

Practice Guidelines for the Diagnosis and Management of Aspergillosis: 2016 Update by the Infectious Diseases Society of America

Thomas F. Patterson,^{1,a} George R. Thompson III,² David W. Denning,³ Jay A. Fishman,⁴ Susan Hadley,⁵ Raoul Herbrecht,⁶ Dimitrios P. Kontoyiannis,⁷ Kieren A. Marr,⁸ Vicki A. Morrison,⁹ M. Hong Nguyen,¹⁰ Brahm H. Segal,¹¹ William J. Steinbach,¹² David A. Stevens,¹³ Thomas J. Walsh,¹⁴ John R. Wingard,¹⁵ Jo-Anne H. Young,¹⁶ and John E. Bennett^{17,a}

¹University of Texas Health Science Center at San Antonio and South Texas Veterans Health Care System; ²University of California, Davis; ³National Aspergillosis Centre, University Hospital of South Manchester, University of Manchester, United Kingdom; ⁴Massachusetts General Hospital and Harvard Medical School, and ⁵Tufts Medical Center, Boston, Massachusetts; ⁶University of Strasbourg, France; ⁷University of Texas MD Anderson Cancer Center, Houston; ⁸Johns Hopkins University School of Medicine and the Sidney Kimmel Comprehensive Cancer Center, Baltimore, Maryland; ⁹Hennepin County Medical Center and University of Minnesota, Minneapolis; ¹⁰University of Pittsburgh, Pennsylvania; ¹¹University at Buffalo Jacobs School of Medicine and Biomedical Sciences, and Roswell Park Cancer Institute, New York; ¹²Duke University Medical Center, Durham, North Carolina; ¹³California Institute for Medical Research, San Jose; ¹⁴New York–Presbyterian Hospital/Weill Cornell Medical Center, New York; ¹⁵University of Florida, Gainesville; ¹⁶University of Minnesota, Minneapolis; ¹⁷Laboratory of Clinical Infectious Diseases, National Institute of Allergy and Infectious Disease, National Institutes of Health, Bethesda, Maryland

It is important to realize that guidelines cannot always account for individual variation among patients. They are not intended to supplant physician judgment with respect to particular patients or special clinical situations. IDSA considers adherence to these guidelines to be voluntary, with the ultimate determination regarding their application to be made by the physician in the light of each patient's individual circumstances.

Keywords. aspergillosis; invasive aspergillosis; allergic aspergillosis; chronic aspergillosis; fungal diagnostics; azoles; echinocandins; amphotericin.

EXECUTIVE SUMMARY

Background

Aspergillus species continue to be an important cause of life-threatening infection in immunocompromised patients. This at-risk population is comprised of patients with prolonged neutropenia, allogeneic hematopoietic stem cell transplant (HSCT), solid organ transplant (SOT), inherited or acquired immunodeficiencies, corticosteroid use, and others. This document constitutes the guidelines of the Infectious Diseases Society of America (IDSA) for treatment of aspergillosis and replaces the practice guidelines for *Aspergillus* published in 2008. Since that publication, clinical studies evaluating new and existing therapies including combination therapy for the management of *Aspergillus* infection have been conducted and the data on use of non-culture-based biomarkers for diagnosing infection have been expanded. The objective of these guidelines is to summarize the current evidence for treatment of different forms of aspergillosis. This document reviews guidelines for management of the 3 major forms of aspergillosis: invasive aspergillosis (IA);

chronic (and saprophytic) forms of aspergillosis; and allergic forms of aspergillosis. Given the clinical importance of IA, emphasis is placed upon the diagnosis, treatment, and prevention of the different forms of IA, including invasive pulmonary aspergillosis (IPA), *Aspergillus* sinusitis, disseminated aspergillosis, and several types of single-organ IA.

Summarized below are the 2016 recommendations for the management of aspergillosis. Due to the guidelines' relevance to pediatrics, the guideline has been reviewed and endorsed by the Pediatric Infectious Diseases Society (PIDS). The panel followed a guideline development process that has been adopted by IDSA, which includes use of the Grading of Recommendations, Assessment, Development, and Evaluation (GRADE) system, a systematic method of grading both the strength of the recommendation (weak or strong) and the quality of evidence (very low, low, moderate, and high) (Figure 1). The guidelines are not intended to replace clinical judgment in the management of individual patients. A detailed description of the methods, background, and evidence summaries that support each recommendation can be found in the full text of the guideline.

EPIDEMIOLOGY AND RISK FACTORS FOR INFECTION

I. How Can the Most Susceptible Patients Be Protected From Aspergillosis, and Which Patients Are Most Susceptible?

What Are Sources of Exposure to Aspergillus, and How Can Exposure Be Decreased? Is Environmental Surveillance Useful?

Received 7 May 2016; accepted 11 May 2016.

^aT. F. P. and J. E. B. served as co-chairs for the IDSA *Aspergillus* Guidelines Committee.

Correspondence: T. F. Patterson, Division of Infectious Diseases, San Antonio Center for Medical Mycology, The University of Texas Health Science Center at San Antonio, 7703 Floyd Curl Drive—MSC 7881, San Antonio, TX 78229-3900 (patterson@uthscsa.edu).

Clinical Infectious Diseases®

Published by Oxford University Press for the Infectious Diseases Society of America 2016. This work is written by (a) US Government employee(s) and is in the public domain in the US. DOI: 10.1093/cid/ciw326

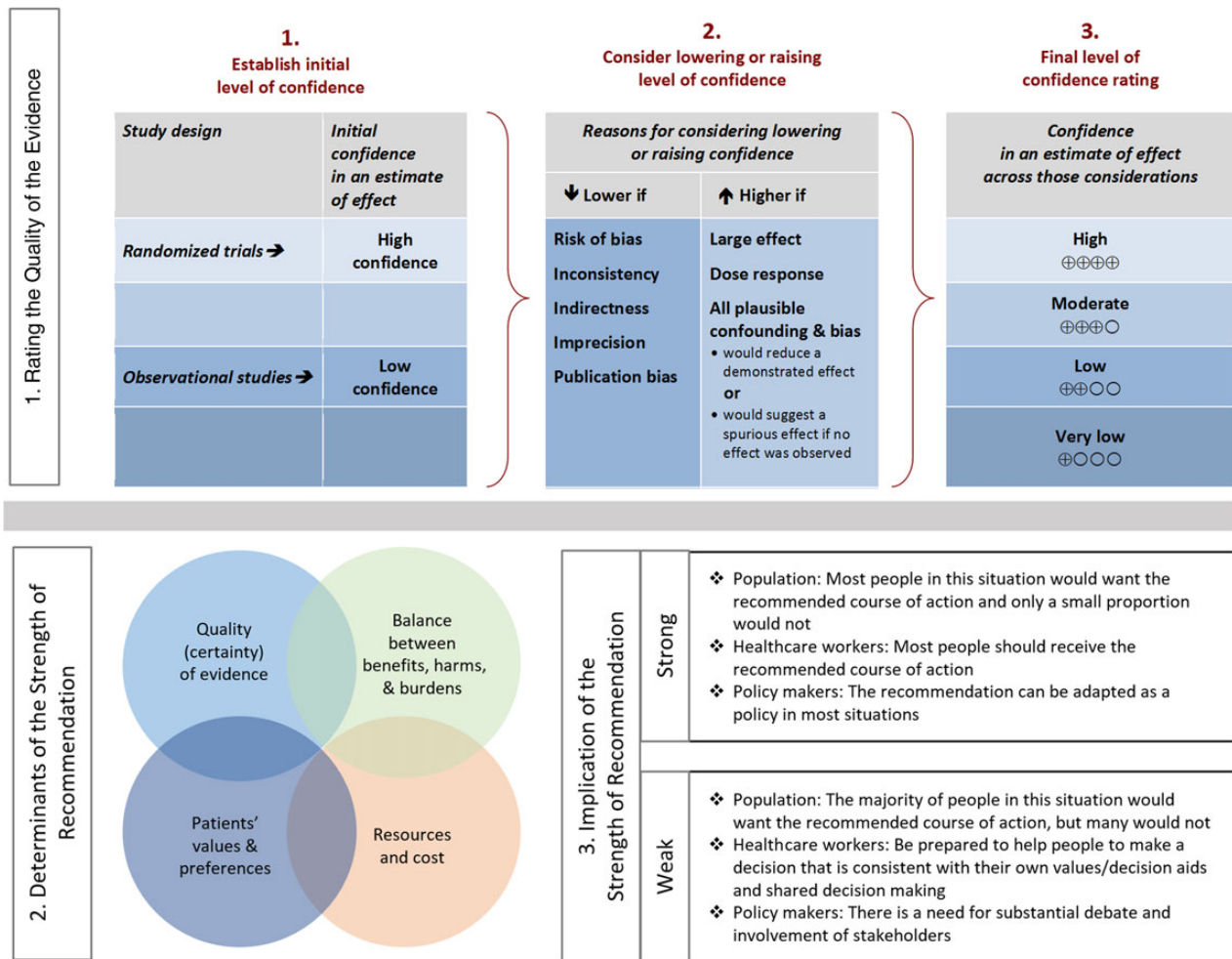


Figure 1. Approach and implications to rating the quality of evidence and strength of recommendations using the Grading of Recommendations, Assessment, Development, and Evaluation (GRADE) methodology (unrestricted use of the figure granted by the US GRADE Network) [4].

Recommendations.

- Hospitalized allogeneic HSCT recipients should be placed in a protected environment to reduce mold exposure (*strong recommendation; low-quality evidence*).
- These precautions can be reasonably applied to other highly immunocompromised patients at increased risk for IA, such as patients receiving induction/reinduction regimens for acute leukemia (*strong recommendation; low-quality evidence*).
- In hospitals in which a protected environment is not available, we recommend admission to a private room, no connection to construction sites, and not allowing plants or cut flowers to be brought into the patient's room (*strong recommendation; low-quality evidence*).
- We recommend reasonable precautions to reduce mold exposure among outpatients at high risk for IA, including avoidance of gardening, spreading mulch (compost), or close exposure to construction or renovation (*strong recommendation; low-quality evidence*).

- Leukemia and transplant centers should perform regular surveillance of cases of invasive mold infection. An increase in incidence over baseline or the occurrence of invasive mold infections in patients who are not at high risk for such infections should prompt evaluation for a hospital source (*strong recommendation; low-quality evidence*).

DIAGNOSIS OF ASPERGILLOSIS

II. How Can a Diagnosis of Invasive Aspergillosis Be Established? How Should *Aspergillus* Be Identified, and How Does This Influence Management? Recommendation.

- Until molecular tools are more widely used in clinical laboratories, we recommend that tissue and fluid specimens be submitted in adequate quantities for simultaneous histopathologic/cytologic and culture examination. In the case of isolates with atypical growth or concerns for resistance, species

identification by molecular methods should be employed (*strong recommendation; high-quality evidence*).

What Is the Diagnostic Value of Nucleic Acid Testing in Clinical Specimens?

Recommendations.

7. There was debate among the committee members regarding the clinical utility of blood-based polymerase chain reaction (PCR) in diagnosing IA, and experts were not in agreement. One group favored recommendations for PCR testing, based on publications validating its role when used in conjunction with other tests such as antigen detection assays to diagnose IA and/or reduce preemptive antifungal usage. The other group thought that PCR assays are promising but could not be recommended for routine use in clinical practice at present due to the lack of conclusive validation for commercially available assays, the variety of methodologies in the literature, and questions about the extent to which results assisted diagnosis.
8. As research in the area continues, we recommend that clinicians choosing to use PCR assays employ them carefully in the management of individual patients on a case-by-case basis. Clinicians should be aware of the methodologies and performance characteristics of the specific assay used, and interpret results accordingly. When PCR assays are used, results should be considered in conjunction with other diagnostic tests and the clinical context (*strong recommendation; moderate-quality evidence*).

How Should Galactomannan and (1 → 3)-β-D-Glucan Be Used for the Diagnosis of Aspergillosis?

Recommendations.

9. Serum and BAL galactomannan (GM) is recommended as an accurate marker for the diagnosis of IA in adult and pediatric patients when used in certain patient subpopulations (hematologic malignancy, HSCT) (*strong recommendation; high-quality evidence*).
10. GM is not recommended for routine blood screening in patients receiving mold-active antifungal therapy or prophylaxis, but can be applied to bronchoscopy specimens from those patients (*strong recommendation; high-quality evidence*).
11. GM is not recommended for screening in SOT recipients or patients with chronic granulomatous disease (CGD) (*strong recommendation; high-quality evidence*).
12. Serum assays for (1 → 3)-β-D-glucan are recommended for diagnosing IA in high-risk patients (hematologic malignancy, allogeneic HSCT), but are not specific for *Aspergillus* (*strong recommendation; moderate-quality evidence*).

What Is the Approach to the Radiographic Diagnosis of Invasive Pulmonary Aspergillosis?

Recommendations.

13. We recommend performing a chest computed tomographic (CT) scan whenever there is a clinical suspicion for IPA

regardless of chest radiograph results (*strong recommendation; high-quality evidence*).

14. Routine use of contrast during a chest CT scan for a suspicion of IPA is not recommended (*strong recommendation; moderate-quality evidence*). Contrast is recommended when a nodule or a mass is close to a large vessel (*strong recommendation; moderate-quality evidence*).
15. We suggest a follow-up chest CT scan to assess the response of IPA to treatment after a minimum of 2 weeks of treatment; earlier assessment is indicated if the patient clinically deteriorates (*weak recommendation; low-quality evidence*). When a nodule is close to a large vessel, more frequent monitoring may be required (*weak recommendation; low-quality evidence*).

What Is the Role of Bronchoscopy in the Diagnosis of Invasive Pulmonary Aspergillosis?

Recommendation.

16. We recommend performing a bronchoscopy with bronchoalveolar lavage (BAL) in patients with a suspicion of IPA (*strong recommendation; moderate-quality evidence*). Significant comorbidities such as severe hypoxemia, bleeding, and platelet transfusion-refractory thrombocytopenia may preclude BAL. The yield of BAL is low for peripheral nodular lesions, so percutaneous or endobronchial lung biopsy should be considered. We recommend the use of a standardized BAL procedure and sending the BAL sample for routine culture and cytology as well as non-culture-based methods (eg, GM) (*strong recommendation; moderate-quality evidence*).

III. What Antifungal Agents Are Available for the Treatment and Prophylaxis of Invasive Aspergillosis, Including Pharmacologic Considerations, and What Is the Role for Susceptibility Testing?

Amphotericin B

Recommendations.

17. Amphotericin B (AmB) deoxycholate and its lipid derivatives are appropriate options for initial and salvage therapy of *Aspergillus* infections when voriconazole cannot be administered. However, AmB deoxycholate should be reserved for use in resource-limited settings in which no alternative agents are available. Lipid formulations of AmB should be considered in settings in which azoles are contraindicated or not tolerated (*strong recommendation; moderate-quality evidence*).
18. Aerosolized formulations of AmB may be considered as prophylaxis in patients with prolonged neutropenia (patients receiving induction/reinduction therapy for acute leukemia and allogeneic HSCT recipients following conditioning or during treatment of graft-vs-host disease [GVHD]) and in lung transplant recipients (*weak recommendation; low-quality evidence*).

Echinocandins

Recommendation.

19. Echinocandins are effective in salvage therapy (either alone or in combination) against IA, but we do not

recommend their routine use as monotherapy for the primary treatment of IA (*strong recommendation; moderate-quality evidence*).

Triazoles

Recommendations.

20. Triazoles are preferred agents for treatment and prevention of IA in most patients (*strong recommendation; high-quality evidence*).
21. For patients receiving triazole-based therapy for IA, prolonged azole prophylaxis, or other therapies for which drug interactions with azoles are anticipated, the committee recommends therapeutic drug monitoring (TDM) once the steady state has been reached. A moderate amount of data for itraconazole, voriconazole, and posaconazole suspension suggests this approach may be valuable in enhancing therapeutic efficacy, in evaluating therapeutic failures attributable to suboptimal drug exposures, and to minimize toxicities potentially attributable to the azoles (*strong recommendation; moderate-quality evidence*). Further studies are needed to address whether TDM is helpful or necessary with the extended-release or intravenous formulations of posaconazole or for isavuconazole.
22. Clinicians should obtain serum trough drug levels for azole antifungal agents (itraconazole, voriconazole, posaconazole, and possibly isavuconazole) and for potentially interacting drugs such as cyclosporine, tacrolimus, and sirolimus (and other CYP3A4 substrates such as tyrosine kinase inhibitors) to optimize therapeutic efficacy and to avoid potential toxicities of both groups of agents (*strong recommendation; moderate-quality evidence*).

Preclinical and Laboratory Assessment of Combination Antifungal Therapy

23. Combinations of polyenes or azoles with echinocandins suggest additive or synergistic effects in some preclinical studies. However, variable test designs and conflicting results of preclinical and in vitro testing have led to uncertainty as to how to interpret the findings (*weak recommendation; low-quality evidence*).

When Should Antifungal Susceptibility Testing Be Performed, and How Should Results Be Interpreted and Affect Management?

Recommendation.

24. Routine antifungal susceptibility testing (AFST) of isolates recovered during initial infection is not recommended. AFST of *Aspergillus* isolates using a reference method is reserved for patients suspected to have an azole-resistant isolate or who are unresponsive to antifungal agents, or for epidemiological purposes (*strong recommendation; moderate-quality evidence*).

INVASIVE SYNDROMES OF ASPERGILLUS

IV. What Are the Recommended Treatment Regimens and Adjunctive Treatment Measures for the Various Clinical Presentation of Invasive Aspergillosis?

How Should IPA Be Treated?

Recommendations.

25. We recommend primary treatment with voriconazole (*strong recommendation; high-quality evidence*).
26. Early initiation of antifungal therapy in patients with strongly suspected IPA is warranted while a diagnostic evaluation is conducted (*strong recommendation; high-quality evidence*).
27. Alternative therapies include liposomal AmB (*strong recommendation; moderate-quality evidence*), isavuconazole (*strong recommendation; moderate-quality evidence*), or other lipid formulations of AmB (*weak recommendation; low-quality evidence*).
28. Combination antifungal therapy with voriconazole and an echinocandin may be considered in select patients with documented IPA (*weak recommendation; moderate-quality evidence*).
29. Primary therapy with an echinocandin is not recommended (*strong recommendation; moderate-quality evidence*). Echinocandins (micafungin or caspofungin) can be used in settings in which azole and polyene antifungals are contraindicated (*weak recommendation; moderate-quality evidence*).
30. We recommend that treatment of IPA be continued for a minimum of 6–12 weeks, largely dependent on the degree and duration of immunosuppression, site of disease, and evidence of disease improvement (*strong recommendation; low-quality evidence*).
31. For patients with successfully treated IPA who require subsequent immunosuppression, secondary prophylaxis should be initiated to prevent recurrence (*strong recommendation; moderate-quality evidence*).

Adjunctive Measures and Immunomodulation: When Should Withdrawal of Immunosuppressive Agents, or Addition of Colony-Stimulating Factors or Granulocyte Transfusions, Be Considered in the Treatment of Invasive Aspergillosis?

Recommendations.

32. Reducing doses of, or eliminating altogether, immunosuppressive agents, when feasible, is advised as a component of anti-*Aspergillus* therapy (*strong recommendation; low-quality evidence*).
33. Colony-stimulating factors may be considered in neutropenic patients with diagnosed or suspected IA (*weak recommendation; low-quality evidence*). There is insufficient evidence regarding the value of granulocyte colony-stimulating factor vs granulocyte macrophage colony-stimulating factor (GM-CSF) in this setting.
34. Granulocyte transfusions can be considered for neutropenic patients with IA that is refractory or unlikely to respond to standard therapy, and for an anticipated duration of more than one week (*weak recommendation; low-quality evidence*).

35. Recombinant interferon- γ is recommended as prophylaxis in CGD patients (*strong recommendation; high-quality evidence*). Its benefit as adjunctive therapy for IA is unknown.
36. Surgery for aspergillosis should be considered for localized disease that is easily accessible to debridement (eg, invasive fungal sinusitis or localized cutaneous disease) (*strong recommendation; low-quality evidence*). The benefit for IA in other settings such as in the treatment of endocarditis, osteomyelitis, or focal central nervous system (CNS) disease appears rational. Other indications are less clear and require consideration of the patient's immune status, comorbidities, confirmation of a single focus, and the risks of surgery.

When Is It Safe to Proceed With Chemotherapy or Transplantation in a Patient With Invasive Aspergillosis?

Recommendations.

37. IA is not an absolute contraindication to additional chemotherapy or HSCT (*strong recommendation; moderate-quality evidence*).
38. Decisions about when to proceed with additional chemotherapy or HSCT following the diagnosis of aspergillosis should involve both infectious diseases specialists and hematologists/oncologists. These decisions must consider the risk of progressive aspergillosis during periods of subsequent antineoplastic treatment vs the risk of death from the underlying malignancy if this treatment is delayed (*strong recommendation; low-quality evidence*).

What Approaches Are Needed for Refractory or Progressive Aspergillosis (Salvage Therapy)?

Recommendations.

39. We recommend an individualized approach that takes into consideration the rapidity, severity, and extent of infection, patient comorbidities, and to exclude the emergence of a new pathogen (*strong recommendation; low-quality evidence*). The general strategies for salvage therapy typically include (i) changing the class of antifungal, (ii) tapering or reversal of underlying immunosuppression when feasible, and (iii) surgical resection of necrotic lesions in selected cases.
40. In the context of salvage therapy, an additional antifungal agent may be added to current therapy, or combination antifungal drugs from different classes other than those in the initial regimen may be used (*weak recommendation; moderate-quality evidence*).
41. In patients currently receiving an antifungal and exhibiting an adverse event attributable to this agent, we recommend changing to an alternative class of antifungal, or the use of an alternative agent with a nonoverlapping side-effect profile (*strong recommendation; low-quality evidence*).
42. For salvage therapy, agents include lipid formulations of AmB, micafungin, caspofungin, posaconazole, or itraconazole. The use of a triazole as salvage therapy should take

into account prior antifungal therapy, host factors, pharmacokinetic considerations, and possible antifungal resistance (*strong recommendation; moderate-quality evidence*).

How Can Biomarkers Be Used to Assess Patient Response to Therapy? Recommendations.

43. Serial monitoring of serum GM can be used in the appropriate patient subpopulations (hematologic malignancy, HSCT) who have an elevated GM at baseline to monitor disease progression and therapeutic response, and predict outcome (*strong recommendation; moderate-quality evidence*).
44. (1 \rightarrow 3)- β -D-glucan has not been extensively studied in IA to predict outcome (*weak recommendation; low-quality evidence*).

What Are the Recommended Treatments for Pediatric Patients With Aspergillosis?

Recommendation.

45. Treatment of aspergillosis in children uses the same recommended therapies as in adult patients; however, the dosing is different and for some antifungals is unknown (*strong recommendation; high-quality evidence*).

What Are Treatment Options for Aspergillosis of the Airways in Transplant and Nontransplant Recipients, and How Does It Differ From Invasive Pulmonary Aspergillosis?

Recommendations.

46. Saprophytic forms of tracheobronchial aspergillosis (TBA) do not require antifungal treatment except for symptomatic or immunosuppressed patients. Treatment includes bronchoscopic removal of mucoid impaction. Mold-active triazole agents are recommended for immunocompromised patients in whom the possibility of invasive disease cannot be eliminated (*strong recommendation; moderate-quality evidence*).
47. Bronchocentric granulomatosis is treated in the same fashion as allergic bronchopulmonary aspergillosis (ABPA) (*strong recommendation; low-quality evidence*).
48. Invasive forms of TBA are treated with a mold-active triazole or intravenous lipid formulations of AmB (*strong recommendation; moderate-quality evidence*). We also recommend minimization or reversal of underlying immunosuppression when feasible, and bronchoscopic debridement of airway lesions in selected cases (*strong recommendation; low-quality evidence*).
49. In lung transplant recipients, we recommend treatment with a systemic antimold antifungal for TBA, including saprophytic forms. We also recommend adjunctive inhaled AmB in the setting of TBA associated with anastomotic endobronchial ischemia or ischemic reperfusion injury due to airway ischemia associated with lung transplant (*strong recommendation; moderate-quality evidence*). Duration of antifungal therapy is at least 3 months or until TBA is completely resolved, whichever is longer.

MANAGEMENT OF EXTRAPULMONARY ASPERGILLOSIS

What Are the Treatment Considerations for Central Nervous System Aspergillosis?

Recommendation.

50. We recommend voriconazole as primary therapy for CNS aspergillosis (*strong recommendation; moderate-quality evidence*). Lipid formulations of AmB are reserved for those intolerant or refractory to voriconazole (*strong recommendation; moderate-quality evidence*).

How Is Aspergillus Endophthalmitis Treated?

Recommendation.

51. We recommend that *Aspergillus* endophthalmitis be treated with systemic oral or intravenous voriconazole plus intravitreal voriconazole or intravitreal AmB deoxycholate (*strong recommendation; weak-quality evidence*).

What Is the Role of Surgery in Aspergillosis of the Paranasal Sinuses?

Recommendation.

52. We recommend that both surgery and either systemic voriconazole or a lipid formulation of AmB be used in invasive *Aspergillus* fungal sinusitis but that surgical removal alone can be used to treat *Aspergillus* fungal ball of the paranasal sinus. Enlargement of the sinus ostomy may be needed to improve drainage and prevent recurrence (*strong recommendation; moderate-quality evidence*).

What Are the Treatment Recommendations for Aspergillus Endocarditis, Pericarditis, and Myocarditis?

Recommendation.

53. In *Aspergillus* endocarditis, we recommend early surgical intervention combined with antifungal therapy in attempts to prevent embolic complications and valvular decompensation (*strong recommendation; moderate-quality evidence*). Voriconazole or a lipid formulation of AmB is recommended as initial therapy (*strong recommendation; low-quality evidence*). Following surgical replacement of an infected valve, lifelong antifungal therapy should be considered (*strong recommendation; low-quality evidence*).

What Are the Treatment Recommendations for Aspergillus Osteomyelitis and Septic Arthritis?

Recommendation.

54. Surgical intervention is recommended, where feasible, for management of *Aspergillus* osteomyelitis and arthritis, combined with voriconazole (*strong recommendation; moderate-quality evidence*).

What Are the Treatment Recommendations for Cutaneous Aspergillosis?

Recommendations.

55. As cutaneous lesions may reflect disseminated infection, we recommend treatment with voriconazole in addition to evaluation for a primary focus of infection (*strong recommendation; low-quality evidence*).

56. In cases of aspergillosis in burns or massive soft tissue wounds, surgical debridement is recommended, in addition to antifungal therapy (*strong recommendation; moderate-quality evidence*).

What Are the Treatment Recommendations for Aspergillus Peritonitis?

Recommendation.

57. We recommend prompt peritoneal dialysis catheter removal accompanied by systemic antifungal therapy with voriconazole (*strong recommendation; low-quality evidence*).

What Are the Treatment Recommendations for Esophageal, Gastrointestinal, and Hepatic Aspergillosis?

Recommendations.

58. We suggest voriconazole and surgical consultation in attempts to prevent complications of hemorrhage, perforation, obstruction, or infarction (*weak recommendation; low-quality evidence*).

59. We suggest antifungal therapy with voriconazole or a lipid formulation of AmB as initial therapy for hepatic aspergillosis. For extrahepatic or perihepatic biliary obstruction, or localized lesions that are refractory to medical therapy, surgical intervention should be considered (*weak recommendation; low-quality evidence*).

What Are the Treatment Recommendations for Renal Aspergillosis?

Recommendation.

60. We suggest a combined approach of medical and urologic management for renal aspergillosis. Obstruction of one or both ureters should be managed with decompression if possible and local instillation of AmB deoxycholate. Parenchymal disease is best treated with voriconazole (*weak recommendation; low-quality evidence*).

What Are the Treatment Regimens for Aspergillus Ear Infections?

Recommendations.

61. Noninvasive *Aspergillus* otitis externa, also called otomycosis, is treated by thorough mechanical cleansing of the external auditory canal followed by topical antifungals or boric acid (*strong recommendation; moderate-quality evidence*).

62. We recommend that clinicians treat IA of the ear with a prolonged course of systemic voriconazole, usually combined with surgery (*strong recommendation; low-quality evidence*).

What Are the Treatment Recommendations for *Aspergillus* Keratitis?

Recommendation.

63. We recommend that clinicians treat *Aspergillus* keratitis with topical natamycin 5% ophthalmic suspension or topical voriconazole (*strong recommendation; moderate-quality evidence*).

How Should *Aspergillus* Bronchitis Be Diagnosed and Treated in the Nontransplant Population?

Recommendations.

64. We suggest the diagnosis of *Aspergillus* bronchitis in non-transplant patients be confirmed by detection of *Aspergillus* spp in respiratory secretions, usually sputum, with both PCR and GM on respiratory samples being much more sensitive than culture (*weak recommendation; low-quality evidence*).

65. We suggest treatment with oral itraconazole or voriconazole with TDM (*weak recommendation; low-quality evidence*).

PROPHYLAXIS OF INVASIVE ASPERGILLOSIS

V. What Are the Recommended Prophylactic Regimens, Who Should Receive Them, and How Should Breakthrough Infection Be Managed? In Which Patients Should Antifungal Prophylaxis Against *Aspergillosis* Be Used?

Recommendation.

66. We recommend prophylaxis with posaconazole (*strong recommendation; high-quality evidence*), voriconazole (*strong recommendation; moderate-quality evidence*), and/or micafungin (*weak recommendation; low-quality evidence*) during prolonged neutropenia for those who are at high risk for IA (*strong recommendation; high-quality evidence*). Prophylaxis with caspofungin is also probably effective (*weak recommendation; low-quality evidence*). Prophylaxis with itraconazole is effective, but therapy may be limited by absorption and tolerability (*strong recommendation; moderate-quality evidence*). Triazoles should not be coadministered with other agents known to have potentially toxic levels with concurrent triazole coadministration (eg, vinca alkaloids, and others) (*strong recommendation; moderate-quality evidence*).

What Are the Recommended Prophylactic Regimens for Patients With Graft-Versus-Host Disease?

Recommendations.

67. We recommend prophylaxis with posaconazole for allogeneic HSCT recipients with GVHD who are at high risk for IA (*strong recommendation; high-quality evidence*). Prophylaxis with other mold-active azoles is also effective. Voriconazole is commonly used for prophylaxis against IA in high-risk patients but did not show improved survival in clinical trials (*strong recommendation; moderate-quality evidence*). Prophylaxis with itraconazole is limited by

tolerability and absorption (*strong recommendation; high-quality evidence*).

68. We recommend continuation of antifungal prophylaxis throughout the duration of immunosuppression in patients with chronic immunosuppression associated with GVHD (corticosteroid equivalent of >1 mg/kg/day of prednisone for >2 weeks and/or the use of other anti-GVHD therapies, such as lymphocyte-depleting agents, or tumor necrosis factor α (TNF- α) inhibition, for refractory GVHD) (*strong recommendation; high-quality evidence*).

What Are the Recommendations for Antifungal Prophylaxis in Lung Transplant Patients?

Recommendations.

69. We recommend antifungal prophylaxis with either a systemic triazole such as voriconazole or itraconazole or an inhaled AmB product for 3 to 4 months after lung transplant (*strong recommendation; moderate-quality evidence*).

70. Systemic voriconazole or itraconazole is suggested over inhaled AmB for lung transplant recipients with mold colonization pre- or post-lung transplant, mold infections found in explanted lungs, fungal infections of the sinus, and single-lung transplant recipients (*weak recommendation; low-quality evidence*).

71. We recommend reinitiating antifungal prophylaxis for lung transplant recipients receiving immunosuppression augmentation with either thymoglobulin, alemtuzumab, or high-dose corticosteroids (*strong recommendation; moderate-quality evidence*).

What Are the Recommendations for Antifungal Prophylaxis in Nonlung Solid Organ Transplant Recipients?

Recommendation.

72. We recommend prophylactic strategies in SOT recipients based on the institutional epidemiology of infection and assessment of individual risk factors (*strong recommendation; low-quality evidence*). Prospective trials are lacking to address the need for routine anti-*Aspergillus* prophylaxis other than for lung transplant recipients. Individual risk factors have been identified in cardiac (pretransplant colonization, reoperation, cytomegalovirus [CMV] infection, renal dysfunction, institutional outbreak), liver (fulminant hepatic failure, reoperation, retransplantation, or renal failure), and others with institutional outbreaks or prolonged or high-dose corticosteroid use. In such patients, the optimal duration of prophylaxis is not known.

MANAGEMENT OF BREAKTHROUGH INFECTION

How Should Breakthrough *Aspergillosis* Be Managed?

Recommendation.

73. We suggest an individualized approach that takes into consideration the rapidity and severity of infection and local

epidemiology. As principles, we recommend an aggressive and prompt attempt to establish a specific diagnosis with bronchoscopy and/or CT-guided biopsy for peripheral lung lesions. Documentation of serum azole levels should be verified if TDM is available for patients receiving mold-active triazoles. Antifungal therapy should be empirically changed to an alternative class of antifungal with *Aspergillus* activity. Other considerations include reduction of underlying immunosuppression if feasible, and susceptibility testing of any *Aspergillus* isolates recovered from the patient (*weak recommendation; moderate-quality evidence*).

VI. When Should Patients Be Treated Empirically?

What Strategies Are Recommended for Empiric and Preemptive Strategies in Allogeneic Hematopoietic Stem Cell Transplant Recipients and Patients Treated for Acute Myelogenous Leukemia? Recommendations.

74. Empiric antifungal therapy is recommended for high-risk patients with prolonged neutropenia who remain persistently febrile despite broad-spectrum antibiotic therapy. Antifungal options include a lipid formulation of AmB (*strong recommendation; high-quality evidence*), an echinocandin (caspofungin or micafungin) (*strong recommendation; high-quality evidence*), or voriconazole (*strong recommendation; moderate-quality evidence*).

75. Empiric antifungal therapy is not recommended for patients who are anticipated to have short durations of neutropenia (duration of neutropenia <10 days), unless other findings indicate a suspected invasive fungal infection (IFI) (*strong recommendation; moderate-quality evidence*).

76. The use of serum or BAL fungal biomarkers such as GM or (1 → 3)-β-D-glucan to guide antifungal therapy in asymptomatic or febrile high-risk patients (often referred to as preemptive or biomarker-driven antifungal therapy) can reduce unnecessary antifungal therapy. The preemptive approach can result in more documented cases of IA without compromise in survival and can be used as an alternative to empiric antifungal therapy (*strong recommendation; moderate-quality evidence*).

77. Early initiation of antifungal therapy in patients with strongly suspected IPA is warranted while a diagnostic evaluation is conducted (*strong recommendation; moderate-quality evidence*).

78. Management of suspected or documented breakthrough IPA in the context of mold-active azole prophylaxis or empiric suppressive therapy is not defined by clinical trial data, but a switch to another drug class is suggested (*weak recommendation; low-quality evidence*).

How Do Lung Transplant Recipients Differ From Other Immunosuppressed Patients in Management of Suspected Invasive Pulmonary Aspergillosis? Recommendations.

79. In lung transplant recipients not on antimold prophylaxis, we suggest preemptive therapy with an antimold antifungal for asymptomatic patients with *Aspergillus* colonization of the airways within 6 months of lung transplant or within 3 months of receiving immunosuppression augmentation for rejection (*weak recommendation; moderate-quality evidence*).

80. Six months after lung transplant and in the absence of recent immunosuppression augmentation for rejection, it may be prudent to withhold antifungal therapy for *Aspergillus* airway colonization (ie, *Aspergillus* respiratory cultures in the absence of clinical features that suggest disease, such as compatible symptoms, or bronchoscopic, histopathologic, and/or radiographic findings) (*weak recommendation; low-quality evidence*).

CHRONIC AND SAPROPHYTIC SYNDROMES OF ASPERGILLUS

VII. How Should Chronic Aspergillosis, Allergic Syndromes, or Noninvasive Syndromes Be Managed?

How Can Chronic Cavitory Pulmonary Aspergillosis Be Diagnosed and Treated?

Recommendations.

81. The diagnosis of chronic cavitory pulmonary aspergillosis (CCPA) requires: (i) 3 months of chronic pulmonary symptoms or chronic illness or progressive radiographic abnormalities, with cavitation, pleural thickening, pericavitary infiltrates, and sometimes a fungal ball; (ii) *Aspergillus* IgG antibody elevated or other microbiological data; and (iii) no or minimal immunocompromise, usually with one or more underlying pulmonary disorders. The *Aspergillus* IgG antibody test is the most sensitive microbiological test (*strong recommendation; moderate-quality evidence*). Sputum *Aspergillus* PCR testing is more sensitive than culture (*weak recommendation; moderate-quality evidence*).

82. Patients with CCPA without pulmonary symptoms, weight loss, or significant fatigue, and those without major impairment of pulmonary function or gradual loss of pulmonary function may be observed without antifungal therapy and followed every 3–6 months (*weak recommendation; low-quality evidence*).

83. Patients with CCPA and either pulmonary or general symptoms or progressive loss of lung function or radiographic progression should be treated with a minimum of 6 months of antifungal therapy (*strong recommendation; low-quality evidence*).

84. Oral itraconazole and voriconazole are the preferred oral antifungal agents (*strong recommendation; high-quality evidence*); posaconazole is a useful third-line agent for those with adverse events or clinical failure (*strong recommendation; moderate-quality evidence*).

85. Hemoptysis may be managed with oral tranexamic acid (*weak recommendation; low-quality evidence*), bronchial

artery embolization (*strong recommendation; moderate-quality evidence*), or antifungal therapy to prevent recurrence (*strong recommendation; low-quality evidence*). Patients failing these measures may require surgical resection (*weak recommendation; moderate-quality evidence*).

86. In those who fail therapy, develop triazole resistance, and/or have adverse events, intravenous micafungin (*weak recommendation; low-quality evidence*), caspofungin (*weak recommendation; low-quality evidence*), or AmB (*weak recommendation; low-quality evidence*) yield some responses. Treatment may need to be prolonged.

87. Surgical resection is an option for some patients with localized disease, unresponsive to medical therapy, including those with pan-azole-resistant *Aspergillus fumigatus* infection or persistent hemoptysis despite bronchial artery embolization (*strong recommendation; moderate-quality evidence*). The outcomes from surgery are less favorable than those with single aspergilloma, and a careful risk assessment prior to surgical intervention is required.

88. In those with progressive disease, long-term, even lifelong antifungal therapy may be required to control disease (*weak recommendation; low-quality evidence*), with continual monitoring for toxicity and resistance.

What Are the Management Options for an Aspergillus Fungal Ball of the Lung (Aspergilloma)?

Recommendations.

89. Asymptomatic patients with a single aspergilloma and no progression of the cavity size over 6–24 months should continue to be observed (*strong recommendation; moderate-quality evidence*).

90. Patients with symptoms, especially significant hemoptysis, with a single aspergilloma, should have it resected, assuming that there are no contraindications (*strong recommendation; moderate-quality evidence*).

91. Peri-/postoperative antifungal therapy is not routinely required, but if the risk of surgical spillage of the aspergilloma is moderate (related to location and morphology of the cavity), antifungal therapy with voriconazole (or another mold-active azole) or an echinocandin is suggested to prevent *Aspergillus* empyema (*weak recommendation; low-quality evidence*).

ALLERGIC SYNDROMES OF ASPERGILLUS

How Is Allergic Bronchopulmonary Aspergillosis Identified and Managed in Patients With Asthma and Cystic Fibrosis?

Recommendations.

92. Elevated *Aspergillus* immunoglobulin E (IgE) and total IgE are recommended to establish the diagnosis and are useful for screening (*strong recommendation; high-quality evidence*).

93. We suggest treating symptomatic asthmatic patients with bronchiectasis or mucoid impaction, despite oral or

inhaled corticosteroid therapy, with oral itraconazole therapy with TDM (*weak recommendation; low-quality evidence*).

94. In CF patients with frequent exacerbations and/or falling forced expiratory volume 1 (FEV₁), we suggest treating with oral itraconazole to minimize corticosteroid use with TDM, and consideration of other mold-active azole therapy if therapeutic levels cannot be achieved (*weak recommendation; low-quality evidence*).

What Is the Medical Management of Allergic Fungal Rhinosinusitis Caused by Aspergillus Species?

Recommendations.

95. We recommend establishing the diagnosis of allergic fungal rhinosinusitis in patients with nasal polyposis and thick eosinophilic mucin by visualizing hyphae in mucus, which is supported by a positive anti-*Aspergillus* IgE serum antibody assay or skin-prick test (where available) (*strong recommendation; moderate-quality evidence*).

96. We recommend polypectomy and sinus washout as the optimal means of symptom control and inducing remission; however, relapse is frequent (*strong recommendation; moderate-quality evidence*).

97. We recommend the use of topical nasal steroids to reduce symptoms and increase time to relapse, especially if given after surgery (*strong recommendation; moderate-quality evidence*).

98. We suggest oral antifungal therapy using mold-active triazoles for refractory infection and/or rapidly relapsing disease, although this approach is only partially effective (*weak recommendation; low-quality evidence*).

INTRODUCTION

IA remains a major cause of morbidity and mortality in high-risk immunocompromised patients. Additionally, chronic and allergic syndromes due to *Aspergillus* are recognized to affect an even greater number of additional patients. In recent years, the clinical evidence for the diagnosis and management of patients with *Aspergillus* syndromes has vastly increased. New agents and formulations along with studies for the use of older agents are available for treating patients with these infections, and new diagnostic tools have increased the ability to diagnose these infections in a timely manner. This document constitutes the guidelines of the Infectious Diseases Society of America (IDSA) for treatment of aspergillosis. These guidelines replace the practice guidelines for *Aspergillus* published in 2008 [1] and incorporate new clinical evidence in the recommendations. The objective of these guidelines is to summarize the current evidence for treatment of different forms of aspergillosis and treatment recommendations are summarized in Table 1. The panel followed the GRADE framework as adopted by the IDSA.

Table 1. Summary of Recommendations for the Treatment of Aspergillosis

Condition	Therapy		Comments
	Primary	Alternative	
Invasive syndromes of <i>Aspergillus</i>			
IPA	Voriconazole (6 mg/kg IV every 12 h for 1 d, followed by 4 mg/kg IV every 12 h; oral therapy can be used at 200–300 mg every 12 h or weight based dosing on a mg/kg basis); see text for pediatric dosing	Primary: Liposomal AmB (3–5 mg/kg/day IV), isavuconazole 200 mg every 8 h for 6 doses, then 200 mg daily Salvage: ABLC (5 mg/kg/day IV), caspofungin (70 mg/day IV × 1, then 50 mg/day IV thereafter), micafungin (100–150 mg/day IV), posaconazole (oral suspension: 200 mg TID; tablet: 300 mg BID on day 1, then 300 mg daily, IV: 300 mg BID on day 1, then 300 mg daily, itraconazole suspension (200 mg PO every 12 h)	Primary combination therapy is not routinely recommended; addition of another agent or switch to another drug class for salvage therapy may be considered in individual patients; dosage in pediatric patients for voriconazole and for caspofungin is different than that of adults; limited clinical experience is reported with anidulafungin; dosage of posaconazole in pediatric patients has not been defined
Invasive sinus aspergillosis	Similar to IPA	Similar to IPA	Surgical debridement as an adjunct to medical therapy
Tracheobronchial aspergillosis	Similar to IPA	Adjunctive inhaled AmB may be useful	Similar to IPA
Aspergillosis of the CNS	Similar to IPA	Similar to IPA Surgical resection may be beneficial in selected cases	This infection is associated with the highest mortality among all of the different patterns of IA; drug interactions with anticonvulsant therapy
<i>Aspergillus</i> infections of the heart (endocarditis, pericarditis, and myocarditis)	Similar to IPA	Similar to IPA	Endocardial lesions caused by <i>Aspergillus</i> species require surgical resection; <i>Aspergillus</i> pericarditis usually requires pericardiectomy
<i>Aspergillus</i> osteomyelitis and septic arthritis	Similar to IPA	Similar to IPA	Surgical resection of devitalized bone and cartilage is important for curative intent
<i>Aspergillus</i> infections of the eye (endophthalmitis and keratitis)	Systemic IV or oral voriconazole plus intravitreal AmB or voriconazole indicated with partial vitrectomy	Similar to invasive pulmonary aspergillosis; limited data with echinocandins and poor ocular penetration by this class	Systemic therapy may be beneficial in management of <i>Aspergillus</i> endophthalmitis; ophthalmologic intervention and management is recommended for all forms of ocular infection; topical therapy for keratitis is indicated
Cutaneous aspergillosis	Similar to IPA	Similar to IPA	Surgical resection is indicated where feasible
<i>Aspergillus</i> peritonitis	Similar to IPA	Similar to IPA	Removal of peritoneal dialysis catheter is essential
Empiric and preemptive antifungal therapy	For empiric antifungal therapy, Liposomal AmB (3 mg/kg/day IV), caspofungin (70 mg day 1 IV and 50 mg/day IV thereafter), micafungin (100 mg day), voriconazole (6 mg/kg IV every 12 h for 1 day, followed by 4 mg/kg IV every 12 h; oral therapy can be used at 200–300 mg every 12 h or 3–4 mg/kg q 12 h)		Preemptive therapy is a logical extension of empiric antifungal therapy in defining a high-risk population with evidence of invasive fungal infection (eg, pulmonary infiltrate or positive GM assay result)
Prophylaxis against IA	Posaconazole: Oral suspension: 200 mg TID Tablet: 300 mg BID on day 1, then 300 mg daily IV: 300 mg BID on day 1, then 300 mg daily	Voriconazole (200 mg PO BID), itraconazole suspension (200 mg PO every 12 h); micafungin (50–100 mg/day), caspofungin (50 mg/day)	Efficacy of posaconazole prophylaxis demonstrated in high-risk patients (patients with GVHD and neutropenic patients with AML or MDS)
Saprophytic or colonizing syndromes of <i>Aspergillus</i>			
Aspergilloma	No therapy or surgical resection	Itraconazole or voriconazole; similar to IPA	The role of medical therapy in the treatment of aspergilloma is uncertain; penetration into preexisting cavities may be minimal for AmB
Chronic cavitary pulmonary aspergillosis	Similar to IPA	Similar to IPA	Innate immune defects demonstrated in most of these patients; long-term therapy may be needed; surgical resection may lead to significant complications; anecdotal response to IFN- γ . Tranexamic acid may be helpful in management of hemoptysis
Allergic syndromes of <i>Aspergillus</i>			
ABPA	Itraconazole	Oral voriconazole (200 mg PO every 12 h) or posaconazole (dosage depends on formulation)	Corticosteroids are a cornerstone of therapy for exacerbations; itraconazole has a demonstrable corticosteroid-sparing effect
Allergic rhinosinusitis caused by <i>Aspergillus</i>	Polypectomy and sinus washout with intranasal corticosteroids	Antifungal therapy reserved for refractory or relapsing cases	

Abbreviations: ABLC, amphotericin B lipid complex; ABPA, allergic bronchopulmonary aspergillosis; AmB, amphotericin B; AML, acute myelogenous leukemia; BID twice daily; CNS, central nervous system; GM, galactomannan; GVHD, graft-vs-host disease; IA, invasive aspergillosis; IFN- γ , interferon gamma; IPA, invasive pulmonary aspergillosis; IV, intravenous; MDS, myelodysplastic syndrome; PO, oral; TID, 3 times daily.

In the recommendation section that follows, the panel answered a series of broad questions for managing syndromes of aspergillosis, and the background and evidence for the recommendations are presented:

- I. How can the most susceptible patients be protected from aspergillosis, and which patients are most susceptible?
- II. How can a diagnosis of IA be established?
- III. What antifungal agents are available for the treatment and prophylaxis of IA, including pharmacologic considerations, and what is the role for susceptibility testing?
- IV. What are the recommended treatment regimens and adjunctive treatment measures for the various clinical presentations of IA?
- V. What are the recommended prophylactic regimens, who should receive them, and how should breakthrough infection be managed?
- VI. When should patients be treated empirically?
- VII. How should chronic aspergillosis, allergic syndromes, or noninvasive syndromes be managed?

METHODOLOGY

Panel Composition

The most recent version of the IDSA guidelines on the management of patients with aspergillosis was published in 2008 [1]. For this update, the IDSA Standards and Practice Guideline Committee (SPGC) convened a multidisciplinary panel of 17 experts in the management of patients with aspergillosis. The panel consisted of 17 members of the IDSA, and included 16 adult infectious diseases physicians and 1 pediatric infectious diseases physician. All panel members were selected on the basis of their expertise in clinical and/or laboratory mycology with a focus on aspergillosis.

Evidence Review: The GRADE Method

GRADE is a systematic approach to guideline development that has been described in detail elsewhere [2, 3]. The IDSA/HIV Medicine Association adopted GRADE in 2008. In the GRADE system, the guideline panel assigns each recommendation with separate ratings for the underlying quality of evidence supporting the recommendation and for the strength with which the recommendation is made (Figure 1) [4]. Data from randomized controlled trials begin as “high” quality, and data from observational studies begin as “low” quality. However, the panel may judge that specific features of the data warrant decreasing or increasing the quality of evidence rating, and GRADE provides guidance on how such factors should be weighed [3]. The strength assigned to a recommendation reflects the panel’s confidence that the benefits of following the recommendation are likely to outweigh potential harms. While the quality of evidence is an important factor in choosing recommendation strength, it is not prescriptive.

Process Overview

Panel members were each assigned to review the recent literature for at least one topic, evaluate the evidence, determine the strength of recommendations, and develop written evidence in support of these recommendations. The panel met face-to-face once and conducted a series of conference calls over a 10-month period. The panel reviewed and discussed all recommendations, their strength, and the quality of evidence. Discrepancies were discussed and resolved, and all final recommendations represent a consensus opinion of the entire panel. For the final version of these guidelines, the panel as a group reviewed all individual sections.

Panel subgroups generated a list of keywords that were used by librarians at the Health Sciences Library, University of Pittsburg (with grateful acknowledgement to Michele Klein-Fedyshin and Charles B. Wessel), to develop PICO (population, intervention, comparison, outcomes) search strings for use in PubMed, and results were returned to each primary author and the chairs for review. Searches were restricted to English-language publications and covered the period of January 2008 (when the last guideline was published) through December 2014. Abstracts presented at international conferences within the past 2 years were also reviewed for inclusion. Systematic reviews of relevant topics were identified using PubMed and the Cochrane library. Each primary topic author was responsible for reviewing the literature relevant to their section and for drafting recommendations and evidence summaries for review and discussion by the full panel.

Conflicts of Interests

The expert panel complied with the IDSA policy on conflicts of interest, which requires disclosure of any financial or other interest that may be construed as constituting an actual, potential, or apparent conflict. Panel members were provided IDSA’s conflicts of interest disclosure statement and were asked to identify ties to companies developing products that may be affected by promulgation of the guideline. Information was requested regarding employment, consultancies, stock ownership, honoraria, research funding, expert testimony, and membership on company advisory committees. Decisions were made on a case-by-case basis as to whether an individual’s role should be limited as a result of a conflict. Potential conflicts of interest are listed in the Notes section.

Review and Approval Process

The panel obtained feedback from 2 external peer reviewers. The guidelines were reviewed and endorsed by the PIDS. The guideline was reviewed and approved by the IDSA Standards and Practice Guidelines Committee and the IDSA Board of Directors prior to dissemination.

Future Guideline Revisions

At annual intervals, the panel chairs will be asked for their input on the need to update the guideline based on an examination of the current literature. The SPGC of the IDSA will consider this

input and determine the necessity and timing of an update. If warranted, the entire panel or a subset thereof will be convened to discuss potential changes.

EPIDEMIOLOGY AND RISK FACTORS FOR INFECTION

I. How Can the Most Susceptible Patients Be Protected From Aspergillosis, and Which Patients Are Most Susceptible?

What Are Sources of Exposure to Aspergillus, and How Can Exposure Be Decreased? Is Environmental Surveillance Useful? Recommendations.

1. Hospitalized allogeneic HSCT recipients should be placed in a protected environment to reduce mold exposure (*strong recommendation; low-quality evidence*).
2. These precautions can be reasonably applied to other highly immunocompromised patients at increased risk for IA, such as patients receiving induction/reinduction regimens for acute leukemia (*strong recommendation; low-quality evidence*).
3. In hospitals in which a protected environment is not available, we recommend admission to a private room, no connection to construction sites, and not allowing plants or cut flowers to be brought into the patient's room (*strong recommendation; low-quality evidence*).
4. We recommend reasonable precautions to reduce mold exposure among outpatients at high risk for IA, including avoidance of gardening, spreading mulch (compost), or close exposure to construction or renovation (*strong recommendation; low-quality evidence*).
5. Leukemia and transplant centers should perform regular surveillance of cases of invasive mold infection. An increase in incidence over baseline or the occurrence of invasive mold infections in patients who are not at high risk for such infections should prompt evaluation for a hospital source (*strong recommendation; low-quality evidence*).

Evidence Summary. *Aspergillus* species and other filamentous fungi are ubiquitous in the environment. The risks of exposure vary both temporally and geographically and are dependent on precipitation patterns, humidity, temperature, and wind conditions [5]. Inhalation of fungal spores is the most common portal of entry, with sinopulmonary disease the most frequent clinical manifestation. Mold exposure also may occur following the consumption or inhalation of products contaminated with fungal spores [6, 7]. Primary cutaneous aspergillosis has been reported in patients with a breach in the normal protective barrier of the skin, such as in burn victims and near vascular sites in neonates [8–11]. Contamination of water systems has also been considered a source of nosocomial aspergillosis and other mold infections [12–17].

Because there are numerous sources of mold in the environment, reasonable efforts should be made to decrease exposure to fungal spores in highly immunocompromised patients. Detailed guidelines have been published regarding hospital room design and

ventilation to reduce mold exposure among allogeneic HSCT recipients [18]. A “protected environment” is recommended, which includes high-efficiency particulate air (HEPA) filtration (and/or laminar airflow), maintenance of positive pressure rooms, and a minimum number of air exchanges per hour. Other at-risk groups such as SOT recipients and burn patients are often also placed in HEPA-filtered rooms. Additional guidelines are provided to minimize mold exposure during hospital construction, renovation, and building [19]. These guidelines can reasonably be applied to other highly immunocompromised patients, such as those receiving induction/reinduction chemotherapy for acute leukemia. We are in agreement with these guidelines, but note that they are consensus criteria based rather than evidence based.

We recognize that highly immunocompromised patients may be admitted to hospitals that lack the engineering standards providing for a “protected environment.” In these settings, reasonable standards include admission to a private room without connection to construction sites, and not allowing plants/cut flowers to be brought into the patient's room.

Patients at risk for mold infections are commonly managed as outpatients where engineering standards are not comparable to the “protected” environment of inpatients. We advise reasonable precautions to reduce mold exposure, including the avoidance of gardening, spreading mulch, or close exposure to construction or renovation. The effectiveness of masks (surgical or N95) to protect against mold infections associated with these exposures is unknown.

The majority of cases of invasive mold infections are sporadic, although outbreaks are well recognized [20–23]. Cases of invasive mold disease with onset of symptoms ≥ 7 days after hospital admission are more likely to be nosocomial [24]. In the absence of an outbreak with an identified environmental source (eg, a contaminated air vent) or molecular analysis that demonstrates clustering of fungal isolates, it is not possible to reliably distinguish community-acquired from nosocomial aspergillosis. As a quality control measure, leukemia and transplant centers should perform regular surveillance (eg, every 3 months) documenting the number of invasive mold infections within their institution. Due to the paucity of culture-confirmed cases of IA and lack of autopsy data in most medical centers, surveillance using case definitions for molds including GM and radiographic evidence of infection such as the revised European Organization for Research and Treatment of Cancer/Mycoses Study Group (EORTC/MSG) criteria is reasonable. An increase in incidence over baseline or the occurrence of invasive mold infections in patients who are not considered high-risk for such infections should prompt evaluation for a hospital source.

Environmental sampling can provide important insight about sources of aspergillosis, including the spread of azole-resistant strains [17, 25], although there is debate whether such surveillance is of value for routine patient care [26, 27]. In the absence of an outbreak, there is insufficient evidence that environmental sampling of fungal spores is of value. In the setting of

a documented or suspected nosocomial outbreak, a number of measures should be undertaken, including evaluation of the ventilation system to ensure adequate filtration, air flow, maintenance of positive pressure, and consideration of environmental sampling (eg, air vents and water system).

What Acquired or Inherited Defects in Host Immunity Increase the Risk of Aspergillosis?

Patients at risk for IA include those with prolonged neutropenia, allogeneic HSCT recipients, SOT recipients, patients receiving corticosteroids, those with advanced AIDS, and those with CGD. In patients with hematologic malignancies, myelodysplastic syndrome (MDS), and other diseases associated with marrow failure (eg, aplastic anemia), the intensity and duration of neutropenia predict the risk of IA [28, 29]. Patients with refractory or relapsed acute leukemia treated with reinduction regimens are at particularly high risk for IA and other mold infections.

Allogeneic HSCT recipients have a significantly higher risk of IA and other opportunistic infections compared with autologous HSCT recipients [30]. In allogeneic HSCT recipients, 3 periods of risk for invasive mold disease occur: (1) neutropenia following the conditioning regimen; (2) exogenous immunosuppression for treatment of acute GVHD; and (3) exogenous immunosuppression for treatment of chronic GVHD (after day 100 of transplant). The level of allogeneic donor and recipient human leukocyte antigen disparity is the major determinant for GVHD severity and intensity of immunosuppression to control GVHD, which, in turn, is the major predisposing factor for opportunistic fungal infections [30–32]. T cell–depleted or CD34-selected stem cell products can also increase the risk of IA [32, 33]. Among allogeneic HSCT recipients, polymorphisms in specific host defense genes of the donor or recipient can also influence the risk of aspergillosis [34–37].

In SOT recipients, the intensity of immunosuppression to prevent or treat allograft rejection, colonization, and coinfection with CMV drive the risk of IA. As in allogeneic HSCT recipients, polymorphisms in specific host defense genes in SOT recipients can also influence the risk of aspergillosis [38, 39]. Lung transplant recipients have the highest risk of IA [40–42]. In a multicenter surveillance study, approximately one-half of cases of IA in lung transplant recipients were late-onset, occurring 1 year or more after transplantation [41]. CMV infection is a risk factor for aspergillosis, notably in heart and lung transplant recipients [43]. Pretransplant *Aspergillus* airway colonization is frequent among cystic fibrosis (CF) patients, and increases the risk of post–lung transplant IA [44]. IA in patients with autoimmune diseases is uncommon. Prolonged use of corticosteroids and other immunosuppressive agents and possibly preexisting lung disease are risk factors [45]. In the era of highly active antiretroviral therapy, IA is a rare complication of human immunodeficiency virus (HIV) infection. AIDS-associated aspergillosis is most frequently associated with advanced AIDS and additional

risk factors, such as neutropenia, corticosteroid use, and concurrent opportunistic infections [46, 47]. CGD, an inherited disorder of the phagocyte NADPH oxidase, is characterized by recurrent bacterial and fungal infections including IA, and other molds, which can be life-threatening [48–51].

Several agents that target immune cell populations and signaling pathways, including malignancies and autoimmune disorders, have also been identified as risk factors for IA. For example, alemtuzumab (anti-CD52) can lead to neutropenia and prolonged suppression of cell-mediated immunity, potentially CMV reactivation [52], and subsequent IA [53, 54]. TNF- α inhibitors are widely used for autoimmune diseases and have been associated with an increased risk of infections and cancer [55]. An analysis of nonviral opportunistic infections in patients with autoimmune diseases documented that the overall risk was greater in patients receiving TNF- α antagonists compared with nonbiological disease-modifying antirheumatic drugs; however, IA was only observed in 1 of >30 000 patients receiving a TNF- α antagonist [56]. By contrast, the use of infliximab for severe GVHD is associated with high risk for the development of IA [57]. Therefore, in assessing the risk for aspergillosis from a specific drug or antibody, one must consider all relevant factors, including the underlying disease being treated, comorbidities (eg, preexisting lung disease), neutropenia, and the use of concurrent immunosuppressive agents.

IA has also been recognized in critically ill patients without traditional risk factors. The exact proportion of critically ill patients with IA in the absence of other risk factors is difficult to determine. In a retrospective analysis, Meersseman et al [58] identified 127 patients out of 1850 intensive care unit admissions (6.9%) with microbiological or histopathologic evidence of *Aspergillus* infection; however, only 5 of these patients had proven IA without predisposing host factors. Trials that evaluate clinical approaches to diagnose IA in critically ill patients include a substantial proportion with classic risk factors for IA and other risk factors including chronic obstructive pulmonary disease (COPD) and cirrhosis [59, 60]. IA has been observed in critically ill patients following other major infections, including influenza [61, 62]. Because critically ill patients are heterogeneous with regard to the underlying disease, comorbidities, and level of immunocompromise [63], it is difficult to delineate the specific role of nonclassic risk factors (eg, multiple organ failure, prolonged mechanical ventilation, bacterial and viral infections including influenza) in driving the risk for IA.

DIAGNOSIS OF ASPERGILLOSIS

II. How Can a Diagnosis of Invasive Aspergillosis Be Established?

How Should Aspergillus Be Identified, and How Does This Influence Management?

Recommendation.

6. Until molecular tools are more widely used in clinical laboratories, we recommend that tissue and fluid specimens be

submitted in adequate quantities for simultaneous histopathologic/cytologic and culture examination. In the case of isolates with atypical growth or concerns for resistance, species identification by molecular methods should be employed (*strong recommendation; high-quality evidence*).

Evidence Summary. The EORTC/MSG revised criteria for defining IFIs, including IA, require a microbiologic and/or histopathologic diagnosis to define proven infection [64]. However, specimen acquisition is challenging in many patients. Histopathologic evidence of fungi is crucial to determine the significance of *Aspergillus* growing in culture, yet diagnostic accuracy of histopathology is suboptimal [65–67]. Moreover, these methods are time-consuming and insensitive. The most common specimens obtained are lung tissue by transthoracic percutaneous needle aspiration or video-assisted thoracoscopic biopsy, and bronchial lavage/wash specimens. These specimens should be submitted in adequate quantities for both histopathologic/cytologic testing and culture with a brief clinical history to aid the pathologist and microbiologist in interpretation of findings [68–72]. Methods to optimize yield should be employed including adequate quantity of specimens, timely delivery of fresh specimen to the laboratory or refrigeration if delay is anticipated (although refrigeration may reduce the recovery of some organisms, eg, Mucorales), incubation of cultures for at least 5 days (and up to 3 weeks for other fungal pathogens), and communication of suspicion for fungal infection with pathology and microbiology laboratory personnel [73]. In the pathology laboratory, standard and special fungal stains on fluid or tissue should be performed simultaneously when a fungal infection is suspected and may reveal the characteristic acute angle branching septate hyphae of *Aspergillus* spp. Molecular assays targeting ribosomal DNA sequences can also be used for detection of *Aspergillus* in tissues, although these methods have not been standardized nor cleared by the US Food and Drug Administration (FDA) for clinical use. The optical brightener methods, Calcofluor or Blankophor, are rapid stains utilized for direct examination and have a high sensitivity and specificity for detecting *Aspergillus*-like features [74, 75]. Special stains on fixed tissue include Gomori methenamine silver (GMS) stain (also referred to as Grocott-Gomori) and periodic acid-Schiff stains. However, no histopathologic finding can definitively diagnose the pathogen, and confirmation by culture or nonculture technique is necessary to distinguish *Aspergillus* from other filamentous fungi such as *Fusarium* spp and *Scedosporium* spp. Additionally, atypical appearances of the organism may be seen in tissue, particularly in patients receiving antifungal therapy. Increasingly, DNA sequencing is being used in reference laboratories to identify “cryptic” species that are misidentified by microscopic appearance or only identified to the complex level. Some of these species are more resistant to azole antifungal agents. *Aspergillus* spp grow well on most media at 37°C at 2–5 days, and methods should

include fungal-specific media. Despite this, culture yield is low and a negative culture does not exclude the diagnosis of IA [76]. This low yield notwithstanding, culture is critical for species complex identification and susceptibility testing where feasible until molecular methods are more routinely performed in clinical laboratories.

What Is the Diagnostic Value of Nucleic Acid Testing in Clinical Specimens?

Recommendations.

7. There was debate among the committee members regarding the clinical utility of blood-based PCR in diagnosing IA, and experts were not in agreement. One group favored recommendations for PCR testing, based on publications validating its role when used in conjunction with other tests such as antigen detection assays to diagnose IA and/or reduce preemptive antifungal usage. The other group thought that PCR assays are promising but could not be recommended for routine use in clinical practice at present due to the lack of conclusive validation for commercially available assays, the variety of methodologies in the literature, and questions about the extent to which results assisted diagnosis.
8. As research in the area continues, we recommend that clinicians choosing to use PCR assays employ them carefully in the management of individual patients on a case-by-case basis. Clinicians should be aware of the methodologies and performance characteristics of the specific assay used, and interpret results accordingly. When PCR assays are used, results should be considered in conjunction with other diagnostic tests and the clinical context (*strong recommendation; moderate-quality evidence*).

Evidence Summary. Since the last IDSA guidelines, there have been numerous publications assessing the performance of *Aspergillus* PCR in clinical samples. Overall, direct comparison studies have shown *Aspergillus* PCR to be substantially more sensitive than culture in blood and respiratory fluids. In a meta-analysis of clinical trials evaluating the accuracy of serum or whole-blood PCR assays for IA, sensitivity and specificity were 84% and 76%, respectively [77]. These values are promising, but PCR of blood or serum is unable on its own to confirm or exclude suspected IA in high-risk patients. The sensitivity of *Aspergillus* PCR on BAL fluid was higher than within blood, but in many instances its specificity was lower [78, 79]. In a systematic review of 9 studies using reference IA definitions strictly adherent to the EORTC/MSG criteria, the sensitivity and specificity of PCR of BAL were 77% and 94%, respectively [78]. Data included large 95% confidence intervals (CIs) that were attributed to the use of different PCR assays and inclusion of heterogeneous patient populations [78, 79]. The lower specificity in BAL has been attributed to the fact that lungs are often colonized by *Aspergillus* (particularly in many high-risk populations, such as lung transplant recipients), and that PCR is not able to

differentiate colonization from disease or to distinguish different *Aspergillus* spp. The high negative predictive value of BAL PCR (usually $\geq 95\%$) suggests a role in ruling out IPA. To date, data suggest that the diagnostic performance of blood or BAL PCR is comparable to that of serum and BAL GM index (GMI; ratio of the optical density [OD] of the patient samples to the mean OD of control samples) of ≥ 0.5 , respectively, and that sensitivity for both tests is affected by antifungal use. Using both PCR and GM in serum resulted in improved sensitivity with no sacrifice of specificity [78].

Clinical trials incorporating biomarkers into the management of adults with hematologic malignancies or allogeneic HSCT have shown that combined GM and PCR reduced use of antifungal treatment [80], and was associated with an earlier diagnosis and lower incidence of IA [81].

There have been fewer PCR studies using nonblood and non-BAL samples. In several studies, PCR is superior to culture in detecting *Aspergillus* spp in sputum specimens from patients with CF and allergic or chronic pulmonary aspergillosis [82–86]. Small studies of *Aspergillus* PCR on nonblood and extrapulmonary body fluids (pleural fluid, cerebrospinal fluid, etc) and paraffin-preserved and fresh tissues (lung, skin, sinus, lymph node) demonstrate sensitivity of 86% and specificity of 100% [87–89].

Despite these promising results, *Aspergillus* PCR cannot yet be recommended for routine use in clinical practice because few assays have been standardized and validated, and the role of PCR testing in patient management is not established. Initiatives such as the European *Aspergillus* PCR Initiative have made significant progress in developing a consensus standard protocol for blood-based *Aspergillus* PCR. PCR assays are commercially available outside the United States (MycAssay *Aspergillus* [Microgen Bioproducts Ltd], Septifast [Roche], MycoReal *Aspergillus* [Ingenetix GmbH], Affigene *Aspergillus* tracer [Cepheid], *Aspergillus* spp Q-PCR Alert [Nanogen], RenDx multiplex *Aspergillus* spp and *Candida* spp [whole blood, plasma, and serum], AsperGenius [Pathonostics], Mycogenie [Ademtech], and others) as is centralization of PCR testing at a reference laboratory in the United States (ViraCor-IBT Laboratories). These provide standardization of the assays, but none have been cleared by the FDA for clinical use in the United States. These efforts now permit multicenter validation of assay performance and studies of clinical utility. Until such studies are completed, however, no specific recommendation about the role of *Aspergillus* PCR in clinical practice in the United States can be made.

How Should Galactomannan and (1 → 3)-β-D-Glucan Be Used for the Diagnosis of Aspergillosis?

Recommendations.

9. Serum and BAL GM is recommended as an accurate marker for the diagnosis of IA in adult and pediatric patients when

used in certain patient subpopulations (hematologic malignancy, HSCT) (*strong recommendation; high-quality evidence*).

10. GM is not recommended for routine blood screening in patients receiving mold-active antifungal therapy or prophylaxis, but can be applied to bronchoscopy specimens from those patients (*strong recommendation; high-quality evidence*).
11. GM is not recommended for screening in SOT recipients or patients with CGD (*strong recommendation; high-quality evidence*).
12. Serum assays for (1 → 3)-β-D-glucan are recommended for diagnosing IA in high-risk patients (hematologic malignancy, allogeneic HSCT), but are not specific for *Aspergillus* (*strong recommendation; moderate-quality evidence*).

Evidence Summary. The Platelia GM enzyme immunoassay is a relatively *Aspergillus*-specific, noninvasive diagnostic assay, and several studies have demonstrated good sensitivity (approximately 70%) in serum of patients with hematological malignancy or allogeneic HSCT [90–95]. A GM-based diagnostic strategy can also result in less empiric antifungal therapy usage [80, 96]. However, the specific patient population tested is critical to optimizing GM usefulness. GM sensitivity in non-neutropenic patients appears to be lower than in other subgroups [97], and decreases to approximately 20% in SOT recipients [98–100]. The GM assay has been repeatedly negative in patients with CGD and IA [101, 102], potentially due to a lack of angioinvasion or immune complex formation with high levels of *Aspergillus* antibodies. Similarly, serum GM has also been reported to be higher in patients with angioinvasive IA vs non-invasive airway IA [103]. While earlier reports suggested that GM was not reliable in pediatric patients due to a high false-positive rate, several subsequent studies have shown its usefulness in children and similar operating characteristics to adult patients [104–111]. Serum GM was not sensitive (38%) in patients with aspergilloma, but improved in those with hemoptysis [112], and was also not sensitive (23%) in patients with chronic pulmonary aspergillosis (CPA) [113] or COPD [114]. GM in patients with CF colonized with *Aspergillus* species was consistently negative [115].

Several variables, including concurrent mold-active antifungal therapy or prophylaxis, significantly reduce levels of circulating GM [91, 94]. The GMI may be increased in the setting of neutropenia and decreases in response to antifungal agents. In one study, the GMI in patients with absolute neutrophil count (ANC) < 100 cells/ μL and not receiving antifungal therapy was statistically higher than those patients with an ANC > 100 cells/ μL ; however, the GMI in patients with an ANC < 100 cells/ μL and receiving antifungal therapy was not statistically different than those patients with an ANC > 100 cells/ μL . Laboratory data and clinical observations indicate that this effect may be due to a higher fungal burden in neutropenic patients, or a more robust inflammatory process in nonneutropenic patients

with a corresponding decrease in the burden of disease, rate of dissemination, and GM release [116, 117].

False-positive results have been reported in several contexts, including in patients who have received certain antibiotics (historically most notably piperacillin-tazobactam, which appears now to no longer be cross-reactive [118], and amoxicillin-clavulanate), neonatal colonization with *Bifidobacterium*, when Plasmalyte is used in BAL fluids, and in patients with other invasive mycoses (including penicilliosis, fusariosis, histoplasmosis, and blastomycosis) [119–122]. Despite these limitations, this assay is a useful adjunctive test to establish an early diagnosis, particularly when used in serial screening of patients at high risk of infection who are not receiving antimold prophylaxis. The optimal rationale for diagnosis in neutropenic patients may be a combined approach guided by clinical, radiographic, and biweekly screening of GM in serum [123], possibly combined with other biomarkers. In patients receiving mold-active antifungal prophylaxis, the use of serum GM as a screening tool results in a very poor predictive value, with most positive tests being false positive in this setting [124]. The detection of GM in BAL fluid has been shown to have a sensitivity that exceeds 70% in most studies and provides additional sensitivity compared with culture even in the setting of mold-active antifungal therapy as discussed below [125–128].

Other potential circulating markers for detection of aspergillosis include (1 → 3)-β-D-glucan detected by the Tachypleus or Limulus assay [129, 130]. The Tachypleus or Limulus assay used to detect the presence of (1 → 3)-β-D-glucan is a variation of the limulus assay used to detect endotoxin. The presence of (1 → 3)-β-D-glucan in serum signifies the presence of fungal invasion but is not specific for *Aspergillus* species; other fungal diseases, including candidiasis, fusariosis, and *Pneumocystis jirovecii* pneumonia can result in a positive test. False-positive results can occur in a variety of contexts, such as through glucan-contaminated blood collection tubes, gauze, depth-type membrane filters for blood processing, and various drugs (eg, antibiotics including some cephalosporins, carbapenems, and ampicillin-sulbactam, and possibly chemotherapeutics such as pegylated asparaginase) [131]. The Fungitell assay (Associates of Cape Cod) for detection of (1 → 3)-β-D-glucan is cleared by the FDA for the diagnosis of invasive mycoses, including aspergillosis, and has been evaluated in high-risk patients with hematological malignancy and allogeneic HSCT [129, 132].

Comparative studies have shown that the Fungitell assay can be slightly more sensitive than GM for IA, but is limited by its poor specificity [133], while others have found that Fungitell is not as helpful for IA [111]. However, another study in a large cancer center that compared GM and (1 → 3)-β-D-glucan assays prospectively over a 3-year period in 82 patients, each for 12 weeks, found that the (1 → 3)-β-D-glucan assay was more sensitive than the GM assays for detection of IA and other mold infections in patients with hematological malignancy

[134]. One meta-analysis of (1 → 3)-β-D-glucan assays revealed limitations [130], while another found similar deficiencies yet improvement in diagnostic capabilities with the combination of both biomarkers [135]. Other organizations have recommended the GM over Fungitell for specifically diagnosing IA [136].

What Is the Approach to the Radiographic Diagnosis of Invasive Pulmonary Aspergillosis?

Recommendations.

13. We recommend performing a chest CT scan whenever there is a clinical suspicion for invasive pulmonary aspergillosis (IPA) regardless of chest radiograph results (*strong recommendation; high-quality evidence*).
14. Routine use of contrast during a chest CT scan for a suspicion of IPA is not recommended (*strong recommendation; moderate-quality evidence*). Contrast is recommended when a nodule or a mass is close to a large vessel (*strong recommendation; moderate-quality evidence*).
15. We suggest a follow-up chest CT scan to assess the response of IPA to treatment after a minimum of 2 weeks of treatment; earlier assessment is indicated if the patient clinically deteriorates (*weak recommendation; low-quality evidence*). When a nodule is close to a large vessel, more frequent monitoring may be required (*weak recommendation; low-quality evidence*).

Evidence Summary. As clinical signs and symptoms are not specific for the diagnosis of IPA, radiographic imaging is critical. The role of imaging is to identify the site of infection, to assess the type, number and size of lesions, and local extension. Imaging also helps to direct diagnostic procedures (eg, BAL or CT-guided biopsy) to the most appropriate area [137].

CT scan is more sensitive than chest radiograph to identify lesions of IPA, especially at their early stage [138], and high-resolution computed tomography (also called thin-section CT scanning with a thin collimation of 0.25–1 mm) is the preferred method. CT angiography may be a useful test pending further evaluation [139]. Chest CT scan performed early after onset of fever helps to identify the cause of fever, may be informative before *Aspergillus* GM is positive, and has been associated with an increased survival in febrile neutropenic patients who have received intensive chemotherapy for a hematologic malignancy [140–142].

Typical features of IPA on CT imaging include nodules, consolidative lesions, and wedge-shaped infarcts. Particularly in neutropenic patients, a halo sign, defined as a nodule (>1 cm in diameter) surrounded by a perimeter of ground-glass opacity reflecting hemorrhage, may be observed [143–147]. Pleural effusions are occasionally observed. Appearance of an air crescent or a cavity in a mass, nodule, or consolidation is also suggestive of invasive mold disease but is usually a later sign, often associated with recovery from neutropenia [145, 146]. The reverse

halo sign is more frequently associated with pulmonary mucormycosis than with IPA [148, 149]. Similar to the halo sign, the reverse halo sign can also present in various other pulmonary conditions including tuberculosis and noninfectious diseases [150, 151].

The presence of nodules and a halo sign are characteristic of angioinvasion, and this form of aspergillosis typically occurs in severely neutropenic patients. IPA can also affect the airways with bronchiolar wall destruction, presence of centrilobular micronodules, and tree-in-bud opacities [152]. Airway disease and angioinvasive lesions can be present in the same patient.

Magnetic resonance imaging (MRI) has no additional value compared to CT scanning for early diagnosis of IPA [153], but is the preferred imaging modality to identify and characterize osseous, paranasal sinus lesions, or CNS disease [154–158].

In neutropenic patients, pulmonary lesions usually increase in size during the first week following initiation of therapy and while the patient recovers from neutropenia [159]. The size of lesions can increase up to 4-fold during the first week and then remain stable for another week. Repetition of a CT scan before 2 weeks after the start of treatment is not usually recommended unless the patient experiences clinical deterioration. An exception is the presence of a nodule close to a large vessel because of the risk for massive hemoptysis if lesions continue to increase in size.

What Is the Role of Bronchoscopy in the Diagnosis of Invasive Pulmonary Aspergillosis?

Recommendations.

16. We recommend performing a bronchoscopy with BAL in patients with a suspicion of IPA (*strong recommendation; moderate-quality evidence*). Significant comorbidities such as severe hypoxemia, bleeding, and platelet transfusion-refractory thrombocytopenia may preclude BAL. The yield of BAL is low for peripheral nodular lesions, so percutaneous or endobronchial lung biopsy should be considered. We recommend the use of a standardized BAL procedure and sending the BAL sample for routine culture and cytology as well as non-culture-based methods (eg, GM) (*strong recommendation; moderate-quality evidence*).

Evidence Summary. Flexible bronchoscopy with BAL remains the cornerstone for microbiological identification in diffuse interstitial or alveolar lung infiltrates, infiltrates in immunosuppressed patients, nosocomial pneumonia, or pneumonia with treatment failure [160–163]. As radiographic signs and symptoms of IPA are nonspecific, BAL increases the likelihood of a diagnosis by direct or indirect identification of mold.

BAL fluid analysis is based on gross observation (hemorrhage, alveolar proteinosis), cell count, and differential count (macrophages, neutrophils, eosinophils, lymphocytes and subpopulation, erythrocytes, malignant cells), and on

microbiologic tests (stains and immunohistochemistry, cultures, antigen or nucleic acid detection). Importantly, BAL allows in the same procedure a search for bacterial, parasitic, viral, and fungal pathogens as well as noninfectious causes of the pulmonary lesions.

There is no uniform agreement on the best timing for bronchoscopy. In a survey of infectious diseases specialists, pulmonologists, and hematologists/oncologists, there was consensus that HSCT recipients who are nonneutropenic and do not have cavitary infiltrates on chest CT scan should receive bronchoscopy only after a failure of empiric antimicrobial therapy. However, there was no agreement between the groups on when neutropenic patients or those with cavitary lesions should undergo bronchoscopy [164].

BAL is an invasive procedure that requires instruction and consent from the patient, sufficient respiratory capacity of the patient, and no major bleeding diathesis. The British Thoracic Society has established guidelines on diagnostic flexible bronchoscopy [165], and specific recommendations for the lavage procedure are also available [166, 167].

Sampsonas et al evaluated a standardized procedure for BAL in 284 consecutive cancer patients with new pulmonary infiltrates [160]. The majority of patients had a hematological malignancy. Thrombocytopenia was not considered a contraindication to bronchoscopy or BAL, but platelet transfusions were administered in patients who had platelet counts <20 000 platelets/ μ L. Only 10 BAL-related complications were observed, and only one was serious but not fatal. In large series, major bronchoscopy-related complications rates range between 0.08% and 0.5%, with mortality rates of 0%–0.04%.

Lavage is usually performed in the segmental or subsegmental bronchus of the most affected area of the lung based on a recent CT scan [160]. Saline is the most often used fluid. False-positive *Aspergillus* GM detection tests were reported when Plasmalyte was used as fluid for BAL [168]. There is considerable variation between practitioners in the volume instilled and the methods of lavage fluid collection, and no consensus has been reached. The instilled volume in nonpediatric patients should be at least 100 mL (most commonly 100–150 mL in aliquots of 20–50 mL, with the initial aliquot likely representing airway sampling) [169]. BAL samples should be sent for cytologic assessment, Gram staining, fungal staining (eg, Calcofluor white or GMS stain), culture, and GM. GM testing from BAL samples provides additional sensitivity compared to culture and exceeds 70% in most studies [125–128]. The optimal threshold for GM positivity has not been determined; an OD of 1.0 has been cleared by the FDA for clinical testing, although some experts consider positivity at OD > 0.5. A higher threshold OD index results in a lower sensitivity but a higher specificity [128].

The diagnostic yield of BAL also varies by the type of radiographic lesion [170]. In this study there was no difference in the diagnostic yield between focal and diffuse infiltrates

(54% vs 52%). In consolidations and tree-in-bud-type abnormalities, the yield is close to 70%, whereas in ground-glass, reticular, or nodular lesions the diagnostic yield falls to approximately 50%.

Transbronchial biopsies are not generally recommended due to their low yield and frequent patient comorbidities (eg, thrombocytopenia) that preclude this diagnostic approach. A percutaneous needle biopsy may be more sensitive than BAL for small peripheral pulmonary lesions.

III. What Antifungal Agents Are Available for the Treatment and Prophylaxis of Invasive Aspergillosis, Including Pharmacologic Considerations, and What Is the Role for Susceptibility Testing?

Amphotericin B

Recommendations.

17. AmB deoxycholate and its lipid derivatives are appropriate options for initial and salvage therapy of *Aspergillus* infections when voriconazole cannot be administered. However, AmB deoxycholate should be reserved for use in resource-limited settings in which no alternative agents are available. Lipid formulations of AmB should be considered in settings in which azoles are contraindicated or not tolerated (*strong recommendation; moderate-quality evidence*).

18. Aerosolized formulations of AmB may be considered as prophylaxis in patients with prolonged neutropenia (patients receiving induction/reinduction therapy for acute leukemia and allogeneic HSCT recipients following conditioning or during treatment of GVHD) and in lung transplant recipients (*weak recommendation; low-quality evidence*).

Evidence Summary. AmB is a polyene with poor oral absorption and is thus solubilized with deoxycholate for intravenous administration. Alternative routes of administration are intraperitoneal, intravitreal, intrathecal, bladder irrigation, and aerosolization. The primary mechanism of action of AmB has historically been considered due to the formation of ion channels in the fungal cell membrane, but recent evidence suggests that amphotericin forms large extramembranous aggregates that extract ergosterol from lipid bilayers, resulting in cell death [171]. Binding to cholesterol in mammalian cell membranes results in end organ dysfunction. A second mechanism of action involves oxidative cell membrane damage. AmB is highly protein bound (95%) before distribution predominantly into reticuloendothelial tissues and kidney. Peak serum concentrations of 1–2 µg/mL are achieved following infusion of 30–50 mg. Penetration into intact and inflamed meninges is poor. No metabolites have been identified. Drug elimination is biphasic with a terminal half-life for AmB deoxycholate of up to 15 days, and the primary route of elimination is not known. Serum levels are not influenced by hepatic or renal dysfunction, and it is poorly dialyzed. Doses of deoxycholate AmB range from 0.1 to 1.5 mg/kg daily. With drug-related renal

dysfunction, 50% dose reduction or alternate-day dosing may be considered. Adverse events include acute infusion reactions (nausea, chills, and rigors), administration-site phlebitis, and nephrotoxicity (azotemia, urinary potassium/magnesium wasting, renal tubular acidosis). Azotemia is exacerbated by concomitant administration of nephrotoxic agents, underlying renal impairment, and diabetes. Volume expansion with a salt load immediately prior to AmB dosing, and monitoring of potassium and magnesium, with repletion as needed, are warranted to prevent renal toxicity. Utility of 24-hour infusions is limited. AmB is active against most, but not all, *Aspergillus* species.

Lipid-based formulations of AmB were developed to reduce AmB-related nephrotoxicity. Available formulations are AmB lipid complex (ABLC; Abelcet), AmB colloidal dispersion (ABCD; Amphocil, Amphotec), and liposomal AmB (AmBisome). Their pharmacokinetic profiles differ from AmB deoxycholate, as well as between each formulation. All preferentially distribute to reticuloendothelial tissue. Infusion reactions of fever and chills occur commonly with ABLC. A characteristic infusion-related reaction syndrome of dyspnea, chest pain, back pain, and hypoxia also may occur, particularly with liposomal AmB [172]. In addition to hypokalemia and hypomagnesemia, mild bilirubin and alkaline phosphatase elevations may occur. Idiosyncratic reactions to one preparation do not preclude use of other formulations [173]. Approved dosages for aspergillosis therapy are: 5 mg/kg/day, 3–6 mg/kg/day, and 3–5 mg/kg/day for ABLC, ABCD, and liposomal AmB, respectively [174]. Higher dose-response relationships have not been well studied, although no improvement in efficacy has been demonstrated to date [175].

Aerosolized formulations of AmB have been used as prophylaxis. Lipid formulations of AmB are generally better tolerated than those involving AmB deoxycholate. Serum drug levels are negligible. These formulations have been utilized as prophylaxis in patients with prolonged neutropenia (patients receiving induction/reinduction therapy for acute leukemia and allogeneic HSCT recipients following conditioning) and in lung (with or without heart) transplant recipients, and therapeutically in calcitrant fungal lung infections [176–184].

Echinocandins

Recommendations.

19. Echinocandins are effective in salvage therapy (either alone or in combination) against IA, but we do not recommend their routine use as monotherapy for the primary treatment of IA (*strong recommendation: moderate-quality evidence*).

Evidence Summary. Echinocandins are semisynthetic amphiphilic lipopeptide antifungal agents. Each of these large molecules is composed of a cyclic hexapeptide core linked to a variably configured N-linked fatty acyl side chain [185]. The

echinocandins act by noncompetitive inhibition of the synthesis of (1 → 3)-β-D-glucan, a polysaccharide in the cell wall of many pathogenic fungi. Together with chitin, these rope-like glucan fibrils are responsible for the cell wall's strength and shape. They are important in maintaining the osmotic integrity of the fungal cell and play a key role in cell division and cell growth.

Each echinocandin has a half-life of >10 hours, which allows for once-daily dosing. They exhibit dose-proportional plasma pharmacokinetics. Echinocandins are highly (>95%) protein bound and distribute well into all major organ sites except for the eye, uninfected spinal fluid where concentrations are lower than other body tissues, and in urine where concentrations are also low. They are available for parenteral administration only. Anidulafungin undergoes spontaneous chemical degradation, with fragment elimination in bile. Caspofungin is metabolized by the liver with some additional spontaneous chemical degradation, with a recommendation for a dose reduction in cases of markedly reduced hepatic function. Micafungin is metabolized by the catechol-O-methyltransferase pathway.

Echinocandins are generally well tolerated, with few side effects and few drug interactions. Caspofungin administration in children and adolescents provides exposure that is comparable to that obtained in adults [186]. There is an inverse relationship between micafungin clearance and age [187], as well as between clearance and weight [188], so micafungin dosing is individualized in patients aged ≤8 years, and in extremely obese patients [187, 188]. Both caspofungin and micafungin maintain linear pharmacokinetics when dose-escalated in adult patients with IA [189, 190]. Among the 3 compounds, caspofungin has more extensive hepatic metabolism, leading to some interactions with other medications. For example, caspofungin can reduce the area under the curve of tacrolimus by approximately 20%, but has no effect on cyclosporine levels. In contrast, cyclosporine increases the area under the curve of caspofungin by approximately 35%. Inducers of drug clearance and/or mixed inducer/inhibitors, namely efavirenz, nelfinavir, nevirapine, phenytoin, rifampin, dexamethasone, and carbamazepine, may reduce caspofungin concentrations.

All 3 agents have activity against *Aspergillus* species. Data are limited regarding their use for primary treatment of invasive infections, due to low accrual in clinical trials. Use of caspofungin to treat 24 allogeneic HSCT recipients with 12 weeks of therapy led to a 42% complete or partial infection response, with a 12-week survival of 50% [191]. However, in a second stratum of that study, primary therapy with caspofungin was successful in only 20 of 61 (33%) patients with hematological malignancy. Based on this limited database, echinocandin monotherapy is not routinely recommended as primary treatment for IA [192]. Use of micafungin to treat 50 patients with CPA led to a 60% treatment response [193]. As a result of the difficulty in enrolling patients at the point of needing primary treatment for

aspergillosis, patients with *Aspergillus* infections were more frequently studied once their infections became refractory to or intolerant of other approved therapies (ie, salvage therapy) [194–196]. In a study where 326 patients were treated with micafungin as salvage therapy, there was a 44% survival rate by the end of 6 weeks of follow-up, with 59% of deaths attributable to the *Aspergillus* infection [194]. Among 83 patients who received caspofungin for salvage therapy, favorable response rates were seen for 45%, compared with 16% among historical controls [195]. Although anidulafungin has been studied in combination therapy, it has not been evaluated in monotherapy as primary or salvage therapy for IA. Because of their distinct mechanism of action, the echinocandins have the potential for use in combination regimens with antifungal agents of differing mechanisms of action [194, 196–198]. When patients are treated with combination therapy, the impact of the echinocandin agent is difficult to specifically define.

Triazoles

Recommendations.

20. Triazoles are preferred agents for treatment and prevention of IA in most patients (*strong recommendation; high-quality evidence*).

Evidence Summary.

TRIAZOLE PHARMACOLOGY

Itraconazole

Itraconazole is formulated as capsules and an oral solution in hydroxypropyl-β-cyclodextrin (HPCD), and a parenteral solution, which is no longer sold in the United States, that also uses HPCD as solubilizing agent. Accumulation of the cyclodextrin molecule in the intravenous preparation occurs with renal impairment, although the toxicity of accumulated cyclodextrin in humans is uncertain. Systemic absorption of oral cyclodextrin is minimal, thus the use of the oral solution is not impacted by renal insufficiency. Itraconazole is highly protein bound (>99%) and is extensively metabolized by the liver (cytochrome P450 [CYP] 3A4) and undergoes enterohepatic circulation. The hydroxyitraconazole metabolite has approximately equivalent antifungal activity but with variable plasma concentration as native drug. Both must be measured to assess drug bioavailability. Itraconazole is an inhibitor and substrate for CYP3A4 and inhibitor of the permeability glycoprotein (p-gp) membrane transporter. The metabolites are excreted in the urine (40%) and bile (55%) [199, 200]. Significant pharmacokinetic variation exists between patients in absorption and distribution [201–203].

Most observed reactions to itraconazole are transient and include nausea and vomiting, hypertriglyceridemia, hypokalemia, and elevated hepatic aminotransferase enzyme levels. Gastrointestinal intolerance appears to be more frequent with oral

HPCD itraconazole solution. Peripheral neuropathy associated with itraconazole has been reported, in particular with prolonged therapy and excessive serum concentrations [204]. Negative inotropic effects have been observed uncommonly but may be important in patients with ventricular dysfunction. Itraconazole is a substrate of CYP3A4 but also interacts with the heme moiety of CYP3A4, resulting in noncompetitive inhibition of oxidative metabolism of many CYP3A4 substrates. Serious interactions with some chemotherapeutic agents (eg, cyclophosphamide and vincristine) may require additional monitoring to avoid toxicity [205] as well as other agents that prolong the QTc interval. Because of these limitations, itraconazole is rarely recommended in patients with acute IPA, with its use reserved for patients with less severe or less invasive disease presentations.

Voriconazole

Voriconazole is formulated as tablets, an oral suspension, and a sulfobutyl-ether cyclodextrin solution for intravenous administration. Sulfobutyl-ether cyclodextrin and voriconazole dissociate in plasma and the cyclodextrin molecule is renally cleared. Accumulation of the vehicle occurs with renal insufficiency. Renal toxicity of hydroxypropyl β -cyclodextrin after parenteral administration has been demonstrated in animal models, although no deleterious effects on renal function have been observed in humans [206, 207]; for this reason, the consequences of cyclodextrin plasma accumulation are unclear. The relative benefits and uncertain risks of intravenous administration of voriconazole in the context of IA and renal failure should be determined on an individual patient basis. This concern does not apply to orally administered voriconazole. The oral formulation has good bioavailability in the fed or fasted state.

Voriconazole is hepatically metabolized, with only 5% of the drug appearing unchanged in the urine. This agent exhibits nonlinear pharmacokinetics in adults, with the maximum concentration in plasma and area under the curve increasing disproportionately with increasing dose. Voriconazole is both a substrate and an inhibitor of CYP2C19 primarily, as well as of CYP3A4 [208–210]. Allelic polymorphisms in CYP2C19 may result phenotypically in rapid or slow metabolism of voriconazole, possibly resulting in significant variation in plasma concentrations [211]. Single-nucleotide polymorphisms contributing to slow metabolism are represented in higher frequencies among non-Indian Asian populations than among other populations.

Factors affecting voriconazole pharmacokinetics include patient age, liver function, CYP2C19- and CYP3A-interacting medications, diet and antacids, proton pump inhibitors, and patient weight, as well as the drug dose and formulation [212]. Reduced voriconazole levels may be observed with oral administration of the drug (vs intravenous), and coadministration with rifampin or phenytoin [213, 214]. Measurement of serum levels is useful in the majority of patients, both to evaluate for potential toxicity

or to document adequate drug exposure, especially in progressive infection [213–226]. Toxicity is more common with higher drug levels but is not predictable based solely on this criterion [216, 220, 227]. The profile of adverse reactions to voriconazole includes transient visual disturbances (characterized principally by photopsia); hepatotoxicity, which may be dose limiting (manifested by elevated serum bilirubin, alkaline phosphatase, and hepatic aminotransferase enzyme levels); skin rash, erythroderma, photosensitivity, and perioral excoriations; nausea, vomiting, and diarrhea; visual or auditory hallucinations; and cardiovascular events including tachyarrhythmias and QT interval prolongations on electrocardiography [209, 211, 213, 228]. There have also been rare cases of arrhythmia (including ventricular arrhythmias such as torsade de pointes and bradycardia), cardiac arrest, and sudden death in patients taking voriconazole. These cases usually involve patients with multiple confounding risk factors, such as history of cardiotoxic chemotherapy, cardiomyopathy, hypokalemia, and concomitant medications (eg, quinolones) that may be contributory. Visual side effects or photopsia are self-limited, reversible, and not clearly associated with absolute drug levels [227, 229]. Mild hepatotoxicity is common as for all azoles and related to drug concentration [227, 230, 231]. Severe hepatotoxicity is uncommon. Reversible central and peripheral neurologic symptoms and hallucinations may be observed in association with higher drug concentrations but with significant variability; these may be confused with other etiologies of CNS dysfunction including posterior reversible leukoencephalopathy syndrome or calcineurin inhibitor toxicity [217, 224, 227, 232, 233]. Voriconazole concentrations may be a predictor of CNS neurotoxicity, which is reversible [214]. The use of prolonged voriconazole therapy (as for osteomyelitis or meningitis) or prophylaxis has revealed newer toxicities including periostitis with severe pain in bones or joints in association with elevated serum fluoride levels [234–240]. The risk for squamous cell skin cancer or melanoma in sun-exposed areas is enhanced by concomitant immunosuppression and chronic voriconazole use, especially in fair-skinned persons [241–243].

Posaconazole

Posaconazole, which is structurally similar to itraconazole, is available as an oral suspension, delayed-release tablet, and intravenous formulation but has been studied for the treatment and prophylaxis of IA only in the oral suspension in efficacy studies. Posaconazole exhibits not only linear kinetics but also saturable absorption of the suspension; thus, oral loading doses are not possible. Steady-state levels may not be achieved for up to a week with posaconazole therapy, which impacts use in primary therapy. The newer delayed-release tablet formulation has improved bioavailability and is given once daily [244–246], as is the intravenous formulation in β -cyclodextrin. Bioavailability of the new tablet is not affected by food or gastric acid, but the oral suspension requires a fed state to maximize

bioavailability. Posaconazole undergoes hepatic metabolism via glucuronidation and also has the capacity for drug–drug interactions through inhibition of CYP3A4 isoenzymes [247]. Posaconazole pharmacokinetics are variable between patients and TDM seems useful, although the posaconazole exposure in plasma from the oral solution appears to underestimate the clinical response to therapy [248–252]. Toxicities are generally mild, including diarrhea and nausea, and do not appear to be related to drug concentrations [253] but may be increased with the higher serum levels attained with the delayed-release tablets. Other toxicities including prolonged QTc interval have been reported with the increased drug levels associated with the extended-release tablets. TDM is recommended based on both preclinical and clinical trials with the oral solution, which documented variable absorption and the relationship of levels to efficacy [254–256], and is likely indicated with the extended-release tablets that may achieve high drug concentrations and be associated with increased toxicities.

Isavuconazole

Isavuconazonium sulfate (referred to in these guidelines as isavuconazole) is a prodrug containing the active antifungal agent isavuconazole, a broad-spectrum triazole agent with a 5-day half-life [257]. The intravenous formulation does not contain cyclodextrin as do other triazoles. Isavuconazole requires a loading dose. The toxicity profile is similar to that of other triazoles, with a similar rate of gastrointestinal disorders, but based on limited experience, a lower rate of photosensitivity, skin disorders, and hepatobiliary and visual disturbances compared with voriconazole [258, 259]. Significant interactions with drugs metabolized by CYP are expected to occur, especially with substrates and inducers of the CYP3A4 enzyme, although preclinical studies suggest that these drug interactions are less severe than with voriconazole. Coadministration of methotrexate with isavuconazole increases exposure to 7-OH methotrexate, a potentially toxic metabolite. Tacrolimus and sirolimus levels are likely to be increased by coadministration of isavuconazole, whereas interactions with cyclosporine and glucocorticoids appear modest. Interestingly, in contrast to other triazoles, isavuconazole could shorten the QTc interval; the clinical significance of this is unclear. There is no effect of the polymorphisms of CYP2C19, which contributes to considerable interpatient variability in serum concentrations of voriconazole.

Triazole Drug Interactions and Therapeutic Drug Monitoring Recommendations.

21. For patients receiving triazole-based therapy for IA, prolonged azole prophylaxis, or other therapies for which drug interactions with azoles are anticipated, the committee recommends TDM once the steady state has been reached. A moderate amount of data for itraconazole, voriconazole, and posaconazole suspension suggests this approach may be valuable in enhancing therapeutic efficacy, in evaluating

therapeutic failures attributable to suboptimal drug exposures, and to minimize toxicities potentially attributable to the azoles (*strong recommendation; moderate-quality evidence*). Further studies are needed to address whether TDM is helpful or necessary with the extended-release or intravenous formulations of posaconazole or for isavuconazole.

22. Clinicians should obtain serum trough drug levels for azole antifungal agents (itraconazole, voriconazole, posaconazole, and possibly isavuconazole) and for potentially interacting drugs such as cyclosporine, tacrolimus, and sirolimus (and other CYP3A4 substrates such as tyrosine kinase inhibitors) to optimize therapeutic efficacy and to avoid potential toxicities of both groups of agents (*strong recommendation; moderate-quality evidence*).

Evidence Summary. Despite a lack of definitive data from large clinical studies, TDM is increasingly recognized as a useful tool for optimizing the safety and efficacy of azole antifungals. Generally, an antifungal agent must meet 3 general criteria for antifungal TDM to be clinically useful. First, a sensitive assay must be available locally or in a reference laboratory that will report results back in a timely fashion (within days), otherwise the impact of monitoring on clinical decision making will be limited. Second, the antifungal must have an established therapeutic range, such that treatment success can be improved or toxicity potentially reduced if patients are dosed to maintain concentrations within this therapeutic window. Finally, the drug must have significant intra- or interpatient pharmacokinetic variability, such that variations in serum levels may jeopardize the effectiveness of therapy with standard dosing guidelines.

Triazole antifungal agents contribute to various important toxicities and drug–drug interactions that may limit therapy (Table 2). Many of the drug interactions are class-related while common toxicities are often specific to the dose or duration of therapy with individual agents [260, 261]. The triazoles are metabolic substrates for, and inhibitors of, several CYP enzymes and inhibitors of the p-gp membrane transporter [262]. Polymorphisms are common in the genes encoding these CYP isoenzymes, particularly CYP2C19, and others with less prominent roles in triazole pharmacokinetics [263]. The polymorphisms of CYP3A4 are not considered to contribute significantly to differences in human metabolism of antifungal triazoles [264]. The polymorphisms of CYP2C19 are a common cause for substantial interpatient variability in drug levels in patients receiving voriconazole.

The triazole antifungal agents demonstrate significant drug–drug interactions that may adversely affect patient outcomes [261]. Each patient’s current medications should be reviewed for potentially deleterious drug interactions. As a class, these include altered serum levels of the azoles and of coadministered agents including calcineurin inhibitors and mammalian target of rapamycin inhibitor immunosuppressive agents, anticoagulants, psychiatric and neurotropic medications, barbiturates,

Table 2. Commonly Encountered Drug–Drug Interactions During Treatment of Aspergillosis

Agent/Class	Interaction	Comment
CNI and mTOR inhibitor immunosuppressive agents	Significant increase in CNI levels by azole	CNI and mTOR agents should be reduced (approximately 30%–50% for CNI and greater for rapamycin) at the time of initiating azole therapy and serum levels for both agents monitored until steady state is reached. Stopping of CNI or mTOR may provoke graft rejection.
Corticosteroids	Levels are increased by azoles	May exacerbate immunosuppression favorable for fungal growth. Prolonged coadministration may elicit signs of excessive steroid exposure.
Antiretroviral agents for HIV	Variable effects	Frequently used in combination with other classes of agents; monitoring of azole levels recommended, and bidirectional drug–drug interactions common.
Rifampin/rifabutin	Decreased levels of azole agents while rifampin/rifabutin levels are increased	Combined use of voriconazole, posaconazole, isavuconazole, or itraconazole with rifampin/rifabutin should generally be avoided. Some combinations are considered contraindicated; others may be managed by TDM and dose adjustment.
Agents that cause QTc interval prolongation (fluoroquinolone and macrolide antimicrobials, quinine, quinidine, digoxin, amiodarone and other antiarrhythmic drugs, calcium channel blockers, psychiatric drugs, antihistamines, and other agents)	QT interval prolongation, torsades de pointes, and other cardiac arrhythmias have been observed with azoles in combination with other agents or preexisting conditions that have these effects	Assess risk benefit and administer with caution to patients with cardiac disorders that increase the risk of arrhythmias.
Vincristine and other vinca alkaloid agents	Neurotoxicity including peripheral neuropathy and seizures in combination with azoles; azole levels also increased	Given the potential for serious toxicity, vincristine and other vinca alkaloids should generally not be coadministered with mold-active azoles. Alternative antifungal therapy (eg, amphotericin B formulation or echinocandin) should be used.
Cyclophosphamide	Increased levels with coadministration of some azoles	Increased renal, hepatic, or genitourinary dysfunction

Abbreviations: CNI, calcineurin inhibitor; HIV, human immunodeficiency virus; mTOR, mammalian target of rapamycin; TDM, therapeutic drug monitoring.

glucocorticoids, digoxin, vinca alkaloids (eg, vincristine) and cyclophosphamide, and antiretroviral agents [260, 265–280]. All of the azoles have important interactions via the CYP enzymes, notably CYP3A4, which can interact with a large number of concomitant medications including tyrosine kinase inhibitors, macrolides, and antiarrhythmics, among others. Active transporters including the p-gp and the breast cancer resistance protein regulate access of the azoles to the drug-metabolizing enzymes of enterocytes and the liver; the clinical importance of the transporters remains to be further defined [260, 281, 282].

Currently, 3 triazoles (itraconazole, voriconazole, and posaconazole) are considered to meet these criteria and have established indications for TDM in IA [283, 284]. There is general agreement that documentation of adequate (and in the case of voriconazole, nontoxic) serum levels in the first 4–7 days after starting therapy (when a patient is at a pharmacokinetic steady state) is preferable for any patient with suspected or documented aspergillosis. Less agreement exists whether TDM is necessary during primary triazole prophylaxis, but low plasma levels of itraconazole and posaconazole suspension have been associated with higher probability of breakthrough infection, and limited data suggest that high levels of posaconazole may be associated with toxicity [285].

The need for continued or repeat monitoring is a patient-specific decision influenced by the clinical status of the host

(eg, specific organ function, comorbidities, and receipt of concomitant medications), severity of infection, concerns regarding nonadherence, cost, TDM assay availability, possibly the duration of therapy [286], and the overall treatment plan. Determination of a plasma drug level, in conjunction with other measures of clinical assessment, can help define factors that may have led to therapeutic failure with oral triazoles and re-open prospects for use of the same oral drug in the future provided pharmacokinetic issues are corrected.

Overviews of clinical scenarios that frequently justify TDM are presented in Table 3. The therapeutic range for voriconazole and posaconazole have been primarily defined from single-center, retrospective studies and can only be considered a general guide for dosing [284].

Itraconazole

Itraconazole capsules require low gastric pH for dissolution, and are therefore poorly absorbed in many patient populations with relative achlorhydria associated with their underlying disease or pharmacotherapy. Itraconazole suspension is better absorbed, but is associated with higher gastrointestinal adverse effects, which are especially problematic in populations who already have nausea, vomiting, or diarrhea. Although a variable rate of breakthrough IA has been reported in patients on itraconazole prophylaxis, relatively few studies have examined the

Table 3. Clinical Scenarios Where Therapeutic Drug Monitoring Is Useful in Treatment of Aspergillosis

Clinical Scenarios Where Antifungal Therapeutic Drug Monitoring Is Useful	Examples, Comment
Populations with increased pharmacokinetic variability	Impaired gastrointestinal function; hepatic (voriconazole, posaconazole, itraconazole); pediatric patients, elderly patients, obese patients, critically ill patients
Changing pharmacokinetics	Intravenous-to-oral switch, changing GI function, changing hepatic or renal function, physiological instability
Interacting medications	Patient receiving medication that induces CYP3A4, antacids, proton pump inhibitors (itraconazole capsules, posaconazole suspension), antiretroviral medications Possibly corticosteroids (voriconazole)
Severe disease	Extensive infection, lesions contiguous with critical structures, CNS infection, multifocal or disseminated infection
Compliance	Important issue with longer-term consolidation therapy or secondary prophylaxis
Suspected breakthrough infection	TDM can help to establish whether fungal disease progression occurred in the setting of inadequate antifungal exposure
Suspected drug toxicity, especially neurotoxicity (voriconazole)	Although exposure-response relationships are described for other toxicities (eg, hepatotoxicity, bone disease), the utility of TDM to prevent their occurrence is less well established

Table developed from Andes et al [283]; Ashbee et al [284]. Additional studies are needed to assess role of TDM for isavuconazole and for posaconazole extended-release tablet and intravenous formulations.

Abbreviations: CNS, central nervous system; CYP, cytochrome P450; GI, gastrointestinal; TDM, therapeutic drug monitoring.

relationship of itraconazole plasma concentrations and treatment efficacy for aspergillosis. Based primarily on prophylaxis data, most experts recommend dosing itraconazole to achieve trough concentrations >0.5–1 µg/mL (combined itraconazole/hydroxyitraconazole troughs >1.5 µg/mL). There are limited data suggesting that higher trough concentrations of itraconazole (>3 µg/mL) may be associated with increased toxicity [287].

Voriconazole

Various target concentrations associated with voriconazole efficacy have been reported, mostly from single-institution retrospective studies [214, 283]. Most experts would aim for dosing to achieve a voriconazole trough of >1–1.5 µg/mL for efficacy but <5–6 µg/mL to minimize toxicity, primarily CNS toxicity. Visual changes can be related to elevated voriconazole concentration but generally resolve spontaneously and without long-term sequelae. Although voriconazole trough concentrations can be elevated in patients with hepatic dysfunction, available data do not support the concept of a threshold level that could adequately discriminate who will be at higher risk for hepatotoxicity [229].

In a prospective, randomized blinded single-center trial of TDM during voriconazole therapy in 100 patients, the proportion of voriconazole discontinuation due to adverse events was significantly lower in the TDM group than in the non-TDM group (4% vs 17%; $P = 0.02$) [288]. More importantly, higher rates of complete or partial response were observed in patients managed with TDM (81% vs those without TDM 57%; $P = 0.04$). This study and several others suggest that antifungal TDM may reduce drug discontinuation due to adverse events and improve the likelihood of a therapeutic response. There are no widely validated algorithms on how to dose voriconazole. Weight-based dosing is recommended to rapidly achieve therapeutic range, with incremental increases and monitoring (ie, 50% increase in daily dose) for the patient who has trough levels <1 µg/mL. Voriconazole concentrations often increase

disproportionately to administered doses due to saturable metabolism in adults. For patients with very low voriconazole levels, coadministering omeprazole (a CYP2C19 inhibitor) has been reported to “boost” voriconazole area under the curve by 41% [289]. Fundamental pharmacokinetics of voriconazole are different in children (linear) than in adults (nonlinear) [290]. In pediatric patients weighing <50 kg, higher voriconazole doses are needed [291] and drug monitoring is paramount (see specific evidence discussion following Recommendation 45 below).

Posaconazole

Increasing evidence supports an exposure–response relationship for plasma posaconazole concentrations for prophylaxis and treatment of IFIs [250]. This, in conjunction with the fact that posaconazole levels (using the suspension formulation) are commonly low (<0.7 µg/mL) in patients with documented IA receiving salvage treatment [1], makes prudent a strategy of monitoring posaconazole serum concentrations in patients with IA who are on chronic posaconazole suspension. On the other hand, a clear relationship has not been identified between posaconazole concentrations and the risk of breakthrough IA in the pivotal posaconazole registration trials [254, 292] in which the event rate (breakthrough IA) was low. Therefore, TDM during posaconazole prophylaxis may be best used in evaluating potential breakthrough infections. There is limited evidence to suggest that peak or trough posaconazole concentrations are predictive of subsequent hepatic or other toxicities, although higher rates of toxicity have been anecdotally observed in some patients with high serum levels (>1.5 µg/mL) achieved with the delayed-release tablet formulation.

The introduction of posaconazole extended-release tablets and the intravenous formulation of posaconazole more easily achieve increased posaconazole serum drug levels, even in patients with risk factors for posaconazole malabsorption [244,

293, 294]. Further studies are needed to address whether higher posaconazole levels are associated with toxicity and whether TDM is helpful or necessary with the extended-release or intravenous formulations. The value of TDM to guide therapy and to avoid toxicity for isavuconazole, a once-daily extended-spectrum triazole with anti-*Aspergillus* activity with good absorption kinetics, similarly remains to be assessed [258].

Preclinical and Laboratory Assessment of Combination Antifungal Therapy

23. Combinations of polyenes or azoles with echinocandins suggest additive or synergistic effects in some preclinical studies. However, variable test designs and conflicting results of preclinical and in vitro testing have led to uncertainty as to how to interpret the findings (*weak recommendation; low-quality evidence*).

Evidence Summary. The rationale for combination therapy is to maximize treatment by targeting multiple targets or metabolic pathways or different points in the same pathway to improve efficacy through achieving an additive or synergistic effect. Other potential benefits include lowering the risk for emergence of drug resistance and the potential for shorter courses of therapy or lower doses of therapy in an attempt to reduce toxicity.

Antifungal drug combinations have been evaluated in multiple in vitro studies and studied in animal models. Combinations of polyenes or azoles with echinocandins have been most studied, and additive or synergistic effects have been noted in the majority of (but not all) studies when compared to monotherapy (especially echinocandins alone) [295–299]. Unfortunately, there are no standardized or validated protocols for in vitro synergy testing, and there are substantive differences in study design, laboratory assay conditions, definitions of endpoints, species and strains tested, animal models, drug choice and concentrations/doses, drug monotherapy comparator, inoculation size, and portal of pathogen administration. Furthermore, correlations between in vitro findings and in vivo observations have not always been consistent, and differences in drug metabolism between animals and humans make comparisons difficult. Also of importance is the order of administration. Some studies have suggested that prior azole administration subsequently reduces polyene activity [300–307].

Antagonism during the use of combination therapy has also been suggested by some studies, especially between polyenes and certain azoles [308]. By comparison, the combination of triazole and echinocandin agents exhibit synergistic to additive interactions in the same systems [309]. However, a murine model demonstrated possible antagonism between itraconazole and micafungin [310]. In vitro studies demonstrate that the combination of triazole and polyene may be antagonistic [310] or that there may be synergy or antagonism depending on the dose used [309, 311]. In addition to reduced antifungal activity,

other potential harmful effects may include increased risk for resistance, additive toxicity, cost, and deleterious drug interactions. Although the preclinical studies have been generally favorable to consideration of combinations of mold-active azoles or polyenes with echinocandins, the variable test designs and conflicting results of preclinical testing have led to uncertainty as to the applicability to clinical practice.

When Should Antifungal Susceptibility Testing Be Performed, and How Should Results Be Interpreted and Affect Management? Recommendation.

24. Routine AFST of isolates recovered during initial infection is not recommended. AFST of *Aspergillus* isolates using a reference method is reserved for patients suspected to have an azole-resistant isolate or who are unresponsive to antifungal agents, or for epidemiological purposes (*strong recommendation; moderate-quality evidence*).

Evidence Summary. The goal of AFST is to detect resistant isolates that are more likely to fail therapy [312, 313]. Considerable progress since the previous guideline has occurred toward achieving this goal. The European Committee on Antibiotic Susceptibility Testing (EUCAST) and the Clinical and Laboratory Standards Institute (CLSI) have published standardized but different AFST methodologies in recent years [314, 315]. *Aspergillus* minimum inhibitory concentrations (MICs) utilizing EUCAST and CLSI methodologies from more recent clinical studies and large surveys have been determined. Although clinical breakpoints are not yet defined by CLSI, epidemiological cutoff values—the upper limit of wild-type MIC distributions which aid in the determining the likelihood of resistance in *Aspergillus* spp—have been proposed by CLSI [316–319]. Establishing epidemiological cutoff values for azoles and *Aspergillus fumigatus*, utilizing in vitro pharmacokinetic/pharmacodynamic studies, in vivo correlation of mutations and failure, and clinical experience aided derivation of proposed azole clinical breakpoints by EUCAST [312, 320–324]. Taken together, these advances resulted in the recommendation by some experts in Europe to perform routine voriconazole AFST [323].

The advances of molecular techniques have led to important changes to *Aspergillus* taxonomy contributed to by the phylogenetic species recognition concept [325]. This method, based on sequencing of several targets for species recognition analysis, has identified new cryptic species, some of which are more resistant to current antifungal drugs [326]. Azole resistance in filamentous fungi primarily involves mutations in the CYP51A target enzyme or promoter that lead to specific or pan-azole resistance, and is described more frequently in *A. fumigatus* complex than other species [327–333]. Other azole resistance mechanisms are also described [334–339]. Resistance to the echinocandins is uncommon, as is resistance to AmB apart from *Aspergillus terreus*, *Aspergillus nidulans*, and *Aspergillus lentulus*

[340, 341]. While azole resistance in the United States and the Americas appears to be low (<3%), there are multiple reports of resistant strains in some European countries and across the world attributed to prior antifungal exposure and to environmental use of antifungal-containing pesticides [85, 324, 342–345]. These reports notwithstanding, there are few studies determining the impact of resistance detected by AFST on clinical outcomes [346, 347].

At this time, AFST is not routinely performed in most clinical laboratories in the United States. Molecular methods to identify azole and echinocandin resistance in filamentous fungi are under investigation but not yet standardized or validated and require further study [341]. However, in the case of isolates with atypical growth or concerns for resistance when molecular methods are not available, AFST should be employed. In conclusion, AFST advances in the past decade are significant; however, worldwide *Aspergillus* resistance remains low, and routine AFST for clinical management is not recommended at this time.

INVASIVE SYNDROMES OF ASPERGILLUS

IV. What Are the Recommended Treatment Regimens and Adjunctive Treatment Measures for the Various Clinical Presentations of Invasive Aspergillosis?

How Should IPA Be Treated?

Recommendations.

25. We recommend primary treatment with voriconazole (*strong recommendation; high-quality evidence*).
26. Early initiation of antifungal therapy in patients with strongly suspected IPA is warranted while a diagnostic evaluation is conducted (*strong recommendation; high-quality evidence*).
27. Alternative therapies include liposomal AmB (*strong recommendation; moderate-quality evidence*), isavuconazole (*strong recommendation; moderate-quality evidence*), or other lipid formulations of AmB (*weak recommendation; low-quality evidence*).
28. Combination antifungal therapy with voriconazole and an echinocandin may be considered in select patients with documented IPA (*weak recommendation; moderate-quality evidence*).
29. Primary therapy with an echinocandin is not recommended (*strong recommendation; moderate-quality evidence*). Echinocandins (micafungin or caspofungin) can be used in settings in which azole and polyene antifungals are contraindicated (*weak recommendation; moderate-quality evidence*).
30. We recommend that treatment of IPA be continued for a minimum of 6–12 weeks, largely dependent on the degree and duration of immunosuppression, site of disease, and evidence of disease improvement (*strong recommendation; low-quality evidence*).
31. For patients with successfully treated IPA who require subsequent immunosuppression, secondary prophylaxis should

be initiated to prevent recurrence (*strong recommendation; moderate-quality evidence*).

Evidence Summary. Early initiation of antifungal therapy in patients with strongly suspected IPA is warranted while a diagnostic evaluation is conducted, both because early therapy has been shown to limit progression of disease and because the performance of diagnostic testing remains limited [145, 175]. Availability of drugs that have differential activity for molds that cause similar syndromes, specifically, the lack of voriconazole activity against mucormycosis, emphasizes the importance of a specific microbiologic diagnosis and antimicrobial susceptibility testing. Evidence supporting appropriate primary therapy of IPA has been generated in a series of randomized controlled trials (Table 1).

The first pivotal treatment trial performed for IA demonstrated better survival in patients who received voriconazole compared with AmB deoxycholate [348], justifying a recommendation against AmB deoxycholate therapy. Since that original randomized trial, multiple cohort studies subsequently published support this recommendation with approximately 15% improved survival at 12 weeks in all patient types with voriconazole compared with other intravenous therapies. Thus, for primary treatment of IPA in adults, intravenous or oral voriconazole is recommended for most patients. For seriously ill patients, the parenteral formulation is recommended. A switch to oral therapy, with dosing maximized to achieve recommended target serum levels, can be considered in patients who are able to tolerate oral therapy.

A randomized trial compared voriconazole with isavuconazole, which demonstrated noninferiority in treatment of IPA [349]. This study showed noninferiority in terms of clinical efficacy, measured by survival and composite clinical responses in the intent-to-treat population of patients with possible, probable, and proven aspergillosis. There were fewer drug-related adverse effects in people who received isavuconazole. Based on these data, isavuconazole was approved by the FDA for first-line therapy of IA and is recommended as an alternative primary therapy for IPA.

Another alternative for primary therapy of IA is liposomal AmB. Although no randomized trial has been performed to evaluate effectiveness of this drug compared to voriconazole for primary therapy, a series of randomized trials suggest effectiveness in therapy. Randomized trials of variable quality evaluating primary treatment of IA using lipid formulations of AmB have been reported to generally favor outcomes with lipid formulations, especially with regard to minimizing toxicities. The most compelling effectiveness data have been generated from randomized trials evaluating liposomal AmB. Cornely et al [175] compared an initial dosage of liposomal AmB of 10 mg/kg/day for 2 weeks with a dosage of 3 mg/kg/day. In that study, among 201 patients, overall outcomes in the 2 arms were similar (46% in the high-dose arm vs 50% in the low-dose arm), but there was more toxicity (32% vs 20%) in the high-dose arm, suggesting that higher doses were

not beneficial. These results suggest that liposomal AmB be considered as alternative primary therapy in some patients, especially in situations in which hepatic toxicities or drug interactions warrant nonazole alternatives, and when voriconazole-resistant molds (eg, mucormycosis) remain of concern.

Another lipid AmB alternative is ABLC (5 mg/kg/day), which has not been studied in randomized trials for IA, but has been reported to be effective in observational studies, particularly in the setting of salvage therapy, and is generally well tolerated compared with AmB deoxycholate [350–353].

Finally, ABCD was compared to AmB deoxycholate in a randomized trial of 174 patients. Although therapeutic responses were similar (52% vs 51%), infusion-related reactions were more common in ABCD. Renal toxicity occurred less frequently with ABCD [174], but due to an increase in serious drug reactions, principally fever, chills, and hypoxia, use of ABCD is not recommended.

Combination therapy in the treatment of IPA has been supported by generally favorable in vitro and in vivo preclinical data in support of combinations of polyenes or mold-active azoles with echinocandins. Nonrandomized clinical trial data suggest the benefit of some forms of combination therapy against IA, usually an azole (most commonly voriconazole) with an echinocandin in aspergillosis [197, 198, 296, 299, 304, 354–360]. There are limited prospective randomized first-line combination therapy trials [361, 362]. In a pilot trial [361], 30 hematologic malignancy patients with proven or probable IA were randomized to either a standard dose of liposomal AmB (3 mg/kg/day) plus caspofungin or high-dose liposomal AmB alone (10 mg/kg/day). Responses were better at the end of therapy with combination therapy but overall survival was similar. A more recent randomized trial compared outcomes of voriconazole monotherapy to combination therapy with voriconazole plus anidulafungin [362]. The trial enrolled 454 patients with hematologic malignancy to evaluate hypothesized superiority in 6-week survival in combination therapy recipients. Mortality at 6 weeks was 19.3% for combination recipients and 27.5% for monotherapy recipients ($P = .087$; 95% CI, -19 to 1.5). Secondary mortality benefits favored combination therapy. In post hoc analyses of the dominant subgroup of patients who were diagnosed as having “probable” aspergillosis based on radiographic abnormalities and positive GM assays, the difference in mortality was most notable (15.7% combination vs 27.3% monotherapy; $P = .037$; 95% CI, -22.7 to -4). Global clinical responses at 6 weeks were lower in the combination group (33% vs 43%), which was attributed to more patients in the combination group being unevaluable for this secondary endpoint due to missing data. There were no toxicity differences. This study adds to prior preclinical and observational clinical studies that suggest potential benefits for combination therapy with voriconazole and an echinocandin [198, 356, 363]. For this reason, the committee suggests consideration for an echinocandin with voriconazole for primary therapy in the setting of severe disease, especially in patients with

hematologic malignancy and those with profound and persistent neutropenia.

While caspofungin has been reported to have efficacy in several small noncomparative studies of drug administered for both primary and “salvage” therapy, the committee does not support use of this agent as monotherapy based on lack of robustly powered comparative trials in which outcomes were not favorable compared to historical data [190–192, 195, 364–366].

Duration of antifungal therapy for IPA is not well defined. We generally recommend that treatment of IPA be continued for a minimum of 6–12 weeks, depending on the severity and continuation of immunosuppression, as well as the extent of resolution of clinical disease. Therapeutic monitoring of IPA includes serial clinical evaluation of all symptoms and signs, as well as performance of radiographic imaging, usually with CT, at regular intervals. The frequency with which CT should be performed cannot be universally defined and should be individualized on the basis of the rapidity of evolution of pulmonary infiltrates and the acuity of illness in the individual patient. The volume of pulmonary infiltrates may increase for the first 7–10 days of therapy, especially in the context of granulocyte recovery [159]. The use of serial serum GM assays for therapeutic monitoring is promising but remains investigational. Progressive increases in *Aspergillus* antigen levels over time signify a poor prognosis. However, resolution of GM antigenemia to a normal level is not sufficient as a sole criterion for discontinuation of antifungal therapy. Long-term therapy of IA is facilitated by the availability of oral azole drugs in stable patients. For patients with successfully treated IA who will require subsequent immunosuppression, resumption of antifungal therapy can prevent recurrent infection [367, 368].

Surgical resection of *Aspergillus*-infected tissue may be useful in patients who have lesions that are contiguous with the great vessels or other critical organs, lesions causing recalcitrant hemoptysis from a single focus, and in lesions eroding into bone. This decision should be mindful of the probability of structural adhesion eliciting spillage of organism into the pleural space.

As discussed in Section II, increasing evidence suggests that attention should be placed on antifungal drug resistance, either that innate to the infecting *Aspergillus* species (such as *A. terreus*, *A. flavus*, or “cryptic” *Aspergillus* spp such as *A. lentulus*) or that acquired by a typically susceptible species.

Adjunctive Measures and Immunomodulation: When Should Withdrawal of Immunosuppressive Agents, or Addition of Colony-Stimulating Factors or Granulocyte Transfusions, Be Considered in the Treatment of Invasive Aspergillosis?

Recommendations.

32. Reducing doses of, or eliminating altogether, immunosuppressive agents, when feasible, is advised as a component of anti-*Aspergillus* therapy (strong recommendation; low-quality evidence).

33. Colony-stimulating factors may be considered in neutropenic patients with diagnosed or suspected IA (*weak recommendation; low-quality evidence*). There is insufficient evidence regarding the value of granulocyte colony-stimulating factor (G-CSF) vs GM-CSF in this setting.
34. Granulocyte transfusions can be considered for neutropenic patients with IA that is refractory or unlikely to respond to standard therapy, and for an anticipated duration of more than one week (*weak recommendation; low-quality evidence*).
35. Recombinant interferon- γ is recommended as prophylaxis in CGD patients (*strong recommendation; high-quality evidence*). Its benefit as adjunctive therapy for IA is unknown.
36. Surgery for aspergillosis should be considered for localized disease that is easily accessible to debridement (eg, invasive fungal sinusitis or localized cutaneous disease) (*strong recommendation; low-quality evidence*). The benefit for IA in other settings such as in the treatment of endocarditis, osteomyelitis, or focal CNS disease appears rational. Other indications are less clear and require consideration of the patient's immune status, comorbidities, confirmation of a single focus, and the risks of surgery.

Evidence Summary. Because immune reconstitution is an important factor in survival from IA, immunosuppressive agents should be tapered or removed, when possible. However, it is frequently not feasible to do so, for example, in patients with severe GVHD or in SOT recipients with allograft rejection. Clinical judgment is required in these cases.

Colony-stimulating factors: Colony-stimulating factors administered prophylactically (prior to the onset of neutropenia) are commonly used to shorten the duration of neutropenia in patients receiving cytotoxic regimens. G-CSF influences survival, proliferation, and differentiation of all cells in the neutrophil lineage and augments the function of mature neutrophils. G-CSF also stimulates neutrophil recovery and various neutrophil effector functions and is a potent activator of monocytes and macrophages. Pegfilgrastim, a pegylated formulation of G-CSF with a long half-life, is used to reduce the duration of neutropenia in patients with nonmyeloid cancers.

A meta-analysis of prophylactic G-CSF showed a reduction in the incidence of neutropenic fever and early deaths, including infection-related mortality [369]. Another meta-analysis showed a survival benefit of prophylactic G-CSF in patients with MDS and acute myelogenous leukemia (AML) [370]. Authoritative guidelines have been published regarding the appropriate use of colony-stimulating factors in patients with cancer, with the main goal of reducing neutropenic fever [371, 372]. The value of adjunctive (as opposed to prophylactic) colony-stimulating factors for the treatment of major infections is unclear. Studies in vitro and in murine aspergillosis suggest that G-CSF and GM-CSF can enhance antifungal host defense

[373–376]. If not initiated in the prophylactic setting, use of colony-stimulating factors should be considered in neutropenic patients with diagnosed or suspected IA. Although colony-stimulating factors can augment phagocyte function in addition to cell numbers, there are insufficient data to recommend their use in patients who are not neutropenic.

Granulocyte transfusions: The rationale for granulocyte transfusions is to increase the number of circulating neutrophils until neutrophil recovery occurs and is usually recommended as an adjunctive measure if granulocyte recovery is anticipated. Granulocyte transfusions have been used for decades as adjunctive treatment for severe infections in patients with neutropenia. The impetus to reevaluate granulocyte transfusions stems largely from improvements made in donor mobilization methods using therapy with G-CSF and corticosteroids [377]. In addition, the use of unrelated community donors for granulocytapheresis was shown to be feasible, thus increasing the pool of potential donors [378, 379]. A randomized trial evaluating the safety and effectiveness of granulocyte transfusions in patients with neutropenia and severe bacterial and fungal infections has recently been published (NCT00627393). Those who received an average dose per transfusion of $>0.6 \times 10^9$ granulocytes/kg tended to have better outcomes than those receiving a lower dose [380].

The overall benefit vs risk of granulocyte transfusions is currently unknown. Granulocyte transfusions were of benefit in experimental pulmonary aspergillosis in neutropenic mice [381]. Granulocyte transfusions can be considered for neutropenic patients with severe infections, including IA and other mold infections, which have failed or are unlikely to respond to standard therapy. Acute lung injury is the major risk of granulocyte transfusions. AmB may increase lung injury associated with granulocyte transfusions [382]; therefore, separating AmB and granulocyte infusions by several hours is advised. Alloimmunization leading to graft failure after allogeneic HSCT is another potential risk of granulocyte transfusions. In allogeneic transplants in which the donor and recipient are seronegative for CMV, use of CMV-seronegative granulocyte donors is recommended.

Recombinant interferon gamma (IFN- γ): IFN- γ augments the antifungal activity of macrophages and neutrophils ex vivo against a variety of fungal pathogens, including *Aspergillus* species. A high proportion of patients with CPA are poor producers of IFN- γ [383]. In addition, a high ratio of ex vivo T-cell production of IFN- γ /interleukin 10 is associated with improved responses to antifungal therapy in patients with IA [384].

Recombinant IFN- γ (rIFN- γ) is licensed as a prophylactic agent for patients with CGD on the basis of a randomized trial in which rIFN- γ reduced the number and severity of infections (mostly bacterial) in patients with CGD by approximately 70% [385]. Its use as adjunctive therapy for patients with IA is limited to case reports and small series. One concern related to

rIFN- γ use in allogeneic HSCT recipients is the potential to worsen GVHD. A single-center retrospective analysis suggested that rIFN- γ was safe in allogeneic HSCT recipients [386]. Currently, the data supporting the efficacy of adjunctive rIFN- γ for aspergillosis are weak; it can be considered in patients with severe or refractory aspergillosis.

Surgery: In general, surgical treatment of aspergillosis should be considered for localized disease that is accessible to debridement. Emergent debridement of sinus aspergillosis can be life-saving and limit extension to the orbit and brain. Localized cutaneous aspergillosis should also be debrided. CNS aspergillosis is a devastating complication; neurosurgical removal combined with antifungal therapy may be life-saving, although the expected postsurgical neurologic outcome should also be considered during the decision process. Surgical resection of pulmonary lesions due to *Aspergillus* species can provide a definitive diagnosis and can potentially completely eradicate a localized infection. Surgical therapy may be useful in patients with lesions that are contiguous with the great vessels or the pericardium, uncontrolled bleeding, or invasion of the pleural space and chest wall. Intervention should also be considered for localized pulmonary aspergillosis refractory to antifungal therapy [387].

Another consideration for surgery is the resection of a single pulmonary lesion prior to intensive chemotherapy or HSCT. However, the favorable experience of HSCT in patients with prior IA suggests that antifungal therapy alone may be effective [367, 388–391]. An acceptable approach in patients with pretransplant aspergillosis is close CT monitoring without surgical resection in the absence of additional complications, such as uncontrolled bleeding or chest wall extension. Decisions concerning surgical therapy should be individualized to account for a number of variables, including the degree of resection (eg, wedge resection vs pneumonectomy), potential impact of delays in chemotherapy, comorbidities, performance status, the goal of antineoplastic therapy (eg, curative vs palliative), and unilateral vs bilateral lesions.

When Is It Safe to Proceed With Chemotherapy or Transplantation in a Patient With Invasive Aspergillosis?

Recommendations.

37. IA is not an absolute contraindication to additional chemotherapy or HSCT (*strong recommendation; moderate-quality evidence*).
38. Decisions about when to proceed with additional chemotherapy or HSCT following the diagnosis of aspergillosis should involve both infectious diseases specialists and hematologists/oncologists. These decisions must consider the risk of progressive aspergillosis during periods of subsequent antineoplastic treatment vs the risk of death from the underlying malignancy if this treatment is delayed (*strong recommendation; low-quality evidence*).

Evidence Summary. Patients with malignancy and IA frequently require additional antineoplastic therapy and/or HSCT. The major concern is that aspergillosis will progress during subsequent periods of immunosuppression. Several studies have shown that IA is not a contraindication for additional treatment, including HSCT [367, 388–391]. It is important to administer mold-active antifungal treatment during subsequent periods of immunosuppression (referred to as secondary prophylaxis) to avoid recurrence or progression. In a multicenter retrospective survey of patients with pretransplant aspergillosis, 27 of 129 patients developed progressive fungal disease following allogeneic HSCT. The variables that increased the 2-year cumulative incidence of aspergillosis progression were longer duration of neutropenia after transplantation, refractory malignancy, and <6 weeks from start of antifungal therapy and HSCT [389]. In a prospective, multicenter trial of voriconazole as secondary prophylaxis in patients with pretransplant IFIs (the majority were aspergillosis), the one-year cumulative incidence of invasive fungal disease was 7% following allogeneic HSCT [367].

Decisions about when to proceed with additional chemotherapy or HSCT following the diagnosis of aspergillosis must consider the risks of progressive aspergillosis and the risks of delaying treatment of the underlying malignancy. These decisions require expertise from infectious diseases specialists and oncologists. From the infectious disease standpoint, a period of several weeks of antifungal treatment and clear evidence of response to therapy is ideal before administering additional chemotherapy or HSCT. However, there are situations when this approach is not feasible, for example, in patients with refractory or relapsed acute leukemia who require urgent reinduction therapy.

What Approaches Are Needed for Refractory or Progressive Aspergillosis (Salvage Therapy)?

Recommendations.

39. We recommend an individualized approach that takes into consideration the rapidity, severity, and extent of infection, patient comorbidities, and to exclude the emergence of a new pathogen (*strong recommendation; low-quality evidence*). The general strategies for salvage therapy typically include (i) changing the class of antifungal, (ii) tapering or reversal of underlying immunosuppression when feasible, and (iii) surgical resection of necrotic lesions in selected cases.
40. In the context of salvage therapy, an additional antifungal agent may be added to current therapy, or combination antifungal drugs from different classes other than those in the initial regimen may be used (*weak recommendation; moderate-quality evidence*).
41. In patients currently receiving an antifungal and exhibiting an adverse event attributable to this agent, we recommend changing to an alternative class of antifungal, or the use of an alternative agent with a nonoverlapping side-effect profile (*strong recommendation; low-quality evidence*).

42. For salvage therapy, agents include lipid formulations of AmB, micafungin, caspofungin, posaconazole or itraconazole. The use of a triazole as salvage therapy should take into account prior antifungal therapy, host factors, pharmacokinetic considerations, and possible antifungal resistance (*strong recommendation; moderate-quality evidence*).

Evidence Summary. Many issues confound the interpretation of current published evidence for salvage therapy for IA including publication bias, inadequate statistical power, and heterogeneity of studies. In salvage therapy studies, differentiating *Aspergillus*-attributable mortality vs the impact of underlying disease or coinfections is not possible [392, 393]. It is also unclear whether different therapeutic approaches are needed when breakthrough infection is detected by GM alone vs culture, the latter likely representing a more advanced stage of disease.

Studies in the area of salvage therapy for aspergillosis also lack uniform criteria of what constitutes a “response.” For example, the volume of lesions on chest CT increase during the first 7–10 days on therapy, and neutrophil recovery may lead to immune reconstitution inflammatory syndrome (IRIS) that presents as transitory clinical worsening [159]. Salvage therapy trials that enroll patients after only 7 days of antifungal therapy may not adequately account for this phenomenon. Antifungal therapy initiated at the time of neutrophil recovery is also biased by the salutatory effects of immune recovery.

In addition, there is confusion in some studies between sequential vs true salvage therapy as the action of the failing drug may interact with the action of the salvage drug. The first drug may inflict damage to *Aspergillus* that enhances the action of the second drug, or there may be neutral or possibly even antagonistic effect. Another issue relates to antifungal agents with prolonged half-lives such as AmB formulations [394]. Thus, in patients receiving AmB-based initial therapy, the combined action of both AmB and the “salvage” antifungal agent will be present for several days to a week after cessation of AmB therapy. Finally, most salvage studies do not provide a robust explanation for the lack of response (eg, failure due to drug resistance or coinfection, disadvantageous pharmacokinetics/pharmacodynamics, intolerance to a study drug, or lack of recovery from immunosuppression).

The principal antifungal agents considered for salvage therapy include lipid formulations of AmB, posaconazole, itraconazole, and the echinocandins, caspofungin and micafungin, which have both been evaluated in salvage settings [255, 356, 395–398]. Voriconazole can also be considered as a salvage agent if not used in primary therapy, as could presumably isavuconazole, although isavuconazole has limited evaluation in the salvage setting. In patients who fail initial triazole therapy, a change in class to an AmB formulation (usually liposomal AmB), with or without an echinocandin, should be considered. Azole-specific pharmacokinetic problems must also be

considered, including TDM. Most of the prospective studies of second-line therapy have been conducted by replacing the compound to which the patient is intolerant or against which the infection is progressing. Whether both drugs should be administered simultaneously has seldom been prospectively studied [194]. The addition of a second antifungal agent to a first agent that is failing is usually practiced out of understandable lack of therapeutic options.

Other drug combinations have not been extensively studied [297]. Additional questions of optimal drug combinations, optimal drug dosing, pharmacokinetic interactions, potential toxic interactions, and cost–benefit ratios of primary combination antifungal therapy require further investigation.

The need for surgical resection should be evaluated in cases of pulmonary lesions contiguous with the heart or great vessels, invasion of the chest wall, massive hemoptysis, and other special circumstances. Restoration of or improvement in impaired host defenses is critical for improved outcome of IA. Correction of comorbidities using various adjunctive strategies (eg, correction of hyperglycemia, recovery from neutropenia, or reduction of immunosuppressive medication dosages) is expected to improve outcomes in progressive IA but may also be associated with IRIS.

How Can Biomarkers Be Used to Assess Patient Response to Therapy?

Recommendations.

43. Serial monitoring of serum GM can be used in the appropriate patient subpopulations (hematologic malignancy, HSCT) who have an elevated GM at baseline to monitor disease progression and therapeutic response, and predict outcome (*strong recommendation; moderate-quality evidence*).
44. (1 → 3)- β -D-glucan has not been extensively studied in IA to predict outcome (*weak recommendation; low-quality evidence*).

Evidence Summary. Multiple studies have evaluated serial serum GM for both therapeutic monitoring as well as predicting prognosis and found excellent correlations between GMI and outcomes. A review of 27 published studies, including both adult and pediatric allogeneic or autologous HSCT recipients, found an excellent correlation between GMI and survival, including autopsy findings [399]. A prospective study of 70 patients with prolonged neutropenia found good GMI concordance with clinical outcome at 6 weeks and excellent correlation at 12 weeks, including perfect concordance with autopsy findings and significantly better survival in patients who became GM negative by 12 weeks [400]. Another retrospective study found similar results, including significantly better survival in patients whose GMI normalized compared to patients with persistently positive GM, regardless of resolution of neutropenia [401]. In one study, an adjusted hazard ratio (HR) for

respiratory or all-cause mortality increased from 2.25 with a serum GMI ≥ 0.5 to a HR of 4.9 with a serum GMI ≥ 2.0 [402]. GMI-based assessment can also predict outcome sooner [403].

Several studies have compared the initial GMI and subsequent rate of daily decay of GM, defined as the change from the initial GMI divided by the number of days since that initial value. Both initial GMI and rate of decrease of GM in response to therapy at one week after initiation of therapy have been predictive of mortality [404]. The adjusted HR for initial GM for time to mortality was 1.25 per unit increase in GMI, as well as an HR of 0.78 per unit decrease for survival [405]. GMI is also predictive of outcome in nonneutropenic patients [406–408].

A retrospective evaluation of the global aspergillosis clinical trial comparing voriconazole to AmB deoxycholate followed by other licensed therapy [348] found that GMI at week 1 was significantly lower than baseline GM in the eventual 12-week responders compared with nonresponders. A GMI reduction of $>35\%$ between baseline and week 1 predicted a probability of a satisfactory clinical response, whereas during antifungal treatment every 0.1-unit increase in GMI between baseline and week 2 increased the likelihood of a poor response by 21.6% [409]. A different analysis of the same trial found that those patients who received voriconazole and had a successful week 12 response showed earlier decreases in GMI at week 1 and week 2 as compared to those who eventually failed treatment. However, for patients randomized to initially receive AmB deoxycholate, this early difference trend between week 12 responders and nonresponders was not evident until week 4 [410].

There have been fewer studies with BAL GMI and outcome. A retrospective study of 145 patients found a BAL GMI ≥ 2.0 was significantly associated with a higher 60-day mortality compared with a BAL GMI < 0.5 [411]. However, another retrospective study of 100 allogeneic HSCT recipients found that serum GMI positivity and magnitude, but not BAL GMI, correlated with both 6-week and 6-month mortality [402].

In a single-center retrospective study, initial (1 \rightarrow 3)- β -D-glucan value and early kinetics of (1 \rightarrow 3)- β -D-glucan were not predictive of 6- or 12-week clinical outcome or mortality in IA [412].

What Are the Recommended Treatments for Pediatric Patients With Aspergillosis?

Recommendation.

45. Treatment of aspergillosis in children uses the same recommended therapies as in adult patients; however, the dosing is different and for some antifungals is unknown (*strong recommendation; high-quality evidence*).

Evidence Summary. Treatment in children follows the recommendations used for adults, yet antifungal dosing in children is often significantly different. Underdosing in children is a

common etiology of insufficient drug levels and possibly clinical failures. Voriconazole, while only FDA approved for children 12 years and older, is the mainstay of pediatric aspergillosis treatment in all ages due to substantial pharmacokinetic data and experience. Fundamental pharmacokinetics of voriconazole are different in children (linear) than in adults (nonlinear) [290]. While voriconazole in adults is loaded at 6 mg/kg/dose twice daily, followed by 4 mg/kg/dose twice daily, the preferred pediatric dosing is substantially higher. Population pharmacokinetic analyses of voriconazole reveal that children should be given an intravenous 9 mg/kg loading dose twice daily to be comparable to a 6 mg/kg/dose in adults [413]. Maintenance intravenous dosing in children at 8 mg/kg/dose was comparable to a 4 mg/kg/dose in adults, and the oral dosing of 9 mg/kg/dose was similar to adults receiving 200 mg oral voriconazole twice daily. The majority of adolescents can be dosed as adults, but in younger adolescents (ages 12–14), body weight is more important than age in predicting voriconazole pharmacokinetics. Therefore, younger adolescents should be dosed as children if their weight is <50 kg and as adults if their weight is ≥ 50 kg [413]. Additionally, the oral bioavailability of voriconazole, thought to be $>95\%$ in adults, is lower in children at approximately 50%–65% [414, 415]. As in adult patients, there are still suggestions of the need for higher voriconazole doses [291], and drug monitoring is paramount.

Posaconazole is FDA approved for children 13 years and older for both the oral suspension and tablet, and for 18 years and older for the intravenous formulation. As such, pediatric dosing has not yet been fully defined. Caspofungin is FDA approved for children 3 months and older and dosing is based on body surface area, with a loading dose of 70 mg/m², followed by daily maintenance dosing of 50 mg/m², not to exceed 70 mg [186]. Micafungin is FDA approved for children 4 months and older and clearance increases in younger age groups. Doses in children are 2–3 mg/kg/day, with higher doses for younger children, and patients >40 kg use the adult dose (100 mg) [187]. Anidulafungin is not FDA approved for children, and a single pharmacokinetic study in children suggested a loading dose of 1.5–3 mg/kg and maintenance dose of 0.75–1.5 mg/kg [416]. Dosing of lipid formulations of AmB does not differ in children.

What Are Treatment Options for Aspergillosis of the Airways in Transplant and Nontransplant Recipients, and How Does It Differ From Invasive Pulmonary Aspergillosis?

Recommendations.

46. Saprophytic forms of TBA do not require antifungal treatment except for symptomatic or immunosuppressed patients. Treatment includes bronchoscopic removal of mucoid impaction. Mold-active triazole agents are recommended for immunocompromised patients in whom the possibility of invasive

disease cannot be eliminated (*strong recommendation; moderate-quality evidence*).

47. Bronchocentric granulomatosis is treated in the same fashion as ABPA (*strong recommendation; low-quality evidence*).

48. Invasive forms of TBA are treated with a mold-active triazole or intravenous lipid formulations of AmB (*strong recommendation; moderate-quality evidence*). We also recommend minimization or reversal of underlying immunosuppression when feasible, and bronchoscopic debridement of airway lesions in selected cases (*strong recommendation; low-quality evidence*).

49. In lung transplant recipients, we recommend treatment with a systemic antimold antifungal for TBA, including saprophytic forms. We also recommend adjunctive inhaled AmB in the setting of TBA associated with anastomotic endobronchial ischemia or ischemic reperfusion injury due to airway ischemia associated with lung transplant (*strong recommendation; moderate-quality evidence*). Duration of antifungal therapy is at least 3 months or until TBA is completely resolved, whichever is longer.

Evidence Summary. Airway aspergillosis (or TBA) is similar to pulmonary aspergillosis in that it can occur in saprophytic, allergic (ABPA), or invasive forms. There is also an emerging entity of *Aspergillus* bronchitis among patients with CF, and others with bronchiectasis. The diagnosis of TBA is suggested by bronchoscopic findings and confirmed by culture and histopathology. Due to the limited number of studies, optimal evidence-based therapy is not clear, and recommendations are extrapolated from experience in treating invasive lung parenchymal aspergillosis and TBA case series.

Saprophytic forms of TBA include obstructing bronchial aspergillosis, endobronchial aspergillosis, and mucoid impaction.

Obstructing bronchial aspergillosis is characterized by thick mucous plugs with minimal or no airway inflammation [417, 418]. Patients commonly present with the subacute onset of cough, dyspnea, chest pain, hemoptysis, and expectoration of fungal casts. Management typically consists of bronchoscopic clearance usually followed by oral antifungal therapy.

Endobronchial aspergillosis is generally found among patients with lesions such as broncholiths, cancer, or granulation tissue or suture material at the anastomotic site after lung resection. It is manifested as endobronchial lesions or mucous plugs in or around the bronchial stumps or sutures. In general, these saprophytic forms do not require systemic antifungal therapy unless patients are immunocompromised and locally invasive disease cannot be ruled out [418]. In symptomatic patients, local debridement or suture removal can be performed. There is no consistent evidence that systemic, inhaled, or local injection with an antifungal agent is effective in treating these forms of disease.

Mucoid impaction is a clinical-radiographic syndrome characterized by inspissated mucus filling of the bronchi [417, 418]. Finger-in-glove sign, referring to branching tubular opacities that

extend peripherally, is the classic chest radiograph finding. Patients can be asymptomatic, or present with cough and expectoration of mucous plugs. Mucoid impaction is commonly associated with inflammatory conditions of the airways (such as bronchiectasis and ABPA), benign processes (such as bronchiolitis, foreign body aspiration, endobronchial lipoma, hamartoma, or papilloma), and malignant processes (such as carcinoid tumor or lung malignancies) causing obstruction of large airways. Mucous plugging that may appear hyperattenuated on computed tomography seems to be a particularly distinctive feature of ABPA, probably more common in India, with a high propensity for early relapse and corticosteroid dependence. Mucoid impaction associated with bronchiectasis is treated with maneuvers to promote airway clearance (chest physiotherapy, positive expiratory pressure and vibration devices, mucolytics, nebulized hypertonic saline) and treatment of airway infection (antimicrobial agents). Mucoid impaction associated with features of asthma and hypersensitization to *Aspergillus* is treated as for ABPA [417].

Bronchocentric granulomatosis is a form of ABPA that is characterized histopathologically by necrotizing granulomas with airway obstruction that destroy the bronchioles, but there is no tissue invasion by *Aspergillus*. Bronchoscopic findings include impaction of airway lumen by mucin and cellular debris. Treatment is similar to that of ABPA (see Recommendations 92–94 below) [419].

Invasive TBA is an uncommon disease that originates in the airway but may invade more deeply [417, 420]. It has been described most commonly in immunosuppressed patients (patients with hematologic malignancies, lung transplant or HSCT recipients, and patients on high-dose steroids). However, invasive TBA among patients with no known immunosuppression or following influenza infection has also been described [421, 422]. Invasive TBA consists of 2 forms: ulcerative and pseudomembranous [417, 423]. These 2 forms may represent different states of the same disease process that involves *Aspergillus* invasion of the tracheal or bronchial mucosa, which can extend into the cartilage. The ulcerative form is characterized by discrete ulcerative or plaque-like lesions in the bronchial wall. This form is most commonly observed in lung transplant recipients or patients with AIDS [417, 423]. The pseudomembranous form is characterized by extensive membranes overlying the tracheal or bronchial mucosal surface. It is most commonly reported in severely immunocompromised patients with hematologic malignancies or those HSCT recipients with GVHD. Rarely, it has been linked to postinfluenza syndrome. In general, the ulcerative form carries a better prognosis than the pseudomembranous form. Treatment includes systemic antifungal therapy with a mold-active triazole agent or a lipid formulation of AmB. Follow-up bronchoscopy might be necessary to follow progression. Repeated bronchoscopies might be indicated for clearance of pseudomembranes and/or mucous plugs. The procedure might be complicated by bleeding, especially in the setting of necrotizing pseudomembranes with extension

into pulmonary vessels, and should be performed by experienced interventional bronchoscopists.

TBA is most commonly described in lung transplant recipients, affecting 4%–6% of patients [423, 424]. Potential underlying factors include the high rate of *Aspergillus* colonization both pre- and post-lung transplant, the direct exposure of the allograft lung to the environment, reduced mucociliary clearance, pulmonary denervation, and higher degree of immunosuppression than other organ transplant [425]. TBA typically occurs within 3–6 months of lung transplant, presumably as a result of airway ischemia due to disruption of bronchial vasculature during the transplant procedure. Furthermore, ischemic reperfusion injury might lead to airway stricture and other abnormalities that predispose to *Aspergillus* colonization and disease. Most lesions are asymptomatic and diagnosed by surveillance bronchoscopy; they manifest as pseudomembranes, ulceration, black eschar, or plaques. Rare cases of obstructing bronchial aspergillosis and TBA with bronchopleural fistulae have also been described. These lesions can develop despite systemic antifungal prophylaxis. Although TBA can progress to involve the lungs and disseminate, the overall outcome is better than that of IPA. Improved outcomes might result from early diagnosis based on surveillance bronchoscopy that is routinely performed in lung transplant. We recommend a mold-active triazole or intravenous lipid formulation of AmB based on case series. If the lesion develops while the patient is on antifungal prophylaxis, optimization of antifungal dosing with TDM is indicated. We also recommend adjunctive aerosolized AmB because the anastomotic site is devascularized, making it difficult for parenteral therapies to achieve therapeutic concentrations. Pseudomembranous TBA might be adjunctively treated with bronchoscopic debridement. Airway stenosis resulting from TBA might require balloon dilation, laser treatment, or stent placement. Endobronchial TBA with anastomotic dehiscence might need stent placement or surgical repair [426]. Duration of therapy for TBA is not well studied, but we recommend at least 3 months of systemic antifungal therapy with or without aerosolized AmB or until TBA is completely resolved, whichever is longer.

MANAGEMENT OF EXTRAPULMONARY ASPERGILLOSIS

What Are the Treatment Considerations for Central Nervous System Aspergillosis?

Recommendation.

50. We recommend voriconazole as primary therapy for CNS aspergillosis (*strong recommendation; moderate-quality evidence*). Lipid formulations of AmB are reserved for those intolerant or refractory to voriconazole (*strong recommendation; moderate-quality evidence*).

Evidence Summary. CNS aspergillosis is a devastating complication with a poor prognosis in the vast majority of

affected patients [427]. Tenets of management include attempts to establish an early diagnosis, administration of an appropriate antifungal agent, assessment of the need for surgical intervention, and attempts to mitigate immunologic impairment(s) that led to CNS aspergillosis [428].

Diagnosis is suggested by the presence of focal neurologic deficits or seizures in the immunocompromised host, while meningeal signs are uncommon. CT and MRI are essential for the detection of infection and monitoring response to therapy. The radiographic pattern is dependent on the source of infection with direct extension from the sinuses, eye, or middle ear often causing only a single abscess within the frontal or temporal lobe, and those developing from hematogenous dissemination causing solitary or multiple small abscesses most frequently at the gray-white junction. Vascular invasion may occur and rupture with the development of a hemorrhagic or ischemic stroke, subarachnoid hemorrhage, or empyema formation. Definitive diagnosis is dependent on recovery of the organism, or examination of biopsy findings. Biopsy of lesions within the CNS is not always practical and infection of the CNS is commonly inferred by recovery of *Aspergillus* spp from a pulmonary or sinus source coincident with a characteristic brain lesion. The value of screening patients with IPA for asymptomatic CNS disease has not been determined.

Detection of GM [429] or (1 → 3)-β-D-glucan from the cerebrospinal fluid [430] is helpful in the diagnosis of CNS aspergillosis; however, other fungal pathogens also have positive results with these assays (eg, *Fusarium* spp) [431]. PCR assays have been examined for CNS aspergillosis, but these have not been standardized for widespread use [87].

Surgical intervention is frequently discussed during the care of patients with CNS aspergillosis as resection of infected tissue or abscesses eliminates areas containing viable fungi. A mortality benefit of surgery for the management of cerebral lesions, in combination with antifungal therapy with voriconazole, has been shown in a retrospective study of 81 patients [432]. Although this study was subject to selection bias for those patients who were ultimately able to undergo surgical intervention, a benefit of voriconazole followed by surgical intervention was suggested (HR, 2.1; 95% CI, 1.1–3.9; *P* = .2). Surgical intervention is also a useful adjunct in the management of CNS aspergillosis with contiguous infections of the paranasal sinuses or vertebral bodies and should be pursued in these circumstances when feasible.

The reversal or reduction of immunosuppression is essential in attempts to improve outcomes and should be managed in the same fashion as discussed elsewhere in this document.

Recommendations for the treatment of CNS aspergillosis with voriconazole are based primarily on open-label studies. In a direct comparative trial between AmB deoxycholate and voriconazole, a trend toward improvement of CNS aspergillosis in patients was noted in those who were treated with

voriconazole [348]. The open-label studies of voriconazole in adult and pediatric patients also demonstrate activity of voriconazole in the treatment of CNS aspergillosis [216, 432]. It should be noted that voriconazole interacts with some antiepileptic medications (phenytoin, phenobarbital) that may be coadministered in patients with CNS mass lesions, likely resulting in subtherapeutic concentrations.

Lipid formulations of AmB have demonstrated favorable responses in animal models and patients with CNS aspergillosis. Among lipid formulations of AmB formulations, favorable responses have been achieved in case reports with liposomal AmB, ABLC, and ABCD [433–435]. Itraconazole and posaconazole have also been successfully used in treatment of CNS aspergillosis [255, 436, 437], and case reports describe the efficacy of caspofungin and micafungin in the treatment of CNS aspergillosis [398, 438]. Combination therapy for CNS disease is initiated by some practitioners out of understandable lack of therapeutic options given the mortality associated with this form of dissemination, and a favorable response has been observed in animal models and some patients [197], yet there are no data suggesting better outcomes with this approach.

Progressive neurologic deficits have led to the use of corticosteroid therapy in patients with evolving CNS disease; however, this practice is deleterious and should be avoided. Intrathecal or intralesional antifungal therapy is also not recommended for the treatment of CNS aspergillosis due to a failure of AmB delivered intrathecally to penetrate beyond the pia mater. Delivery via this method also has the potential for AmB-induced chemical meningitis, arachnoiditis, seizures, headache, or altered mental status [439].

Epidural aspergillosis is an unusual manifestation of CNS aspergillosis that most often arises from extension into the epidural space from vertebral abscess [440]. Systemic antifungal therapy and surgical drainage are considered to be standards of practice for management of epidural aspergillosis; however, most of the experience in managing epidural aspergillosis is based on individual case reports and brief case series.

How Is *Aspergillus* Endophthalmitis Treated?

Recommendation.

51. We recommend that *Aspergillus* endophthalmitis be treated with systemic oral or intravenous voriconazole plus intravitreal voriconazole or intravitreal AmB deoxycholate (*strong recommendation: weak-quality evidence*).

Evidence Summary. Hematogenous endophthalmitis presents in immunocompromised and noncompromised patients as sudden loss of vision, usually in one eye, beginning with subretinal lesions that cause retinal necrosis and rapidly extend into the vitreous humor [441]. A dense vitritis forms over a few days. A vitreal aspirate or vitrectomy specimen yields *Aspergillus*, usually *A. fumigatus*, on culture and smear [442]. Visual loss

is usually permanent and enucleation often required for pain relief. Intravitreal voriconazole 100 µg or intravitreal AmB deoxycholate 5–10 µg appear to be essential in treatment, combined with systemic voriconazole [443]. Local concentration of drug is lower if intravitreal drug is injected at the end of a pars plana vitrectomy, lessening concern about retinal toxicity of AmB deoxycholate when that drug is used. Although intracameral injection (injection into the anterior chamber) has no role in aspergillosis of the posterior chamber, it has been reported that intracameral injection of voriconazole 100 µg was useful for extension of *Aspergillus* keratitis into the anterior chamber [444].

What Is the Role of Surgery in Aspergillosis of the Paranasal Sinuses?

Recommendation.

52. We recommend that both surgery and either systemic voriconazole or a lipid formulation of AmB formulation be used in invasive *Aspergillus* fungal sinusitis but that surgical removal alone can be used to treat *Aspergillus* fungal ball of the paranasal sinus. Enlargement of the sinus ostomy may be needed to improve drainage and prevent recurrence (*strong recommendation; moderate-quality evidence*).

Evidence Summary. In an uncomplicated *Aspergillus* fungal ball of the sinus, >90% being in the maxillary sinus, clinicians should remove the fungal ball, preferably using endoscopic techniques as this is usually curative. A wide maxillary antrostomy is done to improve sinus drainage, and a biopsy of the sinus wall is sometimes done to rule out mucosal invasion [445–447]. Local or systemic antifungals have no role in the treatment of a maxillary sinus fungal ball. *Aspergillus* fungal balls of the sphenoid sinus differ in that invasion into the cavernous sinus can occur from fungal invasion or excessive surgical debridement [448]. Systemic antifungal therapy may be advisable if there is a question of mucosal involvement, mucosal breach of the sphenoid sinus, or spread into the cavernous sinus. Local irrigation of the paranasal sinuses with AmB is not considered useful because topical AmB does not penetrate into tissues.

In granulomatous or chronic invasive and granulomatous aspergillosis of the paranasal sinus in immunocompetent patients, often diagnosed because of proptosis or extension to the brain or orbit, and in acute invasive paranasal sinusitis of severely immunocompromised patients, surgical debridement and systemic antifungal therapy is recommended. Sometimes multiple surgical procedures are required, and extensive debridement is best done once thrombocytopenia has resolved, to reduce the risk of postoperative hemorrhage. Voriconazole is the preferred therapy, or a lipid formulation of AmB; morbidity and mortality is high [158, 449, 450]. Allergic fungal rhinosinusitis (AFRS) is discussed elsewhere.

What Are the Treatment Recommendations for *Aspergillus* Endocarditis, Pericarditis, and Myocarditis?

Recommendation.

53. In *Aspergillus* endocarditis, we recommend early surgical intervention combined with antifungal therapy in attempts to prevent embolic complications and valvular decompensation (*strong recommendation; moderate-quality evidence*). Voriconazole or a lipid formulation of AmB is recommended as initial therapy (*strong recommendation; low-quality evidence*). Following surgical replacement of an infected valve, lifelong antifungal therapy should be considered (*strong recommendation; low-quality evidence*).

Evidence Summary. The diagnosis of *Aspergillus* endocarditis is often difficult and almost always delayed with the diagnosis made postmortem in up to one-third of cases [451]. Fever, the presence of a new murmur, and stigmata of peripheral emboli such as new neurologic deficits, heart failure, or dyspnea are the most commonly encountered clinical features and no different from those observed in bacterial endocarditis. Blood cultures are almost always negative, and examination of resected valvular tissue or emboli is the most common means of confirming the diagnosis. The converse is not true; positive blood cultures are more likely to be contaminants than indicating endocarditis. Noninvasive markers such as GM may be positive, but are not specific for the site of disease [452].

The aortic and mitral valves are those most frequently infected. Prior valvular abnormalities and/or prior valvular surgery predisposes to infection, although intravenous drug use and other cardiac procedures have also been presented as predisposing factors. Vegetations secondary to *Aspergillus* spp are often large and/or pedunculated and therefore embolic complications are common, particularly to large arteries. For this reason, imaging of the brain is prudent at the time of diagnosis in attempts to define the full spectrum of disease. Mortality rates are high (50%–96%). The mean survival period for *Aspergillus* endocarditis was 11 days in one study, further illustrating the rapid and frequently lethal course of this infection [453].

Combined medical therapy and valve replacement are essential in attempts to improve outcomes as neither alone has a significant influence on patient outcomes [419, 454], and attempts to manage patients with antifungal agents alone are rarely successful. Voriconazole or liposomal AmB (3–5 mg/kg/day) are recommended as first-line agents. Comparative data are not available; however, case reports [455], case series [451], and animal models [456] have suggested the efficacy of these agents in *Aspergillus* infective endocarditis (IE). Combination therapy may also be used, but no evidence regarding the superiority of this approach has been presented.

The overall poor survival of IE secondary to *Aspergillus* spp limits the available data on recurrence rates. In other causes of fungal endocarditis, recurrence may occur late and even years

after the initial diagnosis. For this reason, long durations of therapy (>2 years) and consideration of lifelong therapy should be considered concomitant with frequent clinical and echocardiographic assessment for possible recurrence [451].

Aspergillus pericarditis arises as the result of direct extension from: a contiguous focus of IPA, from a myocardial lesion, or intraoperative contamination [457, 458]. Pericardial tamponade may rapidly ensue, leading to hemodynamic deterioration and cardiac arrest. Diagnosis is suggested by pericardiocentesis (with positive culture or antigen testing), pericardiectomy, or pericardial biopsy. A combined medical and surgical approach, with pericardial resection or drainage, is necessary in attempts to optimize outcomes [458].

Aspergillus myocarditis may manifest as myocardial infarction, cardiac dysrhythmias, or myoepicarditis [457]. This infection generally occurs in the context of disseminated disease and requires systemic antifungal therapy. An intracardiac abscess may be seen on echocardiography, although in other cases no echocardiographic lesions are observed [459].

What Are the Treatment Recommendations for *Aspergillus* Osteomyelitis and Septic Arthritis?

Recommendation.

54. Surgical intervention is recommended, where feasible, for management of *Aspergillus* osteomyelitis and arthritis, combined with voriconazole (*strong recommendation; moderate-quality evidence*).

Evidence Summary. *Aspergillus* osteomyelitis occurs by one of 3 mechanisms: (1) direct inoculation secondary to trauma, surgery, or epidural injection; (2) contiguous spread from pleuropulmonary disease; or (3) hematogenous spread from either coexistent pulmonary infection or intravenous injection [460, 461]. Most patients have traditional risk factors for IA; however, up to 34% of patients have no obvious predisposing factor or immunosuppression [462]. Vertebral osteomyelitis with or without discitis is the most common form, and the predominance of cases involve the lumbar vertebrae. Back pain is the most common clinical manifestation, with neurologic deficits secondary to cord compromise, or kyphosis also observed. Diagnostic imaging with CT and/or MRI is essential for staging disease and for providing a guide for orthopedic and/or neurosurgical intervention. Diagnosis can be confirmed by isolation of the organism from bone specimens or an aspirate of an adjacent fluid collection.

In cases without significant instability or neural compression and no evidence of disease progression, antifungal treatment alone may be sufficient provided the underlying immunologic deficit can be corrected; however, it should be noted that favorable outcomes more frequently occur in those receiving combined medical and surgical therapy [460]. In cases with spinal instability or symptoms consistent with spinal cord or radicular compression or abscess formation, surgical decompression in

combination with antifungal therapy is recommended [462]. The type and extent of surgery should be individualized.

Voriconazole has been successfully used as salvage and primary therapy, either alone or in combination with surgical debridement [463, 464], and has been shown to be superior to AmB in cases of disseminated aspergillosis [348]. Historical experience has shown the efficacy of AmB formulations. Itraconazole has been used subsequent to a course of AmB. There is little reported experience in the use of posaconazole or echinocandins in the treatment of *Aspergillus* osteomyelitis [465]. Therapy should be continued for a minimum of 8 weeks, with longer courses (>6 months) frequently necessary [460, 461].

Aspergillus arthritis may develop from hematogenous dissemination in immunocompromised patients, via injection, or by direct traumatic inoculation in immunocompetent hosts [466]. In many cases, *Aspergillus* arthritis arises as an extension from a contiguous focus of *Aspergillus* osteomyelitis [466]. Most of the successfully treated cases of *Aspergillus* arthritis have responded to combined medical therapy and drainage of the joint and/or synovectomy [467]. Historically, AmB formulations have demonstrated efficacy in cases of arthritis [466], although more recent data have shown an improvement in response rates when voriconazole is administered, which is the recommended antifungal agent in this setting [468].

What Are the Treatment Recommendations for Cutaneous Aspergillosis?

Recommendations.

55. As cutaneous lesions may reflect disseminated infection, we recommend treatment with voriconazole in addition to evaluation for a primary focus of infection (*strong recommendation; low-quality evidence*).

56. In cases of aspergillosis in burns or massive soft tissue wounds, surgical debridement is recommended, in addition to antifungal therapy (*strong recommendation; moderate-quality evidence*).

Evidence Summary. Cutaneous aspergillosis may develop in the context of hematogenous dissemination in the immunocompromised host or can occur in the context of traumatic or nosocomial device-related infection or in burn victims, and represents a heterogeneous disease [11, 469, 470]. The initial lesions of cutaneous aspergillosis may appear as macules, papules, nodules, or plaques. Pustules or lesions with purulent discharge generally occur in neonates [9]. Unlike IPA, which requires thoracic surgery or thoracoscopy to remove foci of infection, the eradication of cutaneous aspergillosis may be accomplished with considerably less risk [471]. Therefore, surgical intervention, for primary cutaneous infection, may be a useful adjunct to antifungal therapy. Biopsy for confirmation of mycological diagnosis is essential to distinguish aspergillosis from other potential pathogens (eg, fusariosis, mucormycosis) [472]. Skin biopsy should be taken from the center of the lesion and reach the

subcutaneous fat to visualize hyphae invading blood vessels of the dermis and subcutaneous tissues [9].

What Are the Treatment Recommendations for Aspergillus Peritonitis?

Recommendation.

57. We recommend prompt peritoneal dialysis catheter removal accompanied by systemic antifungal therapy with voriconazole (*strong recommendation; low-quality evidence*).

Evidence Summary. *Aspergillus* peritonitis may occur as a complication of chronic ambulatory peritoneal dialysis [473]. Although *Candida* species are the most common cause of fungal peritonitis complicating chronic ambulatory peritoneal dialysis and fungal peritonitis typically occurs following an episode of bacterial peritonitis, *Aspergillus* species are an additional and well-established cause of this infection [474]. The diagnosis can be suggested by detection of (1 → 3)-β-D-glucan and GM in the peritoneal fluid, or confirmed by culture of peritoneal fluid [475]. In rare cases, peritoneal biopsy is required, although this is typically accomplished concurrently with peritoneal dialysis catheter removal [476].

Removal of the dialysis catheter is essential in cases of fungal peritonitis and has been associated with improved survival. In cases where the catheter cannot be promptly removed, some practitioners use intraperitoneal AmB in conjunction with voriconazole, but it should be recognized that intraperitoneal AmB administration may cause a chemical peritonitis and is not recommended by this panel [477]. In most cases the catheter should be immediately removed.

Following catheter removal, systemic antifungal therapy is required. Intravenous AmB formulations result in suboptimal and, in many cases, undetectable peritoneal drug concentrations [478, 479]. Systemic therapy with voriconazole for 6–8 weeks is thus recommended based on successful reports and adequate peritoneal concentrations in conjunction with catheter removal [480, 481]. Posaconazole and the echinocandins have been successfully used in fungal peritonitis from other causes and may have utility as salvage therapy in *Aspergillus* peritonitis [482]. Following treatment, a minority of patients may successfully return to peritoneal dialysis.

What Are the Treatment Recommendations for Esophageal, Gastrointestinal, and Hepatic Aspergillosis?

Recommendations.

58. We suggest voriconazole and surgical consultation in attempts to prevent complications of hemorrhage, perforation, obstruction, or infarction (*weak recommendation; low-quality evidence*).

59. We suggest antifungal therapy with voriconazole or a lipid formulation of AmB as initial therapy for hepatic aspergillosis. For extrahepatic or perihepatic biliary obstruction, or

localized lesions that are refractory to medical therapy, surgical intervention should be considered (*weak recommendation; low-quality evidence*).

Evidence Summary. Aspergillosis of the esophagus and gastrointestinal tract is relatively common in advanced cases of disseminated IA [483]. In fact, in autopsy studies, esophageal and gastrointestinal tract involvement is the third most common site of infection [483]. Disease may occur through hematogenous dissemination or ingestion, and some authors have suggested the gastrointestinal tract as a potential portal of entry for *Aspergillus* spp [484], although this has not been definitively demonstrated. The few well-documented cases have been associated with high morbidity and mortality and the diagnosis is infrequently made antemortem [485]. Because of the paucity of data for esophageal and gastrointestinal aspergillosis, there is no clear indication of optimal therapy, and a rational approach is to combine both medical and surgical therapy [486].

Hepatic aspergillosis may occur as single or multiple hepatic lesions. Dissemination to the liver is thought to occur via the portal venous system from the gastrointestinal tract, or as a component of general and widespread systemic dissemination [487]. Cholangitis secondary to *Aspergillus* spp is exceedingly uncommon, but has been described following biliary surgery [488]. Reports of therapeutic interventions are limited. Medical therapy for hepatic abscesses may be effective and preclude the need for surgical resection.

What Are the Treatment Recommendations for Renal Aspergillosis?

Recommendation.

60. We suggest a combined approach of medical and urologic management for renal aspergillosis. Obstruction of one or both ureters should be managed with decompression if possible and local instillation of AmB deoxycholate. Parenchymal disease is best treated with voriconazole (*weak recommendation; low-quality evidence*).

Evidence Summary. Renal aspergillosis may develop as single or multiple parenchymal abscesses, usually as a result of hematogenous dissemination, or may present as a fungal ball in the pelvis of the kidney [489, 490]. This form of aspergillosis may cause hematuria, ureteropelvic obstruction from a fungal ball, perinephric abscess with extension into surrounding tissues, or passing of fungal elements into the urine.

Reports of management are limited to individual cases. Medical management alone may be successful if abscesses are relatively small. Management of larger abscesses may require surgical drainage. Microwave ablation has been successfully used as an adjunct to antifungal therapy in a single patient deemed a poor surgical candidate [491]. Nephrectomy should be performed only as a last option. Voriconazole, posaconazole, itraconazole, AmB formulations, and the echinocandins all exhibit poor urinary concentrations [492]. Irrigation via a nephrostomy tube with

AmB deoxycholate allows high local concentrations and when given by this route is not absorbed and is not nephrotoxic. It thus may be useful in aspergillosis of the renal pelvis, but has no role in the treatment of parenchymal disease [493].

What Are the Treatment Regimens for Aspergillus Ear Infections? Recommendations.

61. Noninvasive *Aspergillus* otitis externa, also called otomycosis, is treated by thorough mechanical cleansing of the external auditory canal followed by topical antifungals or boric acid (*strong recommendation; moderate-quality evidence*).
62. We recommend that clinicians treat IA of the ear with a prolonged course of systemic voriconazole, usually combined with surgery (*strong recommendation; low-quality evidence*).

Evidence Summary. It is important to distinguish otomycosis, a common entity in healthy persons, from IA of the ear, which is rare and occurs in immunosuppressed persons and diabetic individuals. In otomycosis, *Aspergillus* species, often *Aspergillus niger*, grows on cerumen and desquamated cells in an external auditory canal but does not invade the lining [494, 495]. IA can involve the external auditory canal, middle ear, mastoid, or petrous portion of the temporal bone. When invasion begins in the external auditory canal, infection has been called malignant otitis externa. Tissue-invasive *Aspergillus* otitis should be treated with prolonged systemic antifungals [448], preferably with voriconazole, usually preceded by surgical debridement [496–499]. Colonization of the middle ear and mastoid by *Candida*, *Aspergillus*, or other molds can occur in patients with chronic otitis media in the presence of a perforated tympanic membrane, usually following multiple surgical procedures and many courses of antibacterial agents. In the absence of evidence of tissue invasion, we do not recommend that colonization should be treated [500].

What Are the Treatment Recommendations for Aspergillus Keratitis?

Recommendation.

63. We recommend that clinicians treat *Aspergillus* keratitis with topical natamycin 5% ophthalmic suspension or topical voriconazole (*strong recommendation; moderate-quality evidence*).

Evidence Summary. Clinicians should treat *Aspergillus* keratitis with topical natamycin 5% ophthalmic suspension. In case series and randomized clinical trials of fungal keratitis, topical voriconazole 1% was inferior to natamycin, but *Fusarium* keratitis appeared to account for most of the difference [501–504]. Voriconazole for infusion, reconstituted with water to 1%, is a reasonable alternative for *Aspergillus* keratitis. Diagnosis should be confirmed by smear and culture of corneal scrapings [505]. Confocal microscopy and anterior segment coherence tomography are useful to monitor therapeutic response [505].

Ophthalmologists should consider penetrating keratoplasty for patients who do not respond to topical therapy, though patients with lesions extending to the corneal limbus, with corneal perforation or hypopyon, are at high risk of recurrence [506].

How Should *Aspergillus* Bronchitis Be Diagnosed and Treated in the Nontransplant Population?

Recommendations.

64. We suggest the diagnosis of aspergillus bronchitis in non-transplant patients be confirmed by detection of *Aspergillus* spp in respiratory secretions, usually sputum, with both PCR and GM on respiratory samples being much more sensitive than culture (*weak recommendation; low-quality evidence*).
65. We suggest treatment with oral itraconazole or voriconazole with TDM (*weak recommendation; low-quality evidence*).

Evidence Summary. *Aspergillus* is a cause of acute or chronic bronchitis usually seen as a complication of CF or bronchiectasis [83, 507, 508]. Its clinical features are not distinctive in CF, but include a more rapid decline in FEV₁ than those without ABPA or *Aspergillus* sensitization. It affects up to approximately 30% of adults with CF [509]. Patients present with recurrent, frequently relapsing acute bronchitis with thick sputum plugging and shortness of breath. Occasional patients develop mucoid impaction, or so-called “plastic bronchitis,” requiring urgent bronchial toilet. Identification of *Aspergillus* in airway secretions with culture, PCR, or GM is essential for the diagnosis, and elevated *Aspergillus* IgG serology is supportive of the diagnosis [507, 508]. Several *Aspergillus* species may be implicated.

It is likely that antifungal therapy is helpful in both CF and bronchiectasis by reducing the burden of organisms and thus reducing the inflammatory immune response [508, 510], but this has not been systematically studied. Itraconazole or voriconazole are first-line agents. Patients who fail one azole agent may respond to a different azole. Relapse after improvement during antifungal therapy is common; long-term suppressive therapy may be necessary for symptom control. Triazole antifungal resistance has been documented, and so susceptibility testing is valuable. The role of inhaled antifungal therapy is uncertain.

PROPHYLAXIS OF INVASIVE ASPERGILLOSIS

V. What Are the Recommended Prophylactic Regimens, Who Should Receive Them, and How Should Breakthrough Infection Be Managed? In Which Patients Should Antifungal Prophylaxis Against Aspergillosis Be Used?

Recommendation.

66. We recommend prophylaxis with posaconazole (*strong recommendation; high-quality evidence*), voriconazole (*strong recommendation; moderate-quality evidence*), and/or micafungin (*weak recommendation; low-quality evidence*) during

prolonged neutropenia for those who are at high risk for IA (*strong recommendation; high-quality evidence*). Prophylaxis with caspofungin is also probably effective (*weak recommendation; low-quality evidence*). Prophylaxis with itraconazole is effective, but therapy may be limited by absorption and tolerability (*strong recommendation; moderate-quality evidence*). Triazoles should not be coadministered with other agents known to have potentially toxic levels with concurrent triazole coadministration (eg, vinca alkaloids and others) (*strong recommendation; moderate-quality evidence*).

Evidence Summary. Hematologic disorders with poorly functioning neutrophils (eg, aplastic anemia and variants thereof, MDS), acute leukemia with repeated and/or prolonged neutropenia, [511], or a history of IA prior to transplantation [512] have been identified as significant risk factors for IA.

A 2007 large randomized clinical trial of oral posaconazole solution demonstrated its superiority vs fluconazole or itraconazole in the prevention of IA among patients with AML and MDS undergoing chemotherapy [292]. This study demonstrated higher survival for patients in the posaconazole arm, although there was greater toxicity among recipients of posaconazole, compared with the fluconazole/itraconazole arm. With the approval of an extended-release tablet form of posaconazole, as well as an intravenous form, dosing will be different compared to the randomized prophylaxis trials, which used a solution formulation, and needs further evaluation in HSCT patients.

A previous trial compared voriconazole or fluconazole prophylaxis in allogeneic HSCT recipients; both arms were monitored with GM measurements [513]. *Aspergillus* infections were less frequent with voriconazole than with fluconazole prophylaxis, but the 180-day fungal-free survival and overall survival were not different [513]. In another trial, voriconazole was used as prophylaxis for leukemia patients with about 3 weeks of neutropenia during a construction risk period; less aspergillosis was noted among patients receiving prophylaxis ($P = .04$) [514]. Voriconazole has also been used among children as prophylaxis, although children require different dosing [515]. Voriconazole requires careful monitoring in children [516]. Patients receiving voriconazole prophylaxis remain at risk for both *Aspergillus* and non-*Aspergillus* fungal pathogens that are intrinsically resistant to this agent [517, 518].

A 2004 large, randomized prophylaxis trial comparing micafungin or fluconazole prophylaxis found that the composite endpoint of treatment success was significantly better among those receiving micafungin prophylaxis ($P = .03$), as there was less empiric AmB treatment during neutropenia (15.1% vs 21.4%), fewer breakthrough fungal infections (1.6% vs 2.4%), and less yeast colonization among those receiving micafungin prophylaxis ($P = .03$) [519]. There was a trend toward reduced breakthrough aspergillosis infections (0.2% vs 1.5%; $P = .07$), but micafungin was not approved by the FDA for prophylaxis

of aspergillosis [519]. In clinical practice, the requirement for daily intravenous therapy with echinocandins may lead to a change to oral azole therapy at a time not studied in clinical trials, but these agents may be useful for prophylaxis when drugs that are contraindicated with triazoles (such as cyclophosphamide or vincristine) are required.

Caspofungin has been studied in smaller settings. The efficacy and safety of caspofungin was similar to other prophylactic regimens, in the setting of a low incidence of IFI [520–523].

Itraconazole may be effective, but the conclusions of several prospective trials regarding efficacy are limited, because study designs did not include patients at significant risk for aspergillosis [523–527]. Itraconazole oral capsules have erratic bioavailability [528]. Because there was an increase in transplant-related mortality when itraconazole was used together with cyclophosphamide during the conditioning regimen for HSCT, azole dosing is now delayed until after the stem cell product infusion [529].

Earlier studies of antifungal prophylaxis in hematologic malignancies are summarized in several large meta-analyses [524, 530, 531]. Among the studies that investigated parenterally administered AmB deoxycholate or liposomal formulations of AmB for prophylaxis, most have been historically controlled, and some have suggested a reduction in IA. Several prospective, randomized trials using polyene therapy have demonstrated a reduction in the number of IFIs, but none have demonstrated a significant reduction of IA in a prospective, randomized study [532–534]. Aerosolized AmB formulations have been shown to reduce the incidence of IPA, notably in lung transplant recipients [177].

What Are the Recommended Prophylactic Regimens for Patients With Graft-Versus-Host Disease?

Recommendations.

67. We recommend prophylaxis with posaconazole for allogeneic HSCT recipients with GVHD who are at high risk for IA (*strong recommendation; high-quality evidence*). Prophylaxis with other mold-active azoles is also effective. Voriconazole is commonly used for prophylaxis against IA in high-risk patients but did not show improved survival in clinical trials (*strong recommendation; moderate-quality evidence*). Prophylaxis with itraconazole is limited by tolerability and absorption (*strong recommendation; high-quality evidence*).

68. We recommend continuation of antifungal prophylaxis throughout the duration of immunosuppression in patients with chronic immunosuppression associated with GVHD (corticosteroid equivalent of >1 mg/kg/day of prednisone for >2 weeks and/or the use of other anti-GVHD therapies, such as lymphocyte-depleting agents, or TNF- α inhibition, for refractory GVHD) (*strong recommendation; high-quality evidence*).

Evidence Summary. A randomized clinical trial of posaconazole prophylaxis during GVHD in HSCT recipients found a significant reduction in proven and probable IFIs and similar

toxicity in posaconazole recipients, compared with those receiving fluconazole, which has no mold activity [254]. Since this time, posaconazole extended-release tablets have become available and have replaced the use of oral solution at many centers and may further improve serum posaconazole levels without clinically relevant hepatotoxicity [244].

A 2010 large, randomized clinical trial of voriconazole prophylaxis following allogeneic transplant continued the antifungal prophylaxis to day 180 for higher-risk patients such as those with GVHD [513]. *Aspergillus* infections were less frequent with voriconazole than with fluconazole, but fungal-free survival and overall survival were no different [513]. Voriconazole provided effective prophylaxis when added specifically during corticosteroid therapy for GVHD [535]. Voriconazole has also been assessed among children as prophylaxis starting from the time of transplant, and then continued for those patients with acute GVHD [515]. Acute GVHD is a risk factor for hepatotoxicity attributable to voriconazole that requires careful monitoring in this setting [536]. The use of itraconazole for prophylaxis against *Aspergillus* during GVHD as in other populations is complicated by erratic bioavailability and drug toxicity [528, 537]. Patients receiving voriconazole or itraconazole prophylaxis remain at risk for both *Aspergillus* and non-*Aspergillus* fungal pathogens that are intrinsically resistant to this agent [517, 518].

What Are the Recommendations for Antifungal Prophylaxis in Lung Transplant Patients?

Recommendations.

69. We recommend antifungal prophylaxis with either a systemic triazole such as voriconazole or itraconazole or an inhaled AmB product for 3 to 4 months after lung transplant (*strong recommendation; moderate-quality evidence*).

70. Systemic voriconazole or itraconazole is suggested over inhaled AmB for lung transplant recipients with mold colonization pre- or post-lung transplant, mold infections found in explanted lungs, fungal infections of the sinus, and single-lung transplant recipients (*weak recommendation; low-quality evidence*).

71. We recommend reinitiating antifungal prophylaxis for lung transplant recipients receiving immunosuppression augmentation with either thymoglobulin, alemtuzumab, or high-dose corticosteroids (*strong recommendation; moderate-quality evidence*).

Evidence Summary. Antifungal prophylaxis for lung transplant recipients is commonplace at many centers but is not employed universally [538]. Furthermore, the types of prophylaxis (inhaled or systemic), antifungal agents used, and duration of prophylaxis also vary [538, 539]. To date, there have been no prospective comparative trials evaluating the long-term benefit of antifungal prophylaxis among lung transplant recipients. Retrospective and observational studies with historical controls showed lower rates of IFIs among patients receiving antifungal

prophylaxis [540–543]. Given these data, the presence of damaged airways early after transplant (see TBA above), high levels of immunosuppression following lung transplant, and poor outcomes of IFIs, it is reasonable to consider antifungal prophylaxis in the early posttransplant period.

Aerosolized AmB formulations have been shown to protect lung transplant recipients from pulmonary fungal infections [540]. There is no evidence that one formulation of AmB is superior to others, but AmB deoxycholate is associated with more side effects than other formulations, including cough, bronchospasm, taste disturbance, and nausea as well as difficulty in administering the drug [176, 182, 183, 540, 544–546]. The longer tissue half-life of the lipid formulations of AmB also permits less frequent administration [183]. An advantage of inhaled AmB is the lack of systemic adverse effects and/or drug–drug interactions; a disadvantage is its inability to prevent extrapulmonary fungal infections. Systemic voriconazole and itraconazole are also effective in preventing IFI [425, 542]. To date, there is no evidence that one agent is superior to the other. Azole prophylaxis is complicated by drug interactions with the calcineurin inhibitors, as well as liver toxicity. It should be noted that antifungal prophylaxis might only delay the onset of IFI [547], as the allograft is exposed to the environment, and patients are maintained on relatively high doses of immunosuppression lifelong.

In the absence of a head-to-head comparative trial of inhaled AmB vs a systemic mold-active antifungal, we suggest that systemic voriconazole or itraconazole be considered for (1) patients colonized with *Aspergillus* or other pathogenic molds pre- or post-lung transplant [548, 549]; (2) patients with evidence of mold infections found in explanted lungs [550]; (3) patients with evidence of fungal infections in the sinus; and (4) single-lung transplant recipients [551]. For the remaining patients, inhaled AmB or systemic voriconazole or itraconazole might be equally effective. Posaconazole solution may not be ideal for prophylaxis in the early period after lung transplant, as many patients have gastrointestinal or nutritional issues and are taking a proton pump inhibitor as routine posttransplant prophylaxis for gastroesophageal reflux. There are no data on the efficacy and safety of the intravenous or tablet formulations of posaconazole for prophylaxis early after transplant.

A benefit to continuing antifungal prophylaxis beyond 3–4 months after lung transplant has not been established. Beyond this period of high risk, we suggest antifungal prophylaxis only in the setting of severe rejection requiring thymoglobulin or alemtuzumab, or high-dose and prolonged use of corticosteroids.

What Are the Recommendations for Antifungal Prophylaxis in Nonlung Solid Organ Transplant Recipients?

Recommendation.

72. We recommend prophylactic strategies in SOT recipients based on the institutional epidemiology of infection and assessment of individual risk factors (*strong recommendation; low-quality evidence*).

Prospective trials are lacking to address the need for routine anti-*Aspergillus* prophylaxis other than for lung transplant recipients. Individual risk factors have been identified in cardiac (pretransplant colonization, reoperation, CMV infection, renal dysfunction, institutional outbreak), liver (fulminant hepatic failure, reoperation, retransplantation or renal failure), and others with institutional outbreaks or prolonged or high-dose corticosteroid use. In such patients, the optimal duration of prophylaxis is not known.

Evidence Summary. Invasive *Aspergillus* infection occurs in up to 19% of all SOT recipients (estimated 0.65% per year), with recent mortality estimates of approximately 22% [40, 43, 552–554]. The incidence of infection varies with the organ transplanted, including recipients of liver (1%–9.2%) [553, 555–557], heart (1%–14%) [558, 559], kidney (0.7%–4%) [553, 556, 560, 561], and pancreas 3.4% [40, 560, 562]. The risks for IFI in general, and for *Aspergillus* infections in particular, are increased by patient-specific factors including the need for organ retransplantation (liver), posttransplant renal or hepatic failure with renal replacement therapy (liver and kidney), reexploration (liver and heart), pretransplant colonization with *Aspergillus* spp (heart), concurrent CMV infection (liver and heart), hepatitis C infection (liver), and steroid-based regimens [43, 556, 563–566]. The overall intensity of immunosuppression and the chronicity of systemic illness (malnutrition, hypogammaglobulinemia, and leukopenia) in the organ recipient is a general risk for IFI [40, 562]. Pulse-dosed corticosteroid therapy with lymphocyte depletion is a notable risk in the *Aspergillus*-colonized individual [562]. Infections tend to occur both early after transplantation (first month) and late (mean approximately 184 days) [40, 43]. Targeted antifungal prophylaxis varies with the immunosuppressive regimen and local epidemiology of infections [567–570].

MANAGEMENT OF BREAKTHROUGH INFECTION

How Should Breakthrough Aspergillosis Be Managed?

Recommendation.

73. We suggest an individualized approach that takes into consideration the rapidity and severity of infection and local epidemiology. As principles, we recommend an aggressive and prompt attempt to establish a specific diagnosis with bronchoscopy and/or CT-guided biopsy for peripheral lung lesions. Documentation of serum azole levels should be verified if TDM is available for patients receiving mold-active triazoles. Antifungal therapy should be empirically changed to an alternative class of antifungal with *Aspergillus* activity. Other considerations include reduction of underlying immunosuppression if feasible, and susceptibility testing of any *Aspergillus* isolates recovered from the patient (*weak recommendation; moderate-quality evidence*).

Evidence Summary. Breakthrough aspergillosis typically occurs in the setting of antifungal prophylaxis. There is a paucity of organized experience on the best way to manage these patients [571]. Documented breakthrough aspergillosis occurs infrequently, in no more than 3% of patients in modern “real life” series of patients receiving mold-active prophylaxis [285]. If the patient develops breakthrough aspergillosis in the setting of non-mold-active prophylaxis (eg, fluconazole), we recommend the same approach for treatment of IA in the absence of prophylaxis. In a patient who develops breakthrough aspergillosis in the setting of mold-active prophylaxis (posaconazole, voriconazole, itraconazole, echinocandins), a “salvage” treatment plan individualized to patient circumstances and comorbidities is required. A typical approach would be to administer broad-spectrum antifungal therapy until the diagnosis is established and a response to treatment can be documented. For patients with apparent breakthrough aspergillosis on prior voriconazole, a lipid formulation of AmB (3–5 mg/kg/day) is recommended, especially in centers where mucormycosis is seen [572]. Knowledge of local epidemiology is essential for the selection of antifungal regimens for breakthrough aspergillosis.

In patients with breakthrough aspergillosis while on voriconazole prophylaxis, there are limited data suggesting that posaconazole retains its activity [573]. In patients with breakthrough aspergillosis while on posaconazole prophylaxis, some data support the use of an alternative triazole as salvage therapy, such as voriconazole or isavuconazole [256]. The benefits of combination antifungal therapy for breakthrough aspergillosis are unknown. If a decision is made to use combination therapy, we favor the initial use of a combination of antifungal agents from different classes than the antifungal the patient was initially receiving when the breakthrough aspergillosis was diagnosed.

Documentation of serum trough antifungal levels, especially for triazole antifungals, which may be prone to wide pharmacokinetic variability, can aid in the evaluation of patients with breakthrough aspergillosis. Several case series have reported that breakthrough aspergillosis in the setting of “therapeutically adequate” voriconazole exposures (recent trough >1 µg/mL) may favor the diagnosis of breakthrough mucormycosis over aspergillosis [218]. In some countries, breakthrough aspergillosis with multiazole-resistant *Aspergillus* species has been described, but the prevalence of these strains in many centers in the United States is unknown [574]. The replacement of posaconazole solution with intravenous and extended-release tablets may reduce the frequency of extremely low serum concentrations. Further studies are needed to address whether TDM is helpful or necessary with the extended-release or intravenous formulations of posaconazole or for isavuconazole.

Diagnosis requires the early use of chest/sinus CT and *Aspergillus* GM, although CT can show atypical lesions [143] and serum GM is frequently negative or “low positive” in patients

receiving mold-active agents preexposure. Although the yield of bronchoscopy in these patients might be low, it is recommended, as coinfections simulating breakthrough aspergillosis are not uncommon [575]. Furthermore, recent data indicate that the yield of GM in BAL is not affected by the presence of a mold-active agent [576]. In case there is growth of *Aspergillus* in a patient with breakthrough *Aspergillus* pneumonia, it would be prudent to document the susceptibility of the cultured isolate (using a reference method) because the patient will need secondary prophylaxis with a triazole antifungal after the initial treatment phase is completed.

VI. When Should Patients Be Treated Empirically?

What Strategies Are Recommended for Empiric and Preemptive Strategies in Allogeneic Hematopoietic Stem Cell Transplant Recipients and Patients Treated for Acute Myelogenous Leukemia? Recommendations.

74. Empiric antifungal therapy is recommended for high-risk patients with prolonged neutropenia who remain persistently febrile despite broad-spectrum antibiotic therapy. Antifungal options include a lipid formulation of AmB (*strong recommendation; high-quality evidence*), an echinocandin (caspofungin or micafungin) (*strong recommendation; high-quality evidence*), or voriconazole (*strong recommendation; moderate-quality evidence*).
75. Empiric antifungal therapy is not recommended for patients who are anticipated to have short durations of neutropenia (duration of neutropenia <10 days), unless other findings indicate a suspected IFI (*strong recommendation; moderate-quality evidence*).
76. The use of serum or BAL fungal biomarkers such as GM or (1 → 3)-β-D-glucan to guide antifungal therapy in asymptomatic or febrile high-risk patients (often referred to as preemptive or biomarker-driven antifungal therapy) can reduce unnecessary antifungal therapy. The preemptive approach can result in more documented cases of IPA without compromise in survival and can be used as an alternative to empiric antifungal therapy (*strong recommendation; moderate-quality evidence*).
77. Early initiation of antifungal therapy in patients with strongly suspected IPA is warranted while a diagnostic evaluation is conducted (*strong recommendation; moderate-quality evidence*).
78. Management of suspected or documented breakthrough IPA in the context of mold-active azole prophylaxis or empiric suppressive therapy is not defined by clinical trial data, but a switch to another drug class is suggested (*weak recommendation; low-quality evidence*).

Evidence Summary. This area has been reviewed in a related 2010 guideline from the IDSA [577]. Early reports from the National Cancer Institute and the EORTC underscored the

importance of early initiation of therapy for treatment of IA and other IFIs [145, 175, 577–579]. These small randomized, nonplacebo, open-label trials demonstrated that high-risk neutropenic patients with persistent fever despite broad-spectrum antibacterial therapy have an increased risk of developing an overt IFI and empiric antifungal therapy reduced the frequency of overt IFIs. Although all AmB formulations are efficacious, nephrotoxicity and infusion reactions occur and the risk varies by formulation, with the greatest risk with AmB deoxycholate and the least risk with liposomal AmB. Liposomal AmB and itraconazole were as efficacious as and less toxic than AmB deoxycholate, and caspofungin was as efficacious as liposomal AmB in randomized trials [580–582]. Although the other echinocandins have been less well studied for this indication, the committee regards all the echinocandins as therapeutically equivalent. A randomized trial of voriconazole vs liposomal AmB did not fulfill criteria for noninferiority for the overall population but was comparable to liposomal AmB in the high-risk neutropenic population, with a significant reduction in the rate of emergent IA [583].

Empiric antifungal therapy appears to be most beneficial in patients with prolonged neutropenia (duration of neutropenia >10 days) in contrast to low-risk neutropenic patients [584]. One randomized trial [585] compared antifungal therapy initiated at the onset of first neutropenic fever with that initiated after 96 hours of fever in leukemic and allogeneic HSCT patients; there was no difference in rates of IFI. The initiation of antifungal therapy is generally recommended for persistent unexplained fever after 4–7 days with a broad-spectrum antibiotic regimen. In one trial, initiation at 4 days was associated with a trend to higher response rates and shorter time to defervescence than initiation at 8 days [586]. The use of empiric antifungal therapy still warrants a comprehensive approach to establishing a microbiological diagnosis where feasible.

Persistent fever has poor specificity for the diagnosis of an IFI, and empiric antifungal therapy may thus expose patients where antifungal treatment is not indicated. The use of noninvasive diagnostics to detect incipient IFIs either in asymptomatic at-risk patients or in patients with unexplained neutropenic fever is sometimes known as preemptive or biomarker-driven antifungal therapy; the latter is a logical alternative to empiric antifungal therapy, in that it targets a high-risk subpopulation on the basis of a surrogate marker of infection, such as abnormal CT findings or a positive result for GM antigen, (1 → 3)- β -D-glucan, or *Aspergillus* PCR where available commercially or as a research tool. Biomarkers have been evaluated in 2 ways: serial screening of asymptomatic high-risk patients [96, 587, 588] and guiding targeted antifungal therapy for a subset of persistently febrile patients [589, 590]. Because approximately 40% of patients receiving empiric antifungal therapy have pulmonary infiltrates, there is considerable overlap between the approaches of empiric and biomarker-targeted therapy. In a feasibility study, Maertens et al used serum GM and chest CT

to detect IPA in patients with leukemia who received fluconazole prophylaxis [96]. This strategy reduced the use of empiric antifungal therapy and successfully treated cases of IPA, in which treatment often was initiated early, before onset of fever. Randomized trials have compared biomarker-driven strategies using serum GM [589, 590], *Aspergillus* PCR, or both [80] to trigger antifungal therapy vs symptom-driven empiric antifungal therapy in leukemia and HSCT. Different design issues such as the lack of standardization of antiyeast prophylaxis [80, 589], timing of biomarker screening (asymptomatic vs febrile patients), types of patients studied, duration of study, and inadequate sample size [588, 590] hamper generalizations. However, in general, these studies suggest that biomarker-driven strategies are associated with less unnecessary antifungal use without a compromise in overall survival. As would be expected by more intensive testing, more IFIs were generally seen, but without an increase in fungal-related mortality, presumably due to early initiation of antifungal therapy made possible by the intensive screening. One concern with the use of PCR assays for screening patients is the lack of commercial assays and technical challenges of different methodologies [591, 592]. Although some experts believe there is sufficient evidence to support the use of PCR assays [593], the committee does not recommend routine use of PCR assays outside the context of clinical trials or clinical research at this time. These various studies suggest that biomarker-driven antifungal therapy is an acceptable alternative to fever-driven empiric antifungal therapy in patients who are receiving antiyeast prophylaxis. Further study is needed to clarify which biomarker or combination of biomarkers is optimal, which risk group should be given antimold prophylaxis vs biomarker screening, and if routine screening in asymptomatic patients is preferable to screening only febrile patients. Data on biomarkers to guide preemptive therapy are limited for pediatric patients.

For persistently febrile neutropenic patients who may be receiving anti-*Aspergillus* prophylaxis, the causes of persistent fever are less likely to be of a fungal origin [594]. Careful evaluation for nonfungal causes, as well as the possibility of breakthrough IFIs that are resistant to the prophylactic regimen, should be considered in this patient population. Thus, routine initiation of empiric antifungal therapy in this context merits reevaluation.

Management of breakthrough IPA in the context of mold-active azole prophylaxis is not defined by clinical trial data. The approach to such patients should be individualized on the basis of clinical criteria, including host immunosuppression, underlying disease, and site of infection, as well as consideration of antifungal dosing, therapeutic monitoring of drug levels, a switch to intravenous therapy, and/or a switch to another drug class.

There are other high-risk patients, such as those with refractory leukemia, those with solid tumors, other SOT recipients, those receiving corticosteroid therapy, those with liver failure, those with COPD with progressive infiltrates despite antibiotics,

and critically ill patients in whom empiric therapy may be warranted on a case-by-case basis.

How Do Lung Transplant Recipients Differ From Other Immunosuppressed Patients in Management of Suspected Invasive Pulmonary Aspergillosis?

Recommendations.

79. In lung transplant recipients not on antimold prophylaxis, we suggest preemptive therapy with an antimold antifungal for asymptomatic patients with *Aspergillus* colonization of the airways within 6 months of lung transplant or within 3 months of receiving immunosuppression augmentation for rejection (*weak recommendation; moderate-quality evidence*).

80. Six months after lung transplant and in the absence of recent immunosuppression augmentation for rejection, it may be prudent to withhold antifungal therapy for *Aspergillus* airway colonization (ie, *Aspergillus* respiratory cultures in the absence of clinical features that suggest disease, such as compatible symptoms, or bronchoscopic, histopathologic, and/or radiographic findings) (*weak recommendation; low-quality evidence*).

Evidence Summary. Many lung transplant centers routinely perform scheduled bronchoscopies with transbronchial biopsies and BAL. These surveillance bronchoscopies allow inspection for airway complications, rejection monitoring, and detection of microbial colonization (bacteria, fungi, and/or viruses) before the onset of overt infection. Between 20% and 46% of lung transplant recipients are colonized in the airway with *Aspergillus* spp at some point after transplant [595, 596]. The risk of IA is increased 11-fold in patients with *Aspergillus* colonization of the airways, and mortality rates are high [595]. Furthermore, *Aspergillus*-colonized patients have an increased risk of chronic lung allograft dysfunction due to bronchiolitis obliterans and death [596, 597]. At present, it is not known whether asymptomatic patients with *Aspergillus* colonization should be treated with antifungal agents. Given the high rate of *Aspergillus* disease among colonized patients, we suggest a course of antifungal azole therapy within 6 months of transplant. Preemptive antifungal therapy based on culture has been successfully used in clearing *Aspergillus* from the airway [598–600]. In asymptomatic patients who are colonized with *Aspergillus* after 6 months, we suggest a thorough physical exam, to rule out signs of disseminated aspergillosis, and a chest CT. We also suggest a sinus CT for patients with signs or symptoms of sinus disease. If screening is negative, clinicians should consider factors such as immunosuppression augmentation for rejection within the previous 3–4 months (especially with alemtuzumab, thymoglobulin, or high-dose and prolonged duration of corticosteroids), the presence of recent CMV disease or uncontrolled CMV infection, and the presence of an airway stent or airway abnormalities at the time of positive culture. If physical findings or imaging abnormalities are suggestive of aspergillosis, or any

of the aforementioned factors are present, we suggest a course of 1–3 months of preemptive antifungal therapy and conversely, if negative, a watchful waiting approach without antifungal therapy.

CHRONIC AND SAPROPHYTIC SYNDROMES OF ASPERGILLUS

VII. How Should Chronic Aspergillosis, Allergic Syndromes, or Noninvasive Syndromes Be Managed?

How Can Chronic Cavitory Pulmonary Aspergillosis Be Diagnosed and Treated?

Recommendations.

81. The diagnosis of CCPA requires: (i) 3 months of chronic pulmonary symptoms or chronic illness or progressive radiologic radiographic abnormalities, with cavitation, pleural thickening, pericavitary infiltrates, and sometimes a fungal ball; (ii) *Aspergillus* IgG antibody elevated or other microbiological data; and (iii) no or minimal immunocompromise, usually with one or more underlying pulmonary disorders. The *Aspergillus* IgG antibody test is the most sensitive microbiological test (*strong recommendation; moderate-quality evidence*). Sputum *Aspergillus* PCR testing is more sensitive than culture (*weak recommendation; moderate-quality evidence*).

82. Patients with CCPA without pulmonary symptoms, weight loss, or significant fatigue, and those without major impairment of pulmonary function or gradual loss of pulmonary function may be observed without antifungal therapy and followed every 3–6 months (*weak recommendation; low-quality evidence*).

83. Patients with CCPA and either pulmonary or general symptoms or progressive loss of lung function or radiographic progression should be treated with a minimum of 6 months of antifungal therapy (*strong recommendation; low-quality evidence*).

84. Oral itraconazole and voriconazole are the preferred oral antifungal agents (*strong recommendation; high-quality evidence*); posaconazole is a useful third-line agent for those with adverse events or clinical failure (*strong recommendation; moderate-quality evidence*).

85. Hemoptysis may be managed with oral tranexamic acid (*weak recommendation; low-quality evidence*), bronchial artery embolization (*strong recommendation; moderate-quality evidence*), or antifungal therapy to prevent recurrence (*strong recommendation; low-quality evidence*). Patients failing these measures may require surgical resection (*weak recommendation; moderate-quality evidence*).

86. In those who fail therapy, develop triazole resistance, and/or have adverse events, intravenous micafungin (*weak recommendation; low-quality evidence*), caspofungin (*weak recommendation; low-quality evidence*), or AmB (*weak recommendation; low-quality evidence*) yield some responses. Treatment may need to be prolonged.

87. Surgical resection is an option for some patients with localized disease, unresponsive to medical therapy, including

those with pan-azole-resistant *Aspergillus fumigatus* infection or persistent hemoptysis despite bronchial artery embolization (*strong recommendation; moderate-quality evidence*). The outcomes from surgery are less favorable than those with single aspergilloma, and a careful risk assessment prior to surgical intervention is required.

88. In those with progressive disease, long-term, even lifelong antifungal therapy may be required to control disease (*weak recommendation; low-quality evidence*), with continual monitoring for toxicity and resistance.

Evidence Summary. Chronic cavitary pulmonary aspergillosis is defined as one or more pulmonary cavities that may or may not contain solid or liquid material or a fungal ball, with a positive *Aspergillus* IgG antibody test or microbiological evidence implicating *Aspergillus* spp with significant pulmonary or systemic symptoms and overt radiographic progression (new cavities, increasing pericavity infiltrates, or increasing pleural thickening) over at least 3 months [601, 602]. It is one manifestation of CPA [603, 604], single aspergilloma and *Aspergillus* nodule being others, and chronic fibrosing pulmonary aspergillosis (CFPA) an end-stage complication of CCPA [601].

CCPA complicates other pulmonary diseases, including tuberculosis, nontuberculous mycobacterial infection (both of which may occur concurrently, although are usually antecedent), fibrocystic sarcoidosis, ABPA, asthma, prior pneumonia, pneumothorax or lobectomy, COPD, ankylosing spondylitis and rheumatoid arthritis, hyper IgE syndrome, and congenital bullous disease [603]. Patients with mild or moderate immunosuppression may develop what was termed chronic necrotizing pulmonary aspergillosis, but is better considered subacute IPA [602, 605]. Patients with CCPA and CFPA have numerous underlying immunological defects, probably mostly genetic [606, 607]. As these defects and their pulmonary damage from prior disease are irreversible, long-term suppressive antifungal therapy is the default mode of treatment, although patients with mild cases may be able to stop therapy, and others may be forced to stop if medication intolerance or side effects develop.

Patients present with primarily pulmonary or general symptoms, or both. Response to therapy should be assessed against each person's symptom complex. Hemoptysis, shortness of breath, and productive cough are usual, whereas fever and chest pain are uncommon. Weight loss and fatigue are the most common general symptoms and may be profound [581]. Patients are often mistakenly thought to have tuberculosis.

If a fungal ball is present on chest imaging, the diagnosis is almost certainly CPA, either a single aspergilloma or CCPA. Confirmation is with *Aspergillus* IgG testing [608, 609], and the distinction between these 2 entities is made on the basis of symptomology and radiologic appearance. However, the majority of CCPA patients do not have a fungal ball but either multiple empty cavities, or cavities with an irregular (bumpy)

internal wall with associated pleural thickening, and pericavitary infiltrates. Mats of hyphae within the cavity become dislodged and eventually coalesce to form a fungal ball [610]. Diagnosis of CCPA is with *Aspergillus* IgG testing, excluding coccidioidomycosis, histoplasmosis, and paracoccidioidomycosis. Occasionally patients present with mycobacterial infection at the same time as CCPA. Rarely, a necrotizing lung cancer can be infected with *Aspergillus*, giving rise to a similar radiographic appearance. Multiple sputa (expectorated or induced) increase the probability of positive microscopy or fungal culture providing mycological support for the diagnosis. A majority of patients have negative sputum cultures; *Aspergillus* PCR is more sensitive [85]. If culture is positive and the patient has been receiving an azole, the isolate should be submitted for susceptibility testing. Hyphae may be seen on microscopy, and the culture is negative. Biopsy of the wall of a cavity in CCPA yields chronic inflammatory cells and fibrosis, sometimes with granulomata; hyphae consistent with *Aspergillus* spp are usually seen adjacent to the cavity wall, but are not truly invasive. Percutaneous aspiration of a cavity with a positive *Aspergillus* culture is an alternative means of establishing the diagnosis. More than 50% of patients have an increased total and *Aspergillus*-specific IgE titer; eosinophilia may be present [581].

The objectives of therapy of CCPA are to (1) improve symptoms; (2) reduce hemoptysis; (3) reduce progressive lung fibrosis, in particular preventing CFPA, which can occur rapidly; and (4) prolong survival. Oral therapy with itraconazole or voriconazole is a first-line therapy, depending on tolerance and affordability [602, 611–614]. Resistance to itraconazole during therapy has been reported more frequently than with voriconazole, so in patients with a large fungal load, voriconazole may be preferable, although clinical evidence to support this approach is lacking. Posaconazole is currently third-line therapy, because of the general lack of data and cost over long periods [615]. Treatment should be continued for a minimum of 6 months, and if well tolerated with a good response, may be continued for years [616]. Monitoring of therapy is critical and should be undertaken by physicians experienced with antifungal therapy. Toxicity may develop with long-term triazole therapy as previously discussed.

Occasional patients have a marked increase in shortness of breath shortly after starting antifungal therapy, which may respond to a short course of corticosteroids. Otherwise, all steroids should be avoided in CCPA, unless the patient is receiving adequate antifungal therapy and/or requires them for underlying disease, such as those with rheumatoid arthritis. Inhaled corticosteroids should be stopped in those with COPD and reduced in those with asthma, if possible.

Hemoptysis can usually be controlled with oral tranexamic acid [617, 618]. If hemoptysis is significant, bronchial artery embolization is recommended, and should be performed by an experienced interventional radiologist [619–622]. It may be necessary to embolize abnormal vessels arising from the

internal mammary, subclavian, and lateral thoracic arteries as well. Abnormal vessels arising close to the origin of both spinal and vertebral arteries should not be embolized. Recurrence of hemoptysis is common if antifungal therapy is not given and optimized, and may be a sign of antifungal failure.

Standard monitoring includes assessing radiographic change (every 3–12 months), preferably with low-dose CT without contrast or chest radiograph, inflammatory markers, *Aspergillus* IgG titers, and annual pulmonary function tests. Failure of therapy can be difficult to determine, but is based on a deteriorating clinical status, especially a new productive cough and/or weight loss, new or continuing hemoptysis, radiographic progression, or worsening respiratory function. Other causes of weight loss should be excluded, including celiac disease. Concurrent infection, including nontuberculous mycobacterial infection, is important to exclude, usually with multiple sputum cultures and occasionally bronchoscopy. Antifungal blood concentrations should be checked. Azole resistance should be sought.

On therapy, azole resistance may occur. Susceptibility testing of isolates obtained in patients on therapy may be extremely useful to guide therapeutic choices, and it is recommended that clinical laboratories not discard *A. fumigatus* isolates for 3 months, to allow clinicians to determine if patients are failing at their next outpatient appointment. Some isolates are only resistant to itraconazole or voriconazole, some to itraconazole and posaconazole, and others pan-azole resistant.

In patients who fail, are intolerant, or develop azole resistance or a combination of these circumstances, the clinician may need to resort to intravenous therapy. In addition, acutely ill patients may require an initial course of intravenous antifungal therapy. Both AmB deoxycholate and liposomal AmB and micafungin have been extensively used for CCPA, with modest response rates [193, 601, 623, 624]. In addition to its anti-*Aspergillus* activity, liposomal AmB has many TH₁ upregulating effects, which are generally deficient in patients with CPA, and may contribute to a clinical response. It is better tolerated than AmB deoxycholate, but both may result in treatment-limiting renal dysfunction. Micafungin has been examined in the treatment of CCPA and found to be effective [193]. There are few data for caspofungin and none for ABLC, ABCD, anidulafungin, or isavuconazole [625].

A common cause of death in CCPA, and possibly a trigger for additional lung fibrosis, is intercurrent bacterial infection. Common infections include *Streptococcus pneumoniae*, *Haemophilus influenzae*, and occasionally *Pseudomonas aeruginosa* and *Staphylococcus aureus*. Pneumococcal and *Haemophilus* immunization may reduce infections. Some CCPA patients have overt hypogammaglobulinemia. *Pseudomonas aeruginosa* eradication or control with high-dose oral ciprofloxacin, intravenous therapy, or inhaled colistin or tobramycin is also recommended for these patients. Minimizing bacterial infections allows simpler decision making if patients deteriorate on antifungal therapy.

Occasionally surgical resection is necessary for CCPA, typically for intractable hemoptysis, destroyed lung (CFPA) with poor quality of life, or azole resistance. Patients need to be fit enough (see section on simple aspergilloma for considerations, recommendations 89–91 below). A conventional lobectomy [626–629], video-assisted thoracic surgical procedure [630–632], or cavernostomy with space reduction using a limited thoracoplasty may be required. The outcomes from surgery are acceptable, but both the risk of death and complications such as pleural space infection is higher in CCPA than for single aspergilloma. Relapse rates up to 25% are documented [633], which makes decision making difficult, especially in the knowledge that subtle immune deficits will persist after surgery. All CCPA patients undergoing resection surgery require active follow-up.

What Are the Management Options for an *Aspergillus* Fungal Ball of the Lung (*Aspergilloma*)?

Recommendations.

89. Asymptomatic patients with a single aspergilloma and no progression of the cavity size over 6–24 months should continue to be observed (*strong recommendation; moderate-quality evidence*).
90. Patients with symptoms, especially significant hemoptysis, with a single aspergilloma, should have it resected, assuming that there are no contraindications (*strong recommendation; moderate-quality evidence*).
91. Peri-/postoperative antifungal therapy is not routinely required, but if the risk of surgical spillage of the aspergilloma is moderate (related to location and morphology of the cavity), antifungal therapy with voriconazole (or another mold-active azole) or an echinocandin is suggested to prevent *Aspergillus* empyema (*weak recommendation; low-quality evidence*).

Evidence Summary. Single aspergilloma, previously often referred to as simple aspergilloma, may occur with CPA so that the evidence supporting management of a fungal ball due to *Aspergillus* should be considered in the context of CPA in that situation. These patients may be asymptomatic, present with hemoptysis, shortness of breath, or cough. “Single uncomplicated aspergilloma” is defined as a single pulmonary cavity containing a fungal ball in a nonimmunocompromised patient with microbiological or serological evidence of *Aspergillus* spp with minimal or no symptoms and no radiographic progression over at least 3 months [603]. An aspergilloma is described radiographically as an approximately spherical shadow with surrounding air, also called a fungal ball, in a pulmonary cavity, with evidence that *Aspergillus* spp is present in the material. *Aspergillus fumigatus* is the usual cause. Fungal balls of the lung may rarely be caused by other fungi, such as *A. flavus*, or other molds like *Scedosporium* spp. Single aspergilloma represents a manifestation of CPA with a favorable prognosis, and is usually not rapidly progressive so that management decisions are not usually acute, unless severe hemoptysis has occurred.

The optimal management of a single aspergilloma is surgical resection, either by conventional lobectomy [626–629] or a video-assisted thoracic surgical procedure [630–632]. However, surgical planning requires the following considerations [633]: Respiratory reserve should be adequate, as based on FEV₁ and especially exercise tolerance; patients who are taking antithrombotic medication should be able to have their medication suspended for at least 4 days, and preferably longer; and preoperative bronchial artery embolization allows more time for surgical assessment and planning, but has little impact on postoperative bleeding [634].

An evaluation of risk of spillage at surgery needs to be made based on the difficulty of separating the cavity containing the fungal ball from the chest wall [633]. Extrapleural dissection over the apex may be required but may be followed by bleeding from collateral arterial vessels crossing the pleura from the chest wall. If it is likely or possible that the cavity will be opened during the surgical procedure, leading to pleural contamination, then antifungal therapy with voriconazole (or another mold-active azole) or micafungin (or another echinocandin) should be given, starting preoperatively with voriconazole or perioperatively for micafungin. Use of voriconazole may alter the preferred anesthetic approach, as prolongation of benzodiazepine sedation is problematic with voriconazole. If no spillage occurs during surgery, antifungal therapy can be stopped. If spillage does occur, some clinicians advise washing out the pleural space with AmB or antifungal topical disinfectant such as tauroloidine 2%, although evidence to support either approach is minimal. Antifungal therapy should be continued postoperatively and an infectious diseases physician involved in care to monitor therapy and determine the length of treatment. If there is no evidence of infection following spillage during surgery, a minimum of 4 weeks of therapy is typically recommended.

Patients with 2 separate aspergillomas [635] may be considered for bilobar resections or pneumonectomy depending on locations and their respiratory reserve. If respiratory reserve does not allow resection, then medical therapy alone can be offered to minimize recurrent hemoptysis.

Relapse following resection does occur; 25% of patients in one CPA series had relapse of infection including some aspergilloma cases [633]. Most surgical series do not provide long-term follow-up. For patients with spillage, active follow-up (typically at 4- to 6-month intervals) assessing radiographic change, inflammatory markers, and *Aspergillus* IgG titers for 3 years is advised. If spillage has not occurred, then active follow-up is not advised, unless there is ongoing active pulmonary disease.

ALLERGIC SYNDROMES OF ASPERGILLUS

How Is Allergic Bronchopulmonary Aspergillosis Identified and Managed in Patients With Asthma and Cystic Fibrosis?

Recommendations.

92. Elevated *Aspergillus* IgE and total IgE are recommended to establish the diagnosis and are useful for screening (*strong recommendation; high-quality evidence*).

93. We suggest treating symptomatic asthmatic patients with bronchiectasis or mucoid impaction, despite oral or inhaled corticosteroid therapy, with oral itraconazole therapy with TDM (*weak recommendation; low-quality evidence*).

94. In CF patients with frequent exacerbations and/or falling FEV₁, we suggest treating with oral itraconazole to minimize corticosteroid use with TDM, and consideration of other mold-active azole therapy if therapeutic levels cannot be achieved (*weak recommendation; low-quality evidence*).

Evidence Summary. ABPA complicates asthma and CF [83, 509, 636, 637]. In asthmatic patients it presents as poorly controlled asthma, “pneumonia” that represents mucoid impaction, persistent eosinophilia, and bronchiectasis or with CPA and lung fibrosis, the latter both late complications. Some patients are asymptomatic. In CF, it tends to present with difficult-to-control exacerbations, responsive to corticosteroids, although mucoid impaction is described.

The key criterion for diagnosis is an elevated *Aspergillus*-specific IgE, supported by an elevated total IgE, detectable *Aspergillus*-specific IgG, eosinophilia, and positive skin prick tests for *Aspergillus* (where available) [83, 637, 638]. Uncommonly, other fungi can produce a similar clinical picture. Patients with severe asthma, not fulfilling the criteria for ABPA, may have severe asthma with fungal sensitization, also responsive to antifungal therapy [636, 639]. There are some areas of overlap with these syndromes, and some experts consider all patients with these diagnoses under the term “fungal asthma.”

Screening for ABPA in patients with asthma and CF, probably on an annual basis, is recommended, particularly if patients are symptomatic with frequent asthma exacerbations. Asthmatics admitted to hospital, including intensive care, should be evaluated for fungal asthma [640].

The optimal management of ABPA in both asthma and CF depends on patient response, severity of disease and exacerbation frequency, drug adverse effects, and the emergence of antifungal resistance [637, 639, 641]. Treatment involves a 2-pronged approach: controlling the immune response (which is what makes the patient symptomatic), and decreasing the burden of organisms so that there is less of an immune response.

Oral corticosteroids reduce the inflammatory response in acute exacerbations of ABPA, but are associated with many adverse effects, some short-term, others long-term, such as diabetes in CF. Relapse is frequent after discontinuation. Inhaled corticosteroids control asthma in some patients. Anti-IgE (omalizumab) therapy might be helpful, but data are scant [642]. Cough and sputum production may be reduced by azithromycin or antifungal therapy or both. Nebulized hypertonic saline helps some patients clear sputum [643]. Prevention of exacerbations may be affected by pneumococcal and/or *Haemophilus* vaccination. Avoidance of substantial fungal exposures, as in composting, farming, and house renovation may also prevent exacerbations.

Antifungal therapy is helpful for many patients [639, 641, 644, 645]. Itraconazole is currently the first-line agent for symptomatic patients, CF patients with low FEV₁, or those with complications such as bronchiectasis, mucoid impaction, or CPA. Itraconazole solution is preferred in CF patients because of poor absorption of capsules. Patients who fail itraconazole, or are intolerant to itraconazole, may respond to voriconazole, posaconazole, or inhaled AmB [646]. Relapse after improvement during antifungal therapy is common; long-term suppressive therapy may be necessary. Interactions of itraconazole with some inhaled corticosteroids can precipitate Cushing's syndrome, so that reduction in inhaled steroid dose or a switch to ciclesonide may be useful for those patients. Triazole antifungal resistance has been documented in some geographic regions, so susceptibility testing may be valuable in areas where epidemiologic data indicate environmental resistance or isolates are cultured from patients on antifungal therapy.

What Is the Medical Management of Allergic Fungal Rhinosinusitis Caused by *Aspergillus* Species?

Recommendations.

95. We recommend establishing the diagnosis of AFRS in patients with nasal polyposis and thick eosinophilic mucin by visualizing hyphae in mucus, which is supported by a positive *Aspergillus* IgE serum assay or skin-prick test (where available) (*strong recommendation; moderate-quality evidence*).
96. We recommend polypectomy and sinus washout as the optimal means of symptom control and inducing remission; however, relapse is frequent (*strong recommendation; moderate-quality evidence*).
97. We recommend the use of topical nasal steroids to reduce symptoms and increase time to relapse, especially if given after surgery (*strong recommendation; moderate-quality evidence*).
98. We suggest oral antifungal therapy using mold-active triazoles for refractory infection and/or rapidly relapsing disease, although this approach is only partially effective (*weak recommendation; low-quality evidence*).

Evidence Summary. AFRS is a small subset (<10%) of chronic rhinosinusitis occurring in adults and children [647]. AFRS is characterized by eosinophilic mucin and fungal hyphae in the paranasal sinuses, often associated with immediate hypersensitivity to various fungi. Fungal culture of nasal secretions is usually unhelpful as it reflects airborne fungi, so clarity about the specific fungus involved is usually inferential or unclear. The disease is commonly associated with nasal polyposis, and sometimes with ABPA [648]. Local complications of AFRS include ophthalmic involvement with oculomotor palsy, bony erosion, and cavernous venous thrombosis [649]. The disease course is long, with many patients having extended periods of remission with exacerbations often following viral and/or

bacterial infections. Short courses of modest doses of oral corticosteroids may shrink polyps and allow drainage, but relapse is common, and not usually prevented by topical steroids. Surgical removal of polyps and mucus is the most important aspect of management, with postoperative systemic or topical nasal steroids recommended to reduce the time to relapse [650, 651]. Saline washes are often helpful. Omalizumab has been reported to be helpful in studies of severe asthma with associated chronic rhinitis [652]. Oral antifungal therapy for AFRS, usually itraconazole, is helpful for refractory disease and to prevent relapse in patients with frequent recurrences [653–655].

FUTURE DIRECTIONS

There are many unanswered and unresolved epidemiological, laboratory, and clinical questions that need to be addressed and understood in the diagnosis, treatment, and prevention of aspergillosis. Better diagnostic tests and improved understanding of the optimal use of current methods are needed both to facilitate more accurate identification of patients with IA and to permit earlier initiation of therapy. The availability of more active and better tolerated antifungal agents has significantly improved therapy of patients at risk for serious *Aspergillus* infections, but even with optimal antifungal therapy the mortality rate remains high; therefore, further development of new antifungal agents is greatly needed. Critical gaps in knowledge remain regarding management of these infections including the optimal utility of combination therapy, tools for early detection of these infections, evaluation of response, therapy for patients with breakthrough or refractory infection, and the population of patients for whom prophylaxis would be most beneficial.

Notes

Dedication. The panel dedicates these guidelines to the memory of our dear friend Susan Hadley, MD, a core member of the Mycoses Study Group, caring physician, and wonderful colleague.

Acknowledgments. The Expert Panel expresses its gratitude for thoughtful reviews of an earlier version by Sanjay Revankar and Samuel Lee. The Panel also greatly appreciates the work of Charles B. Wessels and Michele Klein Fedyshin of the Health Sciences Library System of the University of Pittsburgh for the development and execution of the systematic literature searches for this guideline. We give special thanks to Genet Demisashi of the Infectious Diseases Society of America (IDSA) staff for her support in the development of this guideline.

Financial support. Support for this guideline was provided by the IDSA.

Potential conflicts of interest. The following list is a reflection of what has been reported to IDSA. To provide thorough transparency, IDSA requires full disclosure of all relationships, regardless of relevancy to the guideline topic. Evaluation of such relationships as potential conflicts of interest (COI) is determined by a review process that includes assessment by the Standards and Practice Guideline Committee (SPGC) Chair, the SPGC liaison to the development panel, the Board of Directors liaison to the SPGC, and, if necessary, the COI Task Force of the Board. This assessment of disclosed relationships for possible COI will be based on the relative weight of the financial relationship (ie, monetary amount) and the relevance of the relationship (ie, the degree to which an association might reasonably be interpreted by an independent observer as related to the topic or

recommendation of consideration). The reader of these guidelines should be mindful of this when the list of disclosures is reviewed. For activities outside the submitted work, T. F. P. received research grant support to the University of Texas Health Science Center San Antonio from Astellas, Merck, and Revolution Medicines and has been a consultant for or served on advisory boards to Amplyx, Astellas, Durata, Cidara Therapeutics, Gilead, Merck, Pfizer, Revolution Medicines, Scynexis, Toyama, Vical, and Viamet. For activities outside of the submitted work, G. R. T. received research support to the University of California, Davis from Astellas, Merck, Pfizer, and Scynexis, and has been a consultant for Astellas. For activities outside the submitted work, D. W. D. holds Founder shares in F2G Ltd, a University of Manchester spin-out antifungal discovery company and in Novocyt, which markets the Myconostica real-time molecular assays; has current grant support from the National Institute of Health Research, Medical Research Council, Global Action Fund for Fungal Infections, and the Fungal Infection Trust; serves as a consultant to Astellas, Sigma Tau, Basilea, and Pulmocide; and has received honoraria from Astellas, Dynamiker, Gilead, Merck, and Pfizer. For activities outside the submitted work, J. A. F. served on scientific advisory boards for Revolution Medicines. For activities outside the submitted work, S. H. served as a consultant to Merck. For activities outside the submitted work, R. H. served on advisory boards for Astellas, Basilea, Gilead, and Pfizer and received research grants from Alsace contre le Cancer and Pfizer. For activities outside the submitted work, D. P. K. served as a consultant to Astellas, Merck, and Pfizer; received research support from Astellas, Merck, Pfizer, and T2 Biosystems; and received honoraria from Astellas, Merck, Pfizer, T2 Biosystems, Gilead, and F2G, Inc. For activities outside the submitted work, K. A. M. received honoraria from Amplyx, Astellas, Cidara, F2G, Merck, Pfizer, Revolutions Medicine, and Vical, and has a patent US No. 13/511 264 licensed. For activities outside the submitted work, V. A. M. served as a consultant for Celgene, Amgen, GSK, Merck, and Astellas, and served on the speaker's bureaus for Genentech and Celgene. For activities outside the submitted work, M. H. N. received research grants from Astellas, Pfizer, Merck, ViraCor, and the National Institutes of Health (National Institute of Allergy and Infectious Diseases). For activities outside the submitted work, B. H. S. served on advisory boards for Merck and Astellas, and has contracts for laboratory research from Astellas and Assembly Biosciences. For activities outside the submitted work, W. J. S. served on scientific advisory boards from Merck and received research grants to Duke University from Merck and Astellas. For activities outside the submitted work, T. J. W. served as a consultant or scientific advisor for Astellas, Novartis, Pfizer, and Methygene and received research grants to Weill Cornell Medical Center from Astellas, Merck, and Novartis. For activities outside the submitted work, J. R. W. served as consultant/scientific advisor for Gilead, Astellas, Pfizer, Merck, and Vical. For activities outside the submitted work, J. H. Y. received research support to the University of Minnesota from Astellas, Merck, and Pfizer. All other authors report no potential conflicts. All authors have submitted the ICMJE Form for Disclosure of Potential Conflicts of Interest. Conflicts that the editors consider relevant to the content of the manuscript have been disclosed.

References

- Walsh TJ, Anaissie EJ, Denning DW, et al. Treatment of aspergillosis: clinical practice guidelines of the Infectious Diseases Society of America. *Clin Infect Dis* 2008; 46:327–60.
- Guyatt GH, Oxman AD, Vist GE, et al. GRADE: an emerging consensus on rating quality of evidence and strength of recommendations. *BMJ* 2008; 336:924–6.
- Guyatt GH, Oxman AD, Schunemann HJ, Tugwell P, Knottnerus A. GRADE guidelines: a new series of articles in the Journal of Clinical Epidemiology. *J Clin Epidemiol* 2011; 64:380–2.
- US GRADE Network. Approach and implications to rating the quality of evidence and strength of recommendations using the GRADE methodology. Available at: <http://www.gradeworkinggroup.org/>. Accessed 1 April 2016.
- Panackal AA, Li H, Kontoyiannis DP, et al. Geoclimatic influences on invasive aspergillosis after hematopoietic stem cell transplantation. *Clin Infect Dis* 2010; 50:1588–97.
- Oliver MR, Van Voorhis WC, Boeckh M, Mattson D, Bowden RA. Hepatic mucormycosis in a bone marrow transplant recipient who ingested naturopathic medicine. *Clin Infect Dis* 1996; 22:521–4.
- Thompson GR 3rd, Tuscano JM. Adverse health effects of marijuana use. *N Engl J Med* 2014; 371:878–9.
- Papouli M, Roilides E, Bibashi E, Andreou A. Primary cutaneous aspergillosis in neonates: case report and review. *Clin Infect Dis* 1996; 22:1102–4.
- van Burik JA, Colven R, Spach DH. Cutaneous aspergillosis. *J Clin Microbiol* 1998; 36:3115–21.
- Etienne KA, Subudhi CP, Chadwick PR, et al. Investigation of a cluster of cutaneous aspergillosis in a neonatal intensive care unit. *J Hosp Infect* 2011; 79:344–8.
- Bryce EA, Walker M, Scharf S, et al. An outbreak of cutaneous aspergillosis in a tertiary-care hospital. *Infect Control Hosp Epidemiol* 1996; 17:170–2.
- Anaissie EJ, Stratton SL, Dignani MC, et al. Cleaning patient shower facilities: a novel approach to reducing patient exposure to aerosolized *Aspergillus* species and other opportunistic molds. *Clin Infect Dis* 2002; 35:E86–8.
- Anaissie EJ, Stratton SL, Dignani MC, et al. Pathogenic *Aspergillus* species recovered from a hospital water system: a 3-year prospective study. *Clin Infect Dis* 2002; 34:780–9.
- Anaissie EJ, Stratton SL, Dignani MC, et al. Pathogenic molds (including *Aspergillus* species) in hospital water distribution systems: a 3-year prospective study and clinical implications for patients with hematologic malignancies. *Blood* 2003; 101:2542–6.
- Anaissie EJ, Kuchar RT, Rex JH, et al. Fusariosis associated with pathogenic fusarium species colonization of a hospital water system: a new paradigm for the epidemiology of opportunistic mold infections. *Clin Infect Dis* 2001; 33:1871–8.
- Mesquita-Rocha S, Godoy-Martinez PC, Goncalves SS, et al. The water supply system as a potential source of fungal infection in paediatric haematopoietic stem cell units. *BMC Infect Dis* 2013; 13:289.
- Warris A, Klaassen CH, Meis JF, et al. Molecular epidemiology of *Aspergillus fumigatus* isolates recovered from water, air, and patients shows two clusters of genetically distinct strains. *J Clin Microbiol* 2003; 41:4101–6.
- Tomblyn M, Chiller T, Einsele H, et al. Guidelines for preventing infectious complications among hematopoietic cell transplantation recipients: a global perspective. *Biol Blood Marrow Transplant* 2009; 15:1143–238.
- Partridge-Hinckley K, Liddell GM, Almyroudis NG, Segal BH. Infection control measures to prevent invasive mould diseases in hematopoietic stem cell transplant recipients. *Mycopathologia* 2009; 168:329–37.
- Thio CL, Smith D, Merz WG, et al. Refinements of environmental assessment during an outbreak investigation of invasive aspergillosis in a leukemia and bone marrow transplant unit. *Infect Control Hosp Epidemiol* 2000; 21:18–23.
- Hahn T, Cummings KM, Michalek AM, Lipman BJ, Segal BH, McCarthy PL Jr. Efficacy of high-efficiency particulate air filtration in preventing aspergillosis in immunocompromised patients with hematologic malignancies. *Infect Control Hosp Epidemiol* 2002; 23:525–31.
- Raviv Y, Kramer MR, Amital A, Rubinovitch B, Bishara J, Shitrit D. Outbreak of aspergillosis infections among lung transplant recipients. *Transpl Int* 2007; 20:135–40.
- Pelaez T, Munoz P, Guinea J, et al. Outbreak of invasive aspergillosis after major heart surgery caused by spores in the air of the intensive care unit. *Clin Infect Dis* 2012; 54:e24–31.
- Yokoe D, Casper C, Dubberke E, et al. Infection prevention and control in health-care facilities in which hematopoietic cell transplant recipients are treated. *Bone Marrow Transplant* 2009; 44:495–507.
- van der Linden JW, Camps SM, Kampinga GA, et al. Aspergillosis due to voriconazole highly resistant *Aspergillus fumigatus* and recovery of genetically related resistant isolates from domiciles. *Clin Infect Dis* 2013; 57:513–20.
- Gangneux JP, Bretagne S, Cordonnier C, et al. Prevention of nosocomial fungal infection: the French approach. *Clin Infect Dis* 2002; 35:343–6.
- Hajjeh RA, Warnock DW. Counterpoint: invasive aspergillosis and the environment—rethinking our approach to prevention. *Clin Infect Dis* 2001; 33:1549–52.
- Weinberger M, Elattar I, Marshall D, et al. Patterns of infection in patients with aplastic anemia and the emergence of *Aspergillus* as a major cause of death. *Medicine (Baltimore)* 1992; 71:24–43.
- Gerson SL, Talbot GH, Hurwitz S, Strom BL, Lusk EJ, Cassileth PA. Prolonged granulocytopenia: the major risk factor for invasive pulmonary aspergillosis in patients with acute leukemia. *Ann Intern Med* 1984; 100:345–51.
- Kontoyiannis DP, Marr KA, Park BJ, et al. Prospective surveillance for invasive fungal infections in hematopoietic stem cell transplant recipients, 2001–2006: overview of the Transplant-Associated Infection Surveillance Network (TRANS-NET) Database. *Clin Infect Dis* 2010; 50:1091–100.
- Jantunen E, Ruutu P, Niskanen L, et al. Incidence and risk factors for invasive fungal infections in allogeneic BMT recipients. *Bone Marrow Transplant* 1997; 19:801–8.
- Marr KA, Carter RA, Boeckh M, Martin P, Corey L. Invasive aspergillosis in allogeneic stem cell transplant recipients: changes in epidemiology and risk factors. *Blood* 2002; 100:4358–66.

33. van Burik JA, Carter SL, Freifeld AG, et al. Higher risk of cytomegalovirus and aspergillus infections in recipients of T cell-depleted unrelated bone marrow: analysis of infectious complications in patients treated with T cell depletion versus immunosuppressive therapy to prevent graft-versus-host disease. *Biol Blood Marrow Transplant* **2007**; 13:1487–98.
34. Bochud PY, Chien JW, Marr KA, et al. Toll-like receptor 4 polymorphisms and aspergillus in stem-cell transplantation. *N Engl J Med* **2008**; 359:1766–77.
35. Zaas AK, Liao G, Chien JW, et al. Plasminogen alleles influence susceptibility to invasive aspergillus. *PLoS Genet* **2008**; 4:e1000101.
36. Cunha C, Aversa F, Lacerda JF, et al. Genetic PTX3 deficiency and aspergillus in stem-cell transplantation. *N Engl J Med* **2014**; 370:421–32.
37. Cunha C, Di Ianni M, Bozza S, et al. Dectin-1 Y238X polymorphism associates with susceptibility to invasive aspergillus in hematopoietic transplantation through impairment of both recipient- and donor-dependent mechanisms of antifungal immunity. *Blood* **2010**; 116:5394–402.
38. Wojtowicz A, Lecompte TD, Bibert S, et al. PTX3 polymorphisms and invasive mold infections after solid organ transplant. *Clin Infect Dis* **2015**; 61:619–22.
39. Wojtowicz A, Gresnigt MS, Lecompte T, et al. IL1B and DEFB1 polymorphisms increase susceptibility to invasive mold infection after solid-organ transplantation. *J Infect Dis* **2015**; 211:1646–57.
40. Pappas PG, Alexander BD, Andes DR, et al. Invasive fungal infections among organ transplant recipients: results of the Transplant-Associated Infection Surveillance Network (TRANSNET). *Clin Infect Dis* **2010**; 50:1101–11.
41. Doligalski CT, Benedict K, Cleveland AA, et al. Epidemiology of invasive mold infections in lung transplant recipients. *Am J Transplant* **2014**; 14:1328–33.
42. Neofytos D, Fishman JA, Horn D, et al. Epidemiology and outcome of invasive fungal infections in solid organ transplant recipients. *Transpl Infect Dis* **2010**; 12:220–9.
43. Singh N, Husain S; AST Infectious Diseases Community of Practice. Aspergillus in solid organ transplantation. *Am J Transplant* **2013**; 13(suppl 4):228–41.
44. Luong ML, Chaparro C, Stephenson A, et al. Pretransplant *Aspergillus* colonization of cystic fibrosis patients and the incidence of post-lung transplant invasive aspergillus. *Transplantation* **2014**; 97:351–7.
45. Su T, Li HC, Chen M, et al. Invasive pulmonary aspergillus in patients with antineutrophil cytoplasmic antibody associated vasculitis. *J Clin Rheumatol* **2009**; 15:380–2.
46. Mylonakis E, Barlam TF, Flanigan T, Rich JD. Pulmonary aspergillus and invasive disease in AIDS: review of 342 cases. *Chest* **1998**; 114:251–62.
47. Wallace JM, Lim R, Browdy BL, et al. Risk factors and outcomes associated with identification of *Aspergillus* in respiratory specimens from persons with HIV disease. Pulmonary Complications of HIV Infection Study Group. *Chest* **1998**; 114:131–7.
48. van den Berg JM, van Koppen E, Ahlin A, et al. Chronic granulomatous disease: the European experience. *PLoS One* **2009**; 4:e5234.
49. Winkelstein JA, Marino MC, Johnston RB Jr, et al. Chronic granulomatous disease. Report on a national registry of 368 patients. *Medicine (Baltimore)* **2000**; 79:155–69.
50. Segal BH, DeCarlo ES, Kwon-Chung KJ, Malech HL, Gallin JI, Holland SM. *Aspergillus nidulans* infection in chronic granulomatous disease. *Medicine (Baltimore)* **1998**; 77:345–54.
51. Segal BH, Barnhart LA, Anderson VL, Walsh TJ, Malech HL, Holland SM. Posaconazole as salvage therapy in patients with chronic granulomatous disease with invasive filamentous fungal infection. *Clin Infect Dis* **2005**; 40:1684–8.
52. Skoetz N, Bauer K, Elter T, et al. Alemtuzumab for patients with chronic lymphocytic leukaemia. *Cochrane Database Syst Rev* **2012**; 2:CD008078.
53. Lundin J, Hagberg H, Repp R, et al. Phase 2 study of alemtuzumab (anti-CD52 monoclonal antibody) in patients with advanced mycosis fungoides/Sezary syndrome. *Blood* **2003**; 101:4267–72.
54. Gallamini A, Zaja F, Patti C, et al. Alemtuzumab (Campath-1H) and CHOP chemotherapy as first-line treatment of peripheral T-cell lymphoma: results of a GITIL (Gruppo Italiano Terapie Innovative nei Linfomi) prospective multicenter trial. *Blood* **2007**; 110:2316–23.
55. Bongartz T, Sutton AJ, Sweeting MJ, Buchan I, Matteson EL, Montori V. Anti-TNF antibody therapy in rheumatoid arthritis and the risk of serious infections and malignancies: systematic review and meta-analysis of rare harmful effects in randomized controlled trials. *JAMA* **2006**; 295:2275–85.
56. Baddley JW, Winthrop KL, Chen L, et al. Non-viral opportunistic infections in new users of tumour necrosis factor inhibitor therapy: results of the SAFETY Assessment of Biologic ThERapy (SABER) Study. *Ann Rheum Dis* **2014**; 73:1942–8.
57. Marty FM, Lee SJ, Fahey MM, et al. Infliximab use in patients with severe graft-versus-host disease and other emerging risk factors of non-*Candida* invasive fungal infections in allogeneic hematopoietic stem cell transplant recipients: a cohort study. *Blood* **2003**; 102:2768–76.
58. Meersseman W, Vandecasteele SJ, Wilmer A, Verbeken E, Peetermans WE, Van Wijngaerden E. Invasive aspergillus in critically ill patients without malignancy. *Am J Respir Crit Care Med* **2004**; 170:621–5.
59. Blot SI, Taccone FS, Van den Abele AM, et al. A clinical algorithm to diagnose invasive pulmonary aspergillus in critically ill patients. *Am J Respir Crit Care Med* **2012**; 186:56–64.
60. Meersseman W, Lagrou K, Maertens J, et al. Galactomannan in bronchoalveolar lavage fluid: a tool for diagnosing aspergillus in intensive care unit patients. *Am J Respir Crit Care Med* **2008**; 177:27–34.
61. Wauters J, Baar I, Meersseman P, et al. Invasive pulmonary aspergillus is a frequent complication of critically ill H1N1 patients: a retrospective study. *Intensive Care Med* **2012**; 38:1761–8.
62. Lat A, Bhadelia N, Miko B, Furuya EY, Thompson GR 3rd. Invasive aspergillus after pandemic (H1N1) 2009. *Emerg Infect Dis* **2010**; 16:971–3.
63. Baddley JW, Stephens JM, Ji X, Gao X, Schlamm HT, Tarallo M. Aspergillus in intensive care unit (ICU) patients: epidemiology and economic outcomes. *BMC Infect Dis* **2013**; 13:29.
64. De Pauw B, Walsh TJ, Donnelly JP, et al. Revised definitions of invasive fungal disease from the European Organization for Research and Treatment of Cancer/Invasive Fungal Infections Cooperative Group and the National Institute of Allergy and Infectious Diseases Mycoses Study Group (EORTC/MSG) Consensus Group. *Clin Infect Dis* **2008**; 46:1813–21.
65. Sangoi AR, Rogers WM, Longacre TA, Montoya JG, Baron EJ, Banaei N. Challenges and pitfalls of morphologic identification of fungal infections in histologic and cytologic specimens: a ten-year retrospective review at a single institution. *Am J Clin Pathol* **2009**; 131:364–75.
66. Shah AA, Hazen KC. Diagnostic accuracy of histopathologic and cytopathologic examination of *Aspergillus* species. *Am J Clin Pathol* **2013**; 139:55–61.
67. Tarrand JJ, Lichterfeld M, Warraich I, et al. Diagnosis of invasive septate mold infections. A correlation of microbiological culture and histologic or cytologic examination. *Am J Clin Pathol* **2003**; 119:854–8.
68. Guarner J, Brandt ME. Histopathologic diagnosis of fungal infections in the 21st century. *Clin Microbiol Rev* **2011**; 24:247–80.
69. Vyzantiadis TA, Johnson EM, Kibbler CC. From the patient to the clinical mycology laboratory: how can we optimise microscopy and culture methods for mould identification? *J Clin Pathol* **2012**; 65:475–83.
70. Hope WW, Walsh TJ, Denning DW. Laboratory diagnosis of invasive aspergillus. *Lancet Infect Dis* **2005**; 5:609–22.
71. Denning DW, Kibbler CC, Barnes RA; British Society for Medical Mycology. British Society for Medical Mycology proposed standards of care for patients with invasive fungal infections. *Lancet Infect Dis* **2003**; 3:230–40.
72. Barton RC. Laboratory diagnosis of invasive aspergillus: from diagnosis to prediction of outcome. *Scientifica* **2013**; 2013:459405.
73. Labarca JA, Wagar EA, Grasmick AE, Kokkinos HM, Bruckner DA. Critical evaluation of 4-week incubation for fungal cultures: is the fourth week useful? *J Clin Microbiol* **1998**; 36:3683–5.
74. Andreas S, Heindl S, Wattky C, Moller K, Ruchel R. Diagnosis of pulmonary aspergillus using optical brighteners. *Eur Respir J* **2000**; 15:407–11.
75. Chander J, Chakrabarti A, Sharma A, Saini JS, Panigarhi D. Evaluation of Calcofluor staining in the diagnosis of fungal corneal ulcer. *Mycoses* **1993**; 36:243–5.
76. Mortensen KL, Johansen HK, Fuursted K, et al. A prospective survey of *Aspergillus* spp. in respiratory tract samples: prevalence, clinical impact and antifungal susceptibility. *Eur J Clin Microbiol Infect Dis* **2011**; 30:1355–63.
77. Arvanitis M, Ziakas PD, Zacharioudakis IM, Zervou FN, Caliendo AM, Mylonakis E. PCR in diagnosis of invasive aspergillus: a meta-analysis of diagnostic performance. *J Clin Microbiol* **2014**; 52:3731–42.
78. Avni T, Levy I, Sprecher H, Yahav D, Leibovici L, Paul M. Diagnostic accuracy of PCR alone compared to galactomannan in bronchoalveolar lavage fluid for diagnosis of invasive pulmonary aspergillus: a systematic review. *J Clin Microbiol* **2012**; 50:3652–8.
79. Heng SC, Morrissey O, Chen SC, et al. Utility of bronchoalveolar lavage fluid galactomannan alone or in combination with PCR for the diagnosis of invasive aspergillus in adult hematology patients: a systematic review and meta-analysis. *Crit Rev Microbiol* **2015**; 41:124–34.
80. Morrissey CO, Chen SC, Sorrell TC, et al. Galactomannan and PCR versus culture and histology for directing use of antifungal treatment for invasive aspergillus in high-risk haematology patients: a randomised controlled trial. *Lancet Infect Dis* **2013**; 13:519–28.
81. Aguado JM, Vazquez L, Fernandez-Ruiz M, et al. Serum galactomannan versus a combination of galactomannan and polymerase chain reaction-based *Aspergillus* DNA detection for early therapy of invasive aspergillus in high-risk hematological patients: a randomized controlled trial. *Clin Infect Dis* **2015**; 60:405–14.

82. Fraczek MG, Kirwan MB, Moore CB, Morris J, Denning DW, Richardson MD. Volume dependency for culture of fungi from respiratory secretions and increased sensitivity of *Aspergillus* quantitative PCR. *Mycoses* **2014**; 57:69–78.
83. Baxter CG, Dunn G, Jones AM, et al. Novel immunologic classification of aspergillosis in adult cystic fibrosis. *J Allergy Clin Immunol* **2013**; 132:560–6. e10.
84. Baxter CG, Rautemaa R, Jones AM, et al. Intravenous antibiotics reduce the presence of *Aspergillus* in adult cystic fibrosis sputum. *Thorax* **2013**; 68:652–7.
85. Denning DW, Park S, Lass-Flörl C, et al. High-frequency triazole resistance found in nonculturable *Aspergillus fumigatus* from lungs of patients with chronic fungal disease. *Clin Infect Dis* **2011**; 52:1123–9.
86. Baxter CG, Jones AM, Webb K, Denning DW. Homogenisation of cystic fibrosis sputum by sonication—an essential step for *Aspergillus* PCR. *J Microbiol Methods* **2011**; 85:75–81.
87. Reinwald M, Buchheidt D, Hummel M, et al. Diagnostic performance of an *Aspergillus*-specific nested PCR assay in cerebrospinal fluid samples of immunocompromised patients for detection of central nervous system aspergillosis. *PLoS One* **2013**; 8:e56706.
88. Reinwald M, Spiess B, Heinz WJ, et al. *Aspergillus* PCR-based investigation of fresh tissue and effusion samples in patients with suspected invasive aspergillosis enhances diagnostic capabilities. *J Clin Microbiol* **2013**; 51:4178–85.
89. Buitrago MJ, Aguado JM, Ballen A, et al. Efficacy of DNA amplification in tissue biopsy samples to improve the detection of invasive fungal disease. *Clin Microbiol Infect* **2013**; 19:E271–7.
90. Herbrecht R, Letscher-Bru V, Oprea C, et al. *Aspergillus* galactomannan detection in the diagnosis of invasive aspergillosis in cancer patients. *J Clin Oncol* **2002**; 7:1898–906.
91. Marr KA, Balajee SA, McLaughlin L, Tabouret M, Bentsen C, Walsh TJ. Detection of galactomannan antigenemia by enzyme immunoassay for the diagnosis of invasive aspergillosis: variables that affect performance. *J Infect Dis* **2004**; 190:641–9.
92. Maertens J, Glasmacher A, Selleslag D, et al. Evaluation of serum sandwich enzyme-linked immunosorbent assay for circulating galactomannan during caspofungin therapy: results from the caspofungin invasive aspergillosis study. *Clin Infect Dis* **2005**; 41:e9–14.
93. Maertens J, Van Eldere J, Verhaegen J, Verbeken E, Verschakelen J, Boogaerts M. Use of circulating galactomannan screening for early diagnosis of invasive aspergillosis in allogeneic stem cell transplant recipients. *J Infect Dis* **2002**; 186:1297–306.
94. Maertens JA, Klont R, Masson C, et al. Optimization of the cutoff value for the *Aspergillus* double-sandwich enzyme immunoassay. *Clin Infect Dis* **2007**; 44:1329–36.
95. Pfeiffer CD, Fine JP, Safdar N. Diagnosis of invasive aspergillosis using a galactomannan assay: a meta-analysis. *Clin Infect Dis* **2006**; 42:1417–27.
96. Maertens J, Theunissen K, Verhoef G, et al. Galactomannan and computed tomography-based preemptive antifungal therapy in neutropenic patients at high risk for invasive fungal infection: a prospective feasibility study. *Clin Infect Dis* **2005**; 41:1242–50.
97. Ku NS, Han SH, Choi JY, et al. Diagnostic value of the serum galactomannan assay for invasive aspergillosis: it is less useful in non-hematological patients. *Scand J Infect Dis* **2012**; 44:600–4.
98. Fortun J, Martin-Davila P, Alvarez ME, et al. False-positive results of *Aspergillus* galactomannan antigenemia in liver transplant recipients. *Transplantation* **2009**; 87:256–60.
99. Kwak EJ, Husain S, Obman A, et al. Efficacy of galactomannan antigen in the Platelia *Aspergillus* enzyme immunoassay for diagnosis of invasive aspergillosis in liver transplant recipients. *J Clin Microbiol* **2004**; 42:435–8.
100. Husain S, Kwak EJ, Obman A, et al. Prospective assessment of Platelia *Aspergillus* galactomannan antigen for the diagnosis of invasive aspergillosis in lung transplant recipients. *Am J Transplant* **2004**; 4:796–802.
101. Verweij PE, Weemaes CM, Curfs JHAJ, Bretagne S, Meis JFGM. Failure to detect circulating *Aspergillus* markers in a patient with chronic granulomatous disease and invasive aspergillosis. *J Clin Microbiol* **2000**; 38:3900–1.
102. Mortensen KL, Knudsen JB, Jensen-Fangel S, Stausbol-Gron B, Arendrup MC, Petersen E. Successful management of invasive aspergillosis presenting as pericarditis in an adult patient with chronic granulomatous disease. *Mycoses* **2011**; 54:e233–6.
103. Hidalgo A, Parody R, Martino R, et al. Correlation between high-resolution computed tomography and galactomannan antigenemia in adult hematologic patients at risk for invasive aspergillosis. *Eur J Radiol* **2009**; 71:55–60.
104. Steinbach WJ, Addison RM, McLaughlin L, et al. Prospective *Aspergillus* galactomannan antigen testing in pediatric hematopoietic stem cell transplant recipients. *Pediatr Infect Dis J* **2007**; 26:558–64.
105. Hayden R, Pounds S, Knapp K, et al. Galactomannan antigenemia in pediatric oncology patients with invasive aspergillosis. *Pediatr Infect Dis J* **2008**; 27:815–9.
106. Castagnola E, Furfaro E, Caviglia I, et al. Performance of the galactomannan antigen detection test in the diagnosis of invasive aspergillosis in children with cancer or undergoing haemopoietic stem cell transplantation. *Clin Microbiol Infect* **2010**; 16:1197–203.
107. Fisher BT, Zaoutis TE, Park JR, et al. Galactomannan antigen testing for diagnosis of invasive aspergillosis in pediatric hematology patients. *J Pediatric Infect Dis Soc* **2012**; 1:103–11.
108. Dinand V, Anjan M, Oberoi JK, et al. Threshold of galactomannan antigenemia positivity for early diagnosis of invasive aspergillosis in neutropenic children. *J Microbiol Immunol Infect* **2016**; 49:66–73.
109. Choi SH, Kang ES, Eo H, et al. *Aspergillus* galactomannan antigen assay and invasive aspergillosis in pediatric cancer patients and hematopoietic stem cell transplant recipients. *Pediatr Blood Cancer* **2013**; 60:316–22.
110. Jha AK, Bansal D, Chakrabarti A, Shivaprakash MR, Trehan A, Marwaha RK. Serum galactomannan assay for the diagnosis of invasive aspergillosis in children with haematological malignancies. *Mycoses* **2013**; 56:442–8.
111. Badiee P, Alborzi A, Karimi M, et al. Diagnostic potential of nested PCR, galactomannan EIA, and beta-D-glucan for invasive aspergillosis in pediatric patients. *J Infect Dev Ctries* **2012**; 6:352–7.
112. Park SY, Lee SO, Choi SH, et al. Serum and bronchoalveolar lavage fluid galactomannan assays in patients with pulmonary aspergilloma. *Clin Infect Dis* **2011**; 52:e149–52.
113. Shin B, Koh WJ, Jeong BH, et al. Serum galactomannan antigen test for the diagnosis of chronic pulmonary aspergillosis. *J Infect* **2014**; 68:494–9.
114. Aquino VR, Nagel F, Andreolla HF, et al. The performance of real-time PCR, galactomannan, and fungal culture in the diagnosis of invasive aspergillosis in ventilated patients with chronic obstructive pulmonary disease (COPD). *Mycopathologia* **2012**; 174:163–9.
115. Warren TA, Yau Y, Ratjen F, Tullis E, Waters V. Serum galactomannan in cystic fibrosis patients colonized with *Aspergillus* species. *Med Mycol* **2012**; 50:658–60.
116. Cordonnier C, Botterel F, Ben Amor R, et al. Correlation between galactomannan antigen levels in serum and neutrophil counts in hematological patients with invasive aspergillosis. *Clin Microbiol Infect* **2009**; 15:81–6.
117. Petraitiene R, Petraitis V, Bacher JD, Finkelman MA, Walsh TJ. Effects of host response and antifungal therapy on serum and BAL levels of galactomannan and (1->3)-beta-D-glucan in experimental invasive pulmonary aspergillosis. *Med Mycol* **2015**; 53:558–68.
118. Vergidis P, Razonable RR, Wheat LJ, et al. Reduction in false-positive *Aspergillus* serum galactomannan enzyme immunoassay results associated with use of piperacillin-tazobactam in the United States. *J Clin Microbiol* **2014**; 52:2199–201.
119. Mennink-Kersten MA, Ruegebrink D, Klont RR, et al. Bifidobacterial lipoglycan as a new cause for false-positive platelia *Aspergillus* enzyme-linked immunosorbent assay reactivity. *J Clin Microbiol* **2005**; 43:3925–31.
120. Sulahian A, Touratier S, Ribaud P. False positive test for aspergillus antigenemia related to concomitant administration of piperacillin and tazobactam. *N Engl J Med* **2003**; 349:2366–7.
121. Mennink-Kersten MA, Donnelly JP, Verweij PE. Detection of circulating galactomannan for the diagnosis and management of invasive aspergillosis. *Lancet Infect Dis* **2004**; 4:349–57.
122. Mennink-Kersten MA, Klont RR, Warris A, Op den Camp HJ, Verweij PE. *Bifidobacterium* lipoteichoic acid and false ELISA reactivity in *Aspergillus* antigen detection. *Lancet* **2004**; 363:325–7.
123. Schwarzing M, Sagaon-Teyssier L, Cabaret O, Bretagne S, Cordonnier C. Performance of serum biomarkers for the early detection of invasive aspergillosis in febrile, neutropenic patients: a multi-state model. *PLoS One* **2013**; 8:e57776.
124. Duarte RF, Sanchez-Ortega I, Cuesta I, et al. Serum galactomannan-based early detection of invasive aspergillosis in hematology patients receiving effective antimold prophylaxis. *Clin Infect Dis* **2014**; 59:1696–702.
125. Husain S, Clancy CJ, Nguyen MH, et al. Performance characteristics of the platelia *Aspergillus* enzyme immunoassay for detection of *Aspergillus* galactomannan antigen in bronchoalveolar lavage fluid. *Clin Vaccine Immunol* **2008**; 15:1760–3.
126. Musher B, Fredricks D, Leisenring W, Balajee SA, Smith C, Marr KA. *Aspergillus* galactomannan enzyme immunoassay and quantitative PCR for diagnosis of invasive aspergillosis with bronchoalveolar lavage fluid. *J Clin Microbiol* **2004**; 42:5517–22.
127. Maertens J, Maertens V, Theunissen K, et al. Bronchoalveolar lavage fluid galactomannan for the diagnosis of invasive pulmonary aspergillosis in patients with hematologic diseases. *Clin Infect Dis* **2009**; 49:1688–93.
128. D’Haese J, Theunissen K, Vermeulen E, et al. Detection of galactomannan in bronchoalveolar lavage fluid samples of patients at risk for invasive pulmonary aspergillosis: analytical and clinical validity. *J Clin Microbiol* **2012**; 50:1258–63.

129. Ostrosky-Zeichner L, Alexander BD, Kett DH, et al. Multicenter clinical evaluation of the (1->3) beta-D-glucan assay as an aid to diagnosis of fungal infections in humans. *Clin Infect Dis* **2005**; 41:654-9.
130. Lamoth F, Cruciani M, Mengoli C, et al. β -Glucan antigenemia assay for the diagnosis of invasive fungal infections in patients with hematological malignancies: a systematic review and meta-analysis of cohort studies from the Third European Conference on Infections in Leukemia (ECIL-3). *Clin Infect Dis* **2012**; 54:633-43.
131. Marty FM, Lowry CM, Lempiński SJ, Kubiak DW, Finkelman MA, Baden LR. Reactivity of (1->3)-beta-D-glucan assay with commonly used intravenous antimicrobials. *Antimicrob Agents Chemother* **2006**; 50:3450-3.
132. Odabasi Z, Mattiuzzi G, Estey E, et al. Beta-D-glucan as a diagnostic adjunct for invasive fungal infections: validation, cutoff development, and performance in patients with acute myelogenous leukemia and myelodysplastic syndrome. *Clin Infect Dis* **2004**; 39:199-205.
133. Sulhayan A, Porcher R, Bergeron A, et al. Use and limits of (1-3)-beta-D-glucan assay (Fungitell), compared to galactomannan determination (Platelia *Aspergillus*), for diagnosis of invasive aspergillosis. *J Clin Microbiol* **2014**; 52:2328-33.
134. Hachem RY, Kontoyiannis DP, Chemaly RF, Jiang Y, Reitzel R, Raad I. Utility of galactomannan enzyme immunoassay and (1,3) beta-D-glucan in diagnosis of invasive fungal infections: low sensitivity for *Aspergillus fumigatus* infection in hematologic malignancy patients. *J Clin Microbiol* **2009**; 47:129-33.
135. Pazos C, Ponton J, Del Palacio A. Contribution of (1->3)-beta-D-glucan chromogenic assay to diagnosis and therapeutic monitoring of invasive aspergillosis in neutropenic adult patients: a comparison with serial screening for circulating galactomannan. *J Clin Microbiol* **2005**; 43:299-305.
136. Marchetti O, Lamoth F, Mikulska M, et al. ECIL recommendations for the use of biological markers for the diagnosis of invasive fungal diseases in leukemic patients and hematopoietic SCT recipients. *Bone Marrow Transplant* **2012**; 47:846-54.
137. Becker MJ, Lugtenburg EJ, Cornelissen JJ, Van Der Schee C, Hoogsteden HC, De Marie S. Galactomannan detection in computerized tomography-based bronchoalveolar lavage fluid and serum in hematological patients at risk for invasive pulmonary aspergillosis. *Br J Haematol* **2003**; 121:448-57.
138. Hauggaard A, Ellis M, Ekelund L. Early chest radiography and CT in the diagnosis, management and outcome of invasive pulmonary aspergillosis. *Acta Radiol* **2002**; 43:292-8.
139. Stanzani M, Sassi C, Lewis RE, et al. High resolution computed tomography angiography improves the radiographic diagnosis of invasive mold disease in patients with hematological malignancies. *Clin Infect Dis* **2015**; 60:1603-10.
140. Busca A, Locatelli F, Barbui A, et al. Usefulness of sequential *Aspergillus* galactomannan antigen detection combined with early radiologic evaluation for diagnosis of invasive pulmonary aspergillosis in patients undergoing allogeneic stem cell transplantation. *Transplant Proc* **2006**; 38:1610-3.
141. Weisser M, Rausch C, Droll A, et al. Galactomannan does not precede major signs on a pulmonary computerized tomographic scan suggestive of invasive aspergillosis in patients with hematological malignancies. *Clin Infect Dis* **2005**; 41:1143-9.
142. Caillot D, Casasnovas O, Bernard A, et al. Improved management of invasive pulmonary aspergillosis in neutropenic patients using early thoracic computed tomographic scan and surgery. *J Clin Oncol* **1997**; 15:139-47.
143. Nucci M, Nouer SA, Graziutti M, Kumar NS, Barlogie B, Anaissie E. Probable invasive aspergillosis without prespecified radiologic findings: proposal for inclusion of a new category of aspergillosis and implications for studying novel therapies. *Clin Infect Dis* **2010**; 51:1273-80.
144. Li XS, Zhu HX, Fan HX, Zhu L, Wang HX, Song YL. Pulmonary fungal infections after bone marrow transplantation: the value of high-resolution computed tomography in predicting their etiology. *Chin Med J (Engl)* **2011**; 124:3249-54.
145. Greene RE, Schlamm HT, Oestmann JW, et al. Imaging findings in acute invasive pulmonary aspergillosis: clinical significance of the halo sign. *Clin Infect Dis* **2007**; 44:373-9.
146. Bruno C, Minniti S, Vassanelli A, Pozzi-Mucelli R. Comparison of CT features of *Aspergillus* and bacterial pneumonia in severely neutropenic patients. *J Thorac Imaging* **2007**; 22:160-5.
147. Brook O, Guralnik L, Hardak E, et al. Radiological findings of early invasive pulmonary aspergillosis in immune-compromised patients. *Hematol Oncol* **2009**; 27:102-6.
148. Legouge C, Caillot D, Chretien ML, et al. The reversed halo sign: pathognomonic pattern of pulmonary mucormycosis in leukemic patients with neutropenia? *Clin Infect Dis* **2014**; 58:672-8.
149. Wahba H, Truong MT, Lei X, Kontoyiannis DP, Marom EM. Reversed halo sign in invasive pulmonary fungal infections. *Clin Infect Dis* **2008**; 46:1733-7.
150. Georgiadou SP, Sipsas NV, Marom EM, Kontoyiannis DP. The diagnostic value of halo and reversed halo signs for invasive mold infections in compromised hosts. *Clin Infect Dis* **2011**; 52:1144-55.
151. Maturu VN, Agarwal R. Reversed halo sign: a systematic review. *Respir Care* **2014**; 59:1440-9.
152. Bergeron A, Porcher R, Sulhayan A, et al. The strategy for the diagnosis of invasive pulmonary aspergillosis should depend on both the underlying condition and the leukocyte count of patients with hematologic malignancies. *Blood* **2012**; 119:1831-7.
153. Blum U, Windfuhr M, Buitrago-Tellez C, Sigmund G, Herbst EW, Langer M. Invasive pulmonary aspergillosis. MRI, CT, and plain radiographic findings and their contribution for early diagnosis. *Chest* **1994**; 106:1156-61.
154. Gabelmann A, Klein S, Kern W, et al. Relevant imaging findings of cerebral aspergillosis on MRI: a retrospective case-based study in immunocompromised patients. *Eur J Neurol* **2007**; 14:548-55.
155. Starkey J, Moritani T, Kirby P. MRI of CNS fungal infections: review of aspergillosis to histoplasmosis and everything in between. *Clin Neuroradiol* **2014**; 24:217-30.
156. Yamada K, Shrier DA, Rubio A, et al. Imaging findings in intracranial aspergillosis. *Acad Radiol* **2002**; 9:163-71.
157. Kourkoumpetis TK, Desalermos A, Muhammed M, Mylonakis E. Central nervous system aspergillosis: a series of 14 cases from a general hospital and review of 123 cases from the literature. *Medicine* **2012**; 91:328-36.
158. Siddiqui AA, Bashir SH, Ali Shah A, et al. Diagnostic MR imaging features of craniocerebral aspergillosis of sino-nasal origin in immunocompetent patients. *Acta Neurochir (Wien)* **2006**; 148:155-66.
159. Caillot D, Couaillier JF, Bernard A, et al. Increasing volume and changing characteristics of invasive pulmonary aspergillosis on sequential thoracic computed tomography scans in patients with neutropenia. *J Clin Oncol* **2001**; 19:253-9.
160. Sampsonas F, Kontoyiannis DP, Dickey BF, Evans SE. Performance of a standardized bronchoalveolar lavage protocol in a comprehensive cancer center: a prospective 2-year study. *Cancer* **2011**; 117:3424-33.
161. Maschmeyer G, Beinert T, Buchheidt D, et al. Diagnosis and antimicrobial therapy of lung infiltrates in febrile neutropenic patients: guidelines of the infectious diseases working party of the German Society of Haematology and Oncology. *Eur J Cancer* **2009**; 45:2462-72.
162. Pereira Gomes JC, Pedreira WL Jr, Araujo EM, et al. Impact of BAL in the management of pneumonia with treatment failure: positivity of BAL culture under antibiotic therapy. *Chest* **2000**; 118:1739-46.
163. Velez L, Correa LT, Maya MA, et al. Diagnostic accuracy of bronchoalveolar lavage samples in immunosuppressed patients with suspected pneumonia: analysis of a protocol. *Respir Med* **2007**; 101:2160-7.
164. Wahla AS, Chatterjee A, Khan II, Conforti JF, Haponik E. Survey of academic pulmonologists, oncologists, and infectious disease physicians on the role of bronchoscopy in managing hematopoietic stem cell transplantation patients with pulmonary infiltrates. *J Bronchology Interv Pulmonol* **2014**; 21:32-9.
165. Du Rand IA, Barber PV, Goldring J, et al. British Thoracic Society guideline for advanced diagnostic and therapeutic flexible bronchoscopy in adults. *Thorax* **2011**; 66(suppl 3):1-21.
166. Haslam PL, Baughman RP. Report of ERS Task Force: guidelines for measurement of acellular components and standardization of BAL. *Eur Respir J* **1999**; 14:245-8.
167. Meyer KC, Raghu G, Baughman RP, et al. An official American Thoracic Society clinical practice guideline: the clinical utility of bronchoalveolar lavage cellular analysis in interstitial lung disease. *Am J Respir Crit Care Med* **2012**; 185:1004-14.
168. Hage CA, Reynolds JM, Durkin M, Wheat LJ, Knox KS. Plasmalyte as a cause of false-positive results for *Aspergillus* galactomannan in bronchoalveolar lavage fluid. *J Clin Microbiol* **2007**; 45:676-7.
169. Baughman RP. Technical aspects of bronchoalveolar lavage: recommendations for a standard procedure. *Semin Respir Crit Care Med* **2007**; 28:475-85.
170. Brownback KR, Simpson SQ. Association of bronchoalveolar lavage yield with chest computed tomography findings and symptoms in immunocompromised patients. *Ann Thorac Med* **2013**; 8:153-9.
171. Anderson TM, Clay MC, Cioffi AG, et al. Amphotericin forms an extramembranous and fungicidal sterol sponge. *Nat Chem Biol* **2014**; 10:400-6.
172. Roden MM, Nelson LD, Knudsen TA, et al. Triad of acute infusion-related reactions associated with liposomal amphotericin B: analysis of clinical and epidemiological characteristics. *Clin Infect Dis* **2003**; 36:1213-20.
173. Farmakiotis D, Tverdek FP, Kontoyiannis DP. The safety of amphotericin B lipid complex in patients with prior severe intolerance to liposomal amphotericin B. *Clin Infect Dis* **2013**; 56:701-3.
174. Bowden R, Chandrasekar P, White MH, et al. A double-blind, randomized, controlled trial of amphotericin B colloidal dispersion versus amphotericin B for treatment of invasive aspergillosis in immunocompromised patients. *Clin Infect Dis* **2002**; 35:359-66.
175. Cornely OA, Maertens J, Bresnik M, et al. Liposomal amphotericin B as initial therapy for invasive mold infection: a randomized trial comparing a high-loading

- dose regimen with standard dosing (AmBiLoad trial). *Clin Infect Dis* **2007**; 44:1289–97.
176. Borro JM, Sole A, de la Torre M, et al. Efficiency and safety of inhaled amphotericin B lipid complex (Abelcet) in the prophylaxis of invasive fungal infections following lung transplantation. *Transplant Proc* **2008**; 40:3090–3.
 177. Rijnders BJ, Cornelissen JJ, Slobbe L, et al. Aerosolized liposomal amphotericin B for the prevention of invasive pulmonary aspergillosis during prolonged neutropenia: a randomized, placebo-controlled trial. *Clin Infect Dis* **2008**; 46:1401–8.
 178. Sehgal IS, Agarwal R. Role of inhaled amphotericin in allergic bronchopulmonary aspergillosis. *J Postgrad Med* **2014**; 60:41–5.
 179. Safdar A, Rodriguez GH. Aerosolized amphotericin B lipid complex as adjunctive treatment for fungal lung infection in patients with cancer-related immunosuppression and recipients of hematopoietic stem cell transplantation. *Pharmacotherapy* **2013**; 33:1035–43.
 180. Nihtinen A, Anttila VJ, Ruutu T, Juvonen E, Volin L. Low incidence of invasive aspergillosis in allogeneic stem cell transplant recipients receiving amphotericin B inhalation prophylaxis. *Transpl Infect Dis* **2012**; 14:24–32.
 181. Morello E, Pagani L, Coser P, et al. Addition of aerosolized deoxycholate amphotericin B to systemic prophylaxis to prevent airways invasive fungal infections in allogeneic hematopoietic SCT: a single-center retrospective study. *Bone Marrow Transplant* **2011**; 46:132–6.
 182. Monforte V, Ussetti P, Lopez R, et al. Nebulized liposomal amphotericin B prophylaxis for *Aspergillus* infection in lung transplantation: pharmacokinetics and safety. *J Heart Lung Transplant* **2009**; 28:170–5.
 183. Monforte V, Ussetti P, Gavalda J, et al. Feasibility, tolerability, and outcomes of nebulized liposomal amphotericin B for *Aspergillus* infection prevention in lung transplantation. *J Heart Lung Transplant* **2010**; 29:523–30.
 184. Sole A. Invasive fungal infections in lung transplantation: role of aerosolized amphotericin B. *Int J Antimicrob Agents* **2008**; 32(suppl 2):S161–5.
 185. Denning DW. Echinocandin antifungal drugs. *Lancet* **2003**; 362:1142–51.
 186. Walsh TJ, Adamson PC, Seibel NL, et al. Pharmacokinetics, safety, and tolerability of caspofungin in children and adolescents. *Antimicrob Agents Chemother* **2005**; 49:4536–45.
 187. Seibel NL, Schwartz C, Arrieta A, et al. Safety, tolerability, and pharmacokinetics of micafungin (FK463) in febrile neutropenic pediatric patients. *Antimicrob Agents Chemother* **2005**; 49:3317–24.
 188. Hall RG, Swancutt MA, Gumbo T. Fractal geometry and the pharmacometrics of micafungin in overweight, obese, and extremely obese people. *Antimicrob Agents Chemother* **2011**; 55:5107–12.
 189. Wurthwein G, Cornely OA, Trame MN, et al. Population pharmacokinetics of escalating doses of caspofungin in a phase II study of patients with invasive aspergillosis. *Antimicrob Agents Chemother* **2013**; 57:1664–71.
 190. Cornely OA, Vehreschild JJ, Vehreschild MJ, et al. Phase II dose escalation study of caspofungin for invasive aspergillosis. *Antimicrob Agents Chemother* **2011**; 55:798–803.
 191. Herbrecht R, Maertens J, Baila L, et al. Caspofungin first-line therapy for invasive aspergillosis in allogeneic hematopoietic stem cell transplant patients: an European Organisation for Research and Treatment of Cancer Study. *Bone Marrow Transplant* **2010**; 45:1227–33.
 192. Viscoli C, Herbrecht R, Akan H, et al. An EORTC phase II study of caspofungin as first-line therapy of invasive aspergillosis in haematological patients. *J Antimicrob Chemother* **2009**; 64:1274–81.
 193. Kohno S, Izumikawa K, Ogawa K, et al. Intravenous micafungin versus voriconazole for chronic pulmonary aspergillosis: a multicenter trial in Japan. *J Infect* **2010**; 61:410–8.
 194. Denning DW, Marr KA, Lau WM, et al. Micafungin (FK463), alone or in combination with other systemic antifungal agents, for the treatment of acute invasive aspergillosis. *J Infect* **2006**; 53:337–49.
 195. Hiemenz JW, Raad II, Maertens JA, et al. Efficacy of caspofungin as salvage therapy for invasive aspergillosis compared to standard therapy in a historical cohort. *Eur J Clin Microbiol Infect Dis* **2010**; 29:1387–94.
 196. Kontoyannis DP, Ratanatharathorn V, Young JA, et al. Micafungin alone or in combination with other systemic antifungal therapies in hematopoietic stem cell transplant recipients with invasive aspergillosis. *Transpl Infect Dis* **2009**; 11:89–93.
 197. Maertens J, Glasmacher A, Herbrecht R, et al. Multicenter, noncomparative study of caspofungin in combination with other antifungals as salvage therapy in adults with invasive aspergillosis. *Cancer* **2006**; 107:2888–97.
 198. Singh N, Limaye AP, Forrest G, et al. Combination of voriconazole and caspofungin as primary therapy for invasive aspergillosis in solid organ transplant recipients: a prospective, multicenter, observational study. *Transplantation* **2006**; 81:320–6.
 199. Slain D, Rogers PD, Cleary JD, Chapman SW. Intravenous itraconazole. *Ann Pharmacother* **2001**; 35:720–9.
 200. Willems L, van der Geest R, de Beule K. Itraconazole oral solution and intravenous formulations: a review of pharmacokinetics and pharmacodynamics. *J Clin Pharm Ther* **2001**; 26:159–69.
 201. Lazo de la Vega S, Volkow P, Yeates RA, Pfaff G. Administration of the antimycotic agents fluconazole and itraconazole to leukaemia patients: a comparative pharmacokinetic study. *Drugs Exp Clin Res* **1994**; 20:69–75.
 202. Hardin TC, Graybill JR, Fetchick R, Woestenborghs R, Rinaldi MG, Kuhn JG. Pharmacokinetics of itraconazole following oral administration to normal volunteers. *Antimicrob Agents Chemother* **1988**; 32:1310–3.
 203. Kim JS, Cheong JW, Kim YK, et al. The relationship between the success rate of empirical antifungal therapy with intravenous itraconazole and clinical parameters, including plasma levels of itraconazole, in immunocompromised patients receiving itraconazole oral solution as prophylaxis: a multicenter, prospective, open-label, observational study in Korea. *Ann Hematol* **2014**; 93:33–42.
 204. Baxter CG, Marshall A, Roberts M, Felton TW, Denning DW. Peripheral neuropathy in patients on long-term triazole antifungal therapy. *J Antimicrob Chemother* **2011**; 66:2136–9.
 205. Marr KA, Leisenring W, Crippa F, et al. Cyclophosphamide metabolism is affected by azole antifungals. *Blood* **2004**; 103:1557–9.
 206. Frank DW, Gray JE, Weaver RN. Cyclohexin nephrosis in the rat. *Am J Pathol* **1976**; 83:367–82.
 207. Luke DR, Tomaszewski K, Damle B, Schlam HT. Review of the basic and clinical pharmacology of sulfolbutylether-beta-cyclodextrin (SBECD). *J Pharm Sci* **2010**; 99:3291–301.
 208. Hyland R, Jones BC, Smith DA. Identification of the cytochrome P450 enzymes involved in the N-oxidation of voriconazole. *Drug Metab Dispos* **2003**; 31:540–7.
 209. Boucher HW, Groll AH, Chiu CC, Walsh TJ. Newer systemic antifungal agents: pharmacokinetics, safety and efficacy. *Drugs* **2004**; 64:1997–2020.
 210. Kim SH, Lee DG, Kwon JC, et al. Clinical impact of cytochrome P450 2C19 genotype on the treatment of invasive aspergillosis under routine therapeutic drug monitoring of voriconazole in a Korean population. *Infect Chemother* **2013**; 45:406–14.
 211. Zonios D, Yamazaki H, Murayama N, et al. Voriconazole metabolism, toxicity, and the effect of cytochrome P450 2C19 genotype. *J Infect Dis* **2014**; 209:1941–8.
 212. Mikus G, Scholz IM, Weiss J. Pharmacogenomics of the triazole antifungal agent voriconazole. *Pharmacogenomics* **2011**; 12:861–72.
 213. Dolton MJ, McLachlan AJ. Voriconazole pharmacokinetics and exposure-response relationships: assessing the links between exposure, efficacy and toxicity. *Int J Antimicrob Agents* **2014**; 44:183–93.
 214. Dolton MJ, Ray JE, Chen SC, Ng K, Pont LG, McLachlan AJ. Multicenter study of voriconazole pharmacokinetics and therapeutic drug monitoring. *Antimicrob Agents Chemother* **2012**; 56:4793–9.
 215. Smith J, Safdar N, Knasinski V, et al. Voriconazole therapeutic drug monitoring. *Antimicrob Agents Chemother* **2006**; 50:1570–2.
 216. Denning DW, Ribaud P, Milpied N, et al. Efficacy and safety of voriconazole in the treatment of acute invasive aspergillosis. *Clin Infect Dis* **2002**; 34:563–71.
 217. Pascual A, Calandra T, Bolay S, Buclin T, Bille J, Marchetti O. Voriconazole therapeutic drug monitoring in patients with invasive mycoses improves efficacy and safety outcomes. *Clin Infect Dis* **2008**; 46:201–11.
 218. Trifilio S, Singhal S, Williams S, et al. Breakthrough fungal infections after allogeneic hematopoietic stem cell transplantation in patients on prophylactic voriconazole. *Bone Marrow Transplant* **2007**; 40:451–6.
 219. Dolton MJ, Mikus G, Weiss J, Ray JE, McLachlan AJ. Understanding variability with voriconazole using a population pharmacokinetic approach: implications for optimal dosing. *J Antimicrob Chemother* **2014**; 69:1633–41.
 220. Mitsani D, Nguyen MH, Shields RK, et al. Prospective, observational study of voriconazole therapeutic drug monitoring among lung transplant recipients receiving prophylaxis: factors impacting levels of and associations between serum troughs, efficacy, and toxicity. *Antimicrob Agents Chemother* **2012**; 56:2371–7.
 221. Hamada Y, Seto Y, Yago K, Kuroyama M. Investigation and threshold of optimum blood concentration of voriconazole: a descriptive statistical meta-analysis. *J Infect Chemother* **2012**; 18:501–7.
 222. Miyakis S, van Hal SJ, Ray J, Marriott D. Voriconazole concentrations and outcome of invasive fungal infections. *Clin Microbiol Infect* **2010**; 16:927–33.
 223. Theuretzbacher U, Ihle F, Derendorf H. Pharmacokinetic/pharmacodynamic profile of voriconazole. *Clin Pharmacokinet* **2006**; 45:649–63.
 224. Imhof A, Schaefer DJ, Schanz U, Schwarz U. Neurological adverse events to voriconazole: evidence for therapeutic drug monitoring. *Swiss Med Wkly* **2006**; 136:739–42.
 225. Lazarus HM, Blumer JL, Yanovich S, Schlam H, Romero A. Safety and pharmacokinetics of oral voriconazole in patients at risk of fungal infection: a dose escalation study. *J Clin Pharmacol* **2002**; 42:395–402.
 226. Geist MJ, Egerer G, Burhenne J, Riedel KD, Weiss J, Mikus G. Steady-state pharmacokinetics and metabolism of voriconazole in patients. *J Antimicrob Chemother* **2013**; 68:2592–9.

227. Boyd AE, Modi S, Howard SJ, Moore CB, Keevil BG, Denning DW. Adverse reactions to voriconazole. *Clin Infect Dis* **2004**; 39:1241–4.
228. Eiden C, Peyriere H, Cociglio M, et al. Adverse effects of voriconazole: analysis of the French Pharmacovigilance Database. *Ann Pharmacother* **2007**; 41:755–63.
229. Tan K, Brayshaw N, Tomaszewski K, Troke P, Wood N. Investigation of the potential relationships between plasma voriconazole concentrations and visual adverse events or liver function test abnormalities. *J Clin Pharmacol* **2006**; 46:235–43.
230. den Hollander JG, van Arkel C, Rijnders BJ, Lugtenburg PJ, de Marie S, Levin MD. Incidence of voriconazole hepatotoxicity during intravenous and oral treatment for invasive fungal infections. *J Antimicrob Chemother* **2006**; 57:1248–50.
231. Luong ML, Hosseini-Moghaddam SM, Singer LG, et al. Risk factors for voriconazole hepatotoxicity at 12 weeks in lung transplant recipients. *Am J Transplant* **2012**; 12:1929–35.
232. Wu Q, Marescaux C, Wolff V, et al. Tacrolimus-associated posterior reversible encephalopathy syndrome after solid organ transplantation. *Eur Neurol* **2010**; 64:169–77.
233. Kuypers DR. Immunotherapy in elderly transplant recipients: a guide to clinically significant drug interactions. *Drugs Aging* **2009**; 26:715–37.
234. Bucknor MD, Gross AJ, Link TM. Voriconazole-induced periostitis in two post-transplant patients. *J Radiol Case Rep* **2013**; 7:10–7.
235. Lustenberger DP, Granata JD, Schar Schmidt TJ. Periostitis secondary to prolonged voriconazole therapy in a lung transplant recipient. *Orthopedics* **2011**; 34:e793–6.
236. Moon WJ, Scheller EL, Suneja A, et al. Plasma fluoride level as a predictor of voriconazole-induced periostitis in patients with skeletal pain. *Clin Infect Dis* **2014**; 59:1237–45.
237. Wang TF, Wang T, Altman R, et al. Periostitis secondary to prolonged voriconazole therapy in lung transplant recipients. *Am J Transplant* **2009**; 9:2845–50.
238. Wermers RA, Cooper K, Razonable RR, et al. Fluoride excess and periostitis in transplant patients receiving long-term voriconazole therapy. *Clin Infect Dis* **2011**; 52:604–11.
239. Gerber B, Guggenberger R, Fasler D, et al. Reversible skeletal disease and high fluoride serum levels in hematologic patients receiving voriconazole. *Blood* **2012**; 120:2390–4.
240. Thompson GR 3rd, Bays D, Cohen SH, Pappagianis D. Fluoride excess in candidoidomycosis patients receiving long-term antifungal therapy: an assessment of currently available triazoles. *Antimicrob Agents Chemother* **2012**; 56:563–4.
241. McLaughlin JM, Equils O, Somerville KT, et al. Risk-adjusted relationship between voriconazole utilization and non-melanoma skin cancer among lung and heart/lung transplant patients. *Transpl Infect Dis* **2013**; 15:329–43.
242. Zwald FO, Brown M. Skin cancer in solid organ transplant recipients: advances in therapy and management: part I. Epidemiology of skin cancer in solid organ transplant recipients. *J Am Acad Dermatol* **2011**; 65:253–61; quiz 62.
243. Zwald FO, Spratt M, Lemos BD, et al. Duration of voriconazole exposure: an independent risk factor for skin cancer after lung transplantation. *Dermatol Surg* **2012**; 38:1369–74.
244. Jung DS, Tverdek FP, Kontoyiannis DP. Switching from posaconazole suspension to tablets increased serum levels in leukemia patients without clinically relevant hepatotoxicity. *Antimicrob Agents Chemother* **2014**; 58:6993–5.
245. Miceli MH, Perissinotti AJ, Kauffman CA, Couriel DR. Serum posaconazole levels among hematological cancer patients taking extended release tablets is affected by body weight and diarrhoea: single centre retrospective analysis. *Mycoses* **2015**; 58:432–6.
246. Cumpston A, Caddell R, Shillingburg A, et al. Superior serum concentrations with posaconazole delayed-release tablets compared to suspension formulation in hematological malignancies. *Antimicrob Agents Chemother* **2015**; 59:4424–8.
247. Sanchez-Ortega I, Vazquez L, Montes C, et al. Effect of posaconazole on cyclosporine blood levels and dose adjustment in allogeneic blood and marrow transplant recipients. *Antimicrob Agents Chemother* **2012**; 56:6422–4.
248. Gubbins PO, Krishna G, Sansone-Parsons A, et al. Pharmacokinetics and safety of oral posaconazole in neutropenic stem cell transplant recipients. *Antimicrob Agents Chemother* **2006**; 50:1993–9.
249. Ullmann AJ, Cornely OA, Burchardt A, et al. Pharmacokinetics, safety, and efficacy of posaconazole in patients with persistent febrile neutropenia or refractory invasive fungal infection. *Antimicrob Agents Chemother* **2006**; 50:658–66.
250. Dolton MJ, Ray JE, Marriott D, McLachlan AJ. Posaconazole exposure-response relationship: evaluating the utility of therapeutic drug monitoring. *Antimicrob Agents Chemother* **2012**; 56:2806–13.
251. Bryant AM, Slain D, Cumpston A, Craig M. A post-marketing evaluation of posaconazole plasma concentrations in neutropenic patients with hematological malignancy receiving posaconazole prophylaxis. *Int J Antimicrob Agents* **2011**; 37:266–9.
252. Lignell A, Lowdin E, Cars O, Chryssanthou E, Sjolin J. Posaconazole in human serum: a greater pharmacodynamic effect than predicted by the non-protein-bound serum concentration. *Antimicrob Agents Chemother* **2011**; 55:3099–104.
253. Lebeaux D, Lantermier F, Elie C, et al. Therapeutic drug monitoring of posaconazole: a monocentric study with 54 adults. *Antimicrob Agents Chemother* **2009**; 53:5224–9.
254. Ullmann AJ, Lipton JH, Vesole DH, et al. Posaconazole or fluconazole for prophylaxis in severe graft-versus-host disease. *N Engl J Med* **2007**; 356:335–47.
255. Walsh TJ, Raad I, Patterson TF, et al. Treatment of invasive aspergillosis with posaconazole in patients who are refractory to or intolerant of conventional therapy: an externally controlled trial. *Clin Infect Dis* **2007**; 44:2–12.
256. Dolton MJ, Ray JE, Chen SC, Ng K, Pont L, McLachlan AJ. Multicenter study of posaconazole therapeutic drug monitoring: exposure-response relationship and factors affecting concentration. *Antimicrob Agents Chemother* **2012**; 56:5503–10.
257. Miceli MH, Kauffman CA. Isavuconazole: a new broad-spectrum triazole antifungal agent. *Clin Infect Dis* **2015**; 61:1558–65.
258. Falci DR, Pasqualotto AC. Profile of isavuconazole and its potential in the treatment of severe invasive fungal infections. *Infect Drug Resist* **2013**; 6:163–74.
259. Livermore J, Hope W. Evaluation of the pharmacokinetics and clinical utility of isavuconazole for treatment of invasive fungal infections. *Expert Opin Drug Metab Toxicol* **2012**; 8:759–65.
260. Bruggemann RJ, Alfenaar JW, Blijlevens NM, et al. Clinical relevance of the pharmacokinetic interactions of azole antifungal drugs with other coadministered agents. *Clin Infect Dis* **2009**; 48:1441–58.
261. Gubbins PO. Triazole antifungal agents drug-drug interactions involving hepatic cytochrome P450. *Expert Opin Drug Metab Toxicol* **2011**; 7:1411–29.
262. Ashbee HR, Gilleece MH. Has the era of individualised medicine arrived for antifungals? A review of antifungal pharmacogenomics. *Bone Marrow Transplant* **2012**; 47:881–94.
263. Dvorak Z. Drug-drug interactions by azole antifungals: beyond a dogma of CYP3A4 enzyme activity inhibition. *Toxicol Lett* **2011**; 202:129–32.
264. Meletiadis J, Chanock S, Walsh TJ. Human pharmacogenomic variations and their implications for antifungal efficacy. *Clin Microbiol Rev* **2006**; 19:763–87.
265. Albengres E, Le Louet H, Tillement JP. Systemic antifungal agents. Drug interactions of clinical significance. *Drug Saf* **1998**; 18:83–97.
266. Baciewicz AM, Chrisman CR, Finch CK, Self TH. Update on rifampin, rifabutin, and rifapentine drug interactions. *Curr Med Res Opin* **2013**; 29:1–12.
267. Bates DW, Yu DT. Clinical impact of drug-drug interactions with systemic azole antifungals. *Drugs Today (Barc)* **2003**; 39:801–13.
268. Chan JD. Pharmacokinetic drug interactions of vinca alkaloids: summary of case reports. *Pharmacotherapy* **1998**; 18:1304–7.
269. Crane JK, Shih HT. Syncope and cardiac arrhythmia due to an interaction between itraconazole and terfenadine. *Am J Med* **1993**; 95:445–6.
270. Dannaoui E, Schwarz P, Lortholary O. In vitro interactions between antifungals and immunosuppressive drugs against zygomycetes. *Antimicrob Agents Chemother* **2009**; 53:3549–51.
271. Depont F, Vargas F, Dutronc H, et al. Drug-drug interactions with systemic antifungals in clinical practice. *Pharmacoepidemiol Drug Saf* **2007**; 16:1227–33.
272. Eiden C, Peyriere H, Tichit R, et al. Inherited long QT syndrome revealed by antifungals drug-drug interaction. *J Clin Pharm Ther* **2007**; 32:321–4.
273. Feldstein AC, Smith DH, Perrin N, et al. Reducing warfarin medication interactions: an interrupted time series evaluation. *Arch Intern Med* **2006**; 166:1009–15.
274. Gubbins PO. Mould-active azoles: pharmacokinetics, drug interactions in neutropenic patients. *Curr Opin Infect Dis* **2007**; 20:579–86.
275. Kramer MR, Amital A, Fuks L, Shitrit D. Voriconazole and itraconazole in lung transplant recipients receiving tacrolimus (FK 506): efficacy and drug interaction. *Clin Transplant* **2011**; 25:E163–7.
276. Narreddy S, Manavathu E, Chandrasekar PH, Alangaden GJ, Revankar SG. In vitro interaction of posaconazole with calcineurin inhibitors and sirolimus against zygomycetes. *J Antimicrob Chemother* **2010**; 65:701–3.
277. Nivoix Y, Ubeaud-Sequier G, Engel P, Leveque D, Herbrecht R. Drug-drug interactions of triazole antifungal agents in multimorbid patients and implications for patient care. *Curr Drug Metab* **2009**; 10:395–409.
278. Sathiapalan RK, El-Solh H. Enhanced vincristine neurotoxicity from drug interactions: case report and review of literature. *Pediatr Hematol Oncol* **2001**; 18:543–6.
279. Steinbach WJ, Schell WA, Blankenship JR, Onyewu C, Heitman J, Perfect JR. In vitro interactions between antifungals and immunosuppressants against *Aspergillus fumigatus*. *Antimicrob Agents Chemother* **2004**; 48:1664–9.
280. Purkins L, Wood N, Kleinermans D, Nichols D. Voriconazole potentiates warfarin-induced prothrombin time prolongation. *Br J Clin Pharmacol* **2003**; 56(suppl 1):24–9.

281. Wang EJ, Lew K, Casciano CN, Clement RP, Johnson WW. Interaction of common azole antifungals with P glycoprotein. *Antimicrob Agents Chemother* **2002**; 46:160–5.
282. Venkatakrisnan K, von Moltke LL, Greenblatt DJ. Effects of the antifungal agents on oxidative drug metabolism: clinical relevance. *Clin Pharmacokinet* **2000**; 38:111–80.
283. Andes D, Pascual A, Marchetti O. Antifungal therapeutic drug monitoring: established and emerging indications. *Antimicrob Agents Chemother* **2009**; 53:24–34.
284. Ashbee HR, Barnes RA, Johnson EM, Richardson MD, Gorton R, Hope WW. Therapeutic drug monitoring (TDM) of antifungal agents: guidelines from the British Society for Medical Mycology. *J Antimicrob Chemother* **2014**; 69:1162–76.
285. Lerolle N, Raffoux E, Socie G, et al. Breakthrough invasive fungal disease in patients receiving posaconazole primary prophylaxis: a 4-year study. *Clin Microbiol Infect* **2014**; 20:O952–9.
286. Mulanovich V, Lewis RE, Raad II, Kontoyiannis DP. Random plasma concentrations of voriconazole decline over time. *J Infect* **2007**; 55:e129–30.
287. Lestner JM, Roberts SA, Moore CB, Howard SJ, Denning DW, Hope WW. Toxicodynamics of itraconazole: implications for therapeutic drug monitoring. *Clin Infect Dis* **2009**; 49:928–30.
288. Park WB, Kim NH, Kim KH, et al. The effect of therapeutic drug monitoring on safety and efficacy of voriconazole in invasive fungal infections: a randomized controlled trial. *Clin Infect Dis* **2012**; 55:1080–7.
289. Boyd NK, Zoellner CL, Swancutt MA, Bhavan KP. Utilization of omeprazole to augment subtherapeutic voriconazole concentrations for treatment of *Aspergillus* infections. *Antimicrob Agents Chemother* **2012**; 56:6001–2.
290. Walsh TJ, Karlsson MO, Driscoll T, et al. Pharmacokinetics and safety of intravenous voriconazole in children after single- or multiple-dose administration. *Antimicrob Agents Chemother* **2004**; 48:2166–72.
291. Pascual A, Csajka C, Buclin T, et al. Challenging recommended oral and intravenous voriconazole doses for improved efficacy and safety: population pharmacokinetics-based analysis of adult patients with invasive fungal infections. *Clin Infect Dis* **2012**; 55:381–90.
292. Cornely OA, Maertens J, Winston DJ, et al. Posaconazole vs. fluconazole or itraconazole prophylaxis in patients with neutropenia. *N Engl J Med* **2007**; 356:348–59.
293. Duarte RF, Lopez-Jimenez J, Cornely OA, et al. Phase 1b study of new posaconazole tablet for prevention of invasive fungal infections in high-risk patients with neutropenia. *Antimicrob Agents Chemother* **2014**; 58:5758–65.
294. Krishna G, Ma L, Martinho M, Preston RA, O'Mara E. A new solid oral tablet formulation of posaconazole: a randomized clinical trial to investigate rising single- and multiple-dose pharmacokinetics and safety in healthy volunteers. *J Antimicrob Chemother* **2012**; 67:2725–30.
295. Mukherjee PK, Sheehan DJ, Hitchcock CA, Ghannoum MA. Combination treatment of invasive fungal infections. *Clin Microbiol Rev* **2005**; 18:163–94.
296. Wirk B, Wingard JR. Combination antifungal therapy: from bench to bedside. *Curr Infect Dis Rep* **2008**; 10:466–72.
297. Steinbach WJ, Juvvadi PR, Fortwendel JR, Rogg LE. Newer combination antifungal therapies for invasive aspergillosis. *Med Mycol* **2011**; 49(suppl 1): S77–81.
298. Zhang M, Sun WK, Wu T, et al. Efficacy of combination therapy of triazole and echinocandin in treatment of invasive aspergillosis: a systematic review of animal and human studies. *J Thorac Dis* **2014**; 6:99–108.
299. Martin-Pena A, Aguilar-Guisado M, Espigado I, Cisneros JM. Antifungal combination therapy for invasive aspergillosis. *Clin Infect Dis* **2014**; 59:1437–45.
300. Schaffner A, Frick PG. The effect of ketoconazole on amphotericin B in a model of disseminated aspergillosis. *J Infect Dis* **1985**; 151:902–10.
301. Schaffner A, Bohler A. Amphotericin B refractory aspergillosis after itraconazole: evidence for significant antagonism. *Mycoses* **1993**; 36:421–4.
302. Maesaki S, Kawamura S, Miyazaki Y, Tomono K, Tashiro T, Kohno S. Effect of sequential combination of amphotericin B and azole antifungal agents against *Aspergillus fumigatus*. *J Infect Chemother* **1999**; 5:125–9.
303. Lewis RE, Prince RA, Chi J, Kontoyiannis DP. Itraconazole preexposure attenuates the efficacy of subsequent amphotericin B therapy in a murine model of acute invasive pulmonary aspergillosis. *Antimicrob Agents Chemother* **2002**; 46:3208–14.
304. Steinbach WJ, Stevens DA, Denning DW. Combination and sequential antifungal therapy for invasive aspergillosis: review of published in vitro and in vivo interactions and 6281 clinical cases from 1966 to 2001. *Clin Infect Dis* **2003**; 37(suppl 3):S188–224.
305. Johnson MD, MacDougall C, Ostrosky-Zeichner L, Perfect JR, Rex JH. Combination antifungal therapy. *Antimicrob Agents Chemother* **2004**; 48:693–715.
306. Kirkpatrick WR, Coco BJ, Patterson TF. Sequential or combination antifungal therapy with voriconazole and liposomal amphotericin B in a guinea pig model of invasive aspergillosis. *Antimicrob Agents Chemother* **2006**; 50:1567–9.
307. Meletiadis J, te Dorsthorst DT, Verweij PE. The concentration-dependent nature of in vitro amphotericin B-itraconazole interaction against *Aspergillus fumigatus*: isobolographic and response surface analysis of complex pharmacodynamic interactions. *Int J Antimicrob Agents* **2006**; 28:439–49.
308. Meletiadis J, Petraitis V, Petraitiene R, et al. Triazole-polyene antagonism in experimental invasive pulmonary aspergillosis: in vitro and in vivo correlation. *J Infect Dis* **2006**; 194:1008–18.
309. Petraitis V, Petraitiene R, Hope WW, et al. Combination therapy in treatment of experimental pulmonary aspergillosis: in vitro and in vivo correlations of the concentration- and dose- dependent interactions between anidulafungin and voriconazole by Bliss independence drug interaction analysis. *Antimicrob Agents Chemother* **2009**; 53:2382–91.
310. Clemons KV, Stevens DA. Efficacy of micafungin alone or in combination against experimental pulmonary aspergillosis. *Med Mycol* **2006**; 44:69–73.
311. Wiederhold NP. Paradoxical echinocandin activity: a limited in vitro phenomenon? *Med Mycol* **2009**; 47(suppl 1):S369–75.
312. Verweij PE, Howard SJ, Melchers WJ, Denning DW. Azole-resistance in *Aspergillus*: proposed nomenclature and breakpoints. *Drug Resist Updat* **2009**; 12:141–7.
313. Eschenauer GA, Carver PL. The evolving role of antifungal susceptibility testing. *Pharmacotherapy* **2013**; 33:465–75.
314. Subcommittee on Antifungal Susceptibility Testing of the ESCMID European Committee for Antimicrobial Susceptibility Testing. EUCAST technical note on the method for the determination of broth dilution minimum inhibitory concentrations of antifungal agents for conidia-forming moulds. *Clin Microbiol Infect* **2008**; 14:982–4.
315. Clinical and Laboratory Standards Institute. Reference method for broth dilution antifungal susceptibility testing for filamentous fungi. 2nd ed. CLSI standard, M38. Wayne, PA: CLSI, **2008**.
316. Cuenca-Estrella M, Moore CB, Barchiesi F, et al. Multicenter evaluation of the reproducibility of the proposed antifungal susceptibility testing method for fermentative yeasts of the Antifungal Susceptibility Testing Subcommittee of the European Committee on Antimicrobial Susceptibility Testing (AFST-EUCAST). *Clin Microbiol Infect* **2003**; 9:467–74.
317. Espinel-Ingroff A, Diekema DJ, Fothergill A, et al. Wild-type MIC distributions and epidemiological cutoff values for the triazoles and six *Aspergillus* spp. for the CLSI broth microdilution method (M38-A2 document). *J Clin Microbiol* **2010**; 48:3251–7.
318. Rodriguez-Tudela JL, Alcazar-Fuoli L, Mellado E, Alastruey-Izquierdo A, Monzon ACuenca-Estrella M. Epidemiological cutoffs and cross-resistance to azole drugs in *Aspergillus fumigatus*. *Antimicrob Agents Chemother* **2008**; 52:2468–72.
319. Pfaller M, Boyken L, Hollis R, et al. Use of epidemiological cutoff values to examine 9-year trends in susceptibility of *Aspergillus* species to the triazoles. *J Clin Microbiol* **2011**; 49:586–90.
320. Georgiadou SP, Kontoyiannis DP. The impact of azole resistance on aspergillosis guidelines. *Ann N Y Acad Sci* **2012**; 1272:15–22.
321. Rodriguez-Tudela JL, Arendrup MC, Cuenca-Estrella M, Donnelly JP, Lass-Flörl C. EUCAST breakpoints for antifungals. *Drug News Perspect* **2010**; 23:93–7.
322. Siopi M, Mavridou E, Mouton JW, Verweij PE, Zerva L, Meletiadis J. Susceptibility breakpoints and target values for therapeutic drug monitoring of voriconazole and *Aspergillus fumigatus* in an in vitro pharmacokinetic/pharmacodynamic model. *J Antimicrob Chemother* **2014**; 69:1611–9.
323. Arendrup MC, Cuenca-Estrella M, Lass-Flörl C, Hope WW. Breakpoints for antifungal agents: an update from EUCAST focussing on echinocandins against *Candida* spp. and triazoles against *Aspergillus* spp. *Drug Resist Updat* **2013**; 16:81–95.
324. Pfaller MA, Messer SA, Woosley LN, Jones RN, Castanheira M. Echinocandin and triazole antifungal susceptibility profiles for clinical opportunistic yeast and mold isolates collected from 2010 to 2011: application of new CLSI clinical breakpoints and epidemiological cutoff values for characterization of geographic and temporal trends of antifungal resistance. *J Clin Microbiol* **2013**; 51:2571–81.
325. Taylor JW, Jacobson DJ, Kroken S, et al. Phylogenetic species recognition and species concepts in fungi. *Fungal Genet Biol* **2000**; 31:21–32.
326. Alastruey-Izquierdo A, Alcazar-Fuoli L, Cuenca-Estrella M. Antifungal susceptibility profile of cryptic species of *Aspergillus*. *Mycopathologia* **2014**; 178:427–33.
327. Chen J, Li H, Li R, Bu D, Wan Z. Mutations in the cyp51A gene and susceptibility to itraconazole in *Aspergillus fumigatus* serially isolated from a patient with lung aspergillosis. *J Antimicrob Chemother* **2005**; 55:31–7.
328. Diaz-Guerra TM, Mellado E, Cuenca-Estrella M, Rodriguez-Tudela JL. A point mutation in the 14 α -sterol demethylase gene cyp51A contributes to itraconazole resistance in *Aspergillus fumigatus*. *Antimicrob Agents Chemother* **2003**; 47:1120–4.

329. Howard SJ, Webster I, Moore CB, et al. Multi-azole resistance in *Aspergillus fumigatus*. *Int J Antimicrob Agents* **2006**; 28:450–3.
330. Mellado E, Garcia-Effron G, Alcazar-Fuoli L, Cuenca-Estrella M, Rodriguez-Tudela JL. Substitutions at methionine 220 in the 14 α -sterol demethylase (Cyp51A) of *Aspergillus fumigatus* are responsible for resistance in vitro to azole antifungal drugs. *Antimicrob Agents Chemother* **2004**; 48:2747–50.
331. Mellado E, Garcia-Effron G, Alcazar-Fuoli L, et al. A new *Aspergillus fumigatus* resistance mechanism conferring in vitro cross-resistance to azole antifungals involves a combination of cyp51A alterations. *Antimicrob Agents Chemother* **2007**; 51:1897–904.
332. Nascimento AM, Goldman GH, Park S, et al. Multiple resistance mechanisms among *Aspergillus fumigatus* mutants with high-level resistance to itraconazole. *Antimicrob Agents Chemother* **2003**; 47:1719–26.
333. Verweij PE, Mellado E, Melchers WJ. Multiple-triazole-resistant aspergillosis. *N Engl J Med* **2007**; 356:1481–3.
334. Albarrag AM, Anderson MJ, Howard SJ, et al. Interrogation of related clinical pan-azole-resistant *Aspergillus fumigatus* strains: G138C, Y431C, and G434C single nucleotide polymorphisms in cyp51A, upregulation of cyp51A, and integration and activation of transposon Atf1 in the cyp51A promoter. *Antimicrob Agents Chemother* **2011**; 55:5113–21.
335. Camps SM, Dutilh BE, Arendrup MC, et al. Discovery of a HapE mutation that causes azole resistance in *Aspergillus fumigatus* through whole genome sequencing and sexual crossing. *PLoS One* **2012**; 7:e50034.
336. Howard SJ, Arendrup MC. Acquired antifungal drug resistance in *Aspergillus fumigatus*: epidemiology and detection. *Med Mycol* **2011**; 49(suppl 1):S90–5.
337. Natesan SK, Lamichchane AK, Swaminathan S, Wu W. Differential expression of ATP-binding cassette and/or major facilitator superfamily class efflux pumps contributes to voriconazole resistance in *Aspergillus flavus*. *Diagn Microbiol Infect Dis* **2013**; 76:458–63.
338. Rajendran R, Mowat E, McCulloch E, et al. Azole resistance of *Aspergillus fumigatus* biofilms is partly associated with efflux pump activity. *Antimicrob Agents Chemother* **2011**; 55:2092–7.
339. Slaven JW, Anderson MJ, Sanglard D, et al. Increased expression of a novel *Aspergillus fumigatus* ABC transporter gene, atrF, in the presence of itraconazole in an itraconazole resistant clinical isolate. *Fungal Genet Biol* **2002**; 36:199–206.
340. Arendrup MC. Update on antifungal resistance in *Aspergillus* and *Candida*. *Clin Microbiol Infect* **2014**; 20(suppl 6):42–8.
341. Cuenca-Estrella M. Antifungal drug resistance mechanisms in pathogenic fungi: from bench to bedside. *Clin Microbiol Infect* **2014**; 20(suppl 6):54–9.
342. Alastruey-Izquierdo A, Mellado E, Pelaez T, et al. Population-based survey of filamentous fungi and antifungal resistance in Spain (FILPOP Study). *Antimicrob Agents Chemother* **2013**; 57:3380–7.
343. Baddley JW, Marr KA, Andes DR, et al. Patterns of susceptibility of *Aspergillus* isolates recovered from patients enrolled in the Transplant-Associated Infection Surveillance Network. *J Clin Microbiol* **2009**; 47:3271–5.
344. Mortensen KL, Mellado E, Lass-Flörl C, Rodriguez-Tudela JL, Johansen HK, Arendrup MC. Environmental study of azole-resistant *Aspergillus fumigatus* and other aspergilli in Austria, Denmark, and Spain. *Antimicrob Agents Chemother* **2010**; 54:4545–9.
345. Snelders E, van der Lee HA, Kuijpers J, et al. Emergence of azole resistance in *Aspergillus fumigatus* and spread of a single resistance mechanism. *PLoS Med* **2008**; 5:e219.
346. Howard SJ, Cerar D, Anderson MJ, et al. Frequency and evolution of azole resistance in *Aspergillus fumigatus* associated with treatment failure. *Emerg Infect Dis* **2009**; 15:1068–76.
347. van der Linden JW, Snelders E, Kampinga GA, et al. Clinical implications of azole resistance in *Aspergillus fumigatus*, The Netherlands, 2007–2009. *Emerg Infect Dis* **2011**; 17:1846–54.
348. Herbrecht R, Denning DW, Patterson TF, et al. Voriconazole versus amphotericin B for primary therapy of invasive aspergillosis. *N Engl J Med* **2002**; 347:408–15.
349. Maertens JA, Raad II, Marr KA, et al. Isavuconazole versus voriconazole for primary treatment of invasive mould disease caused by *Aspergillus* and other filamentous fungi (SECURE): a phase 3, randomised-controlled, non-inferiority trial. *Lancet* **2016**; 387:760–9.
350. Hachem RY, Boktour MR, Hanna HA, et al. Amphotericin B lipid complex versus liposomal amphotericin B monotherapy for invasive aspergillosis in patients with hematologic malignancy. *Cancer* **2008**; 112:1282–7.
351. Ito JI, Chandrasekar PH, Hooshmand-Rad R. Effectiveness of amphotericin B lipid complex (ABLC) treatment in allogeneic hematopoietic cell transplant (HCT) recipients with invasive aspergillosis (IA). *Bone Marrow Transplant* **2005**; 36:873–7.
352. Herbrecht R, Auvrignon A, Andres E, et al. Efficacy of amphotericin B lipid complex in the treatment of invasive fungal infections in immunosuppressed paediatric patients. *Eur J Clin Microbiol Infect Dis* **2001**; 20:77–82.
353. Linden P, Williams P, Chan KM. Efficacy and safety of amphotericin B lipid complex injection (ABLC) in solid-organ transplant recipients with invasive fungal infections. *Clin Transplant* **2000**; 14:329–39.
354. Kontoyannis DP, Hachem R, Lewis RE, et al. Efficacy and toxicity of caspofungin in combination with liposomal amphotericin B as primary or salvage treatment of invasive aspergillosis in patients with hematologic malignancies. *Cancer* **2003**; 98:292–9.
355. Aliff TB, Maslak PG, Jurcic JG, et al. Refractory *Aspergillus* pneumonia in patients with acute leukemia: successful therapy with combination caspofungin and liposomal amphotericin. *Cancer* **2003**; 97:1025–32.
356. Marr KA, Boeckh M, Carter RA, Kim HW, Corey L. Combination antifungal therapy for invasive aspergillosis. *Clin Infect Dis* **2004**; 39:797–802.
357. Kirkpatrick WR, Perea S, Coco BJ, Patterson TF. Efficacy of caspofungin alone and in combination with voriconazole in a guinea pig model of invasive aspergillosis. *Antimicrob Agents Chemother* **2002**; 46:2564–8.
358. Petraitis V, Petraitiene R, Sarafandi AA, et al. Combination therapy in treatment of experimental pulmonary aspergillosis: synergistic interaction between an antifungal triazole and an echinocandin. *J Infect Dis* **2003**; 187:1834–43.
359. Garbati MA, Alasmari FA, Al-Tannir MA, Tleyjeh IM. The role of combination antifungal therapy in the treatment of invasive aspergillosis: a systematic review. *Int J Infect Dis* **2012**; 16:e76–81.
360. Candoni A, Caira M, Cesaro S, et al. Multicentre surveillance study on feasibility, safety and efficacy of antifungal combination therapy for proven or probable invasive fungal diseases in haematological patients: the SEIFEM real-life combo study. *Mycoses* **2014**; 57:342–50.
361. Caillot D, Thiebaut A, Herbrecht R, et al. Liposomal amphotericin B in combination with caspofungin for invasive aspergillosis in patients with hematologic malignancies: a randomized pilot study (Combistrat trial). *Cancer* **2007**; 110:2740–6.
362. Marr KA, Schlamm HT, Herbrecht R, et al. Combination antifungal therapy for invasive aspergillosis: a randomized trial. *Ann Intern Med* **2015**; 162:81–9.
363. Dowell JA, Schranz J, Baruch A, Foster G. Safety and pharmacokinetics of co-administered voriconazole and anidulafungin. *J Clin Pharmacol* **2005**; 45:1373–82.
364. Jarque I, Tormo M, Bello JL, et al. Caspofungin for the treatment of invasive fungal disease in hematological patients (ProCAS Study). *Med Mycol* **2013**; 51:150–4.
365. Egerer G, Reichert D, Pletz MW, Kaskel P, Krobot KJ, Maertens J. Caspofungin for treatment of invasive aspergillosis in Germany: results of a pre-planned sub-analysis of an international registry. *Eur J Med Res* **2012**; 17:1–7.
366. Maertens J, Egerer G, Shin WS, et al. Caspofungin use in daily clinical practice for treatment of invasive aspergillosis: results of a prospective observational registry. *BMC Infect Dis* **2010**; 10:182.
367. Cordonnier C, Rovira M, Maertens J, et al. Voriconazole for secondary prophylaxis of invasive fungal infections in allogeneic stem cell transplant recipients: results of the VOSIFI study. *Haematologica* **2010**; 95:1762–8.
368. Liu Q, Lin R, Sun J, et al. Antifungal agents for secondary prophylaxis based on response to initial antifungal therapy in allogeneic hematopoietic stem cell transplant recipients with prior pulmonary aspergillosis. *Biol Blood Marrow Transplant* **2014**; 20:1198–203.
369. Kuderer NM, Dale DC, Crawford J, Lyman GH. Impact of primary prophylaxis with granulocyte colony-stimulating factor on febrile neutropenia and mortality in adult cancer patients receiving chemotherapy: a systematic review. *J Clin Oncol* **2007**; 25:3158–67.
370. Lyman GH, Dale DC, Wolff DA, et al. Acute myeloid leukemia or myelodysplastic syndrome in randomized controlled clinical trials of cancer chemotherapy with granulocyte colony-stimulating factor: a systematic review. *J Clin Oncol* **2010**; 28:2914–24.
371. Smith TJ, Khatcheressian J, Lyman GH, et al. 2006 update of recommendations for the use of white blood cell growth factors: an evidence-based clinical practice guideline. *J Clin Oncol* **2006**; 24:3187–205.
372. Crawford J, Armitage J, Balducci L, et al. Myeloid growth factors. *J Natl Compr Canc Netw* **2013**; 11:1266–90.
373. Brummer E, Maqbool A, Stevens DA. In vivo GM-CSF prevents dexamethasone suppression of killing of *Aspergillus fumigatus* conidia by bronchoalveolar macrophages. *J Leukoc Biol* **2001**; 70:868–72.
374. Sionov E, Segal E. Polyene and cytokine treatment of experimental aspergillosis. *FEMS Immunol Med Microbiol* **2003**; 39:221–7.
375. Sionov E, Mendlovic S, Segal E. Experimental systemic murine aspergillosis: treatment with polyene and caspofungin combination and G-CSF. *J Antimicrob Chemother* **2005**; 56:594–7.
376. Quezada G, Koshkina NV, Zweidler-McKay P, Zhou Z, Kontoyannis DP, Kleiner ES. Intranasal granulocyte-macrophage colony-stimulating factor reduces the *Aspergillus* burden in an immunosuppressed murine model of pulmonary aspergillosis. *Antimicrob Agents Chemother* **2008**; 52:716–8.

377. Bensing WI, Price TH, Dale DC, et al. The effects of daily recombinant human granulocyte colony-stimulating factor administration on normal granulocyte donors undergoing leukapheresis. *Blood* **1993**; 81:1883–8.
378. Hubel K, Carter RA, Liles WC, et al. Granulocyte transfusion therapy for infections in candidates and recipients of HPC transplantation: a comparative analysis of feasibility and outcome for community donors versus related donors. *Transfusion* **2002**; 42:1414–21.
379. Price TH, Bowden RA, Boeckh M, et al. Phase I/II trial of neutrophil transfusions from donors stimulated with G-CSF and dexamethasone for treatment of patients with infections in hematopoietic stem cell transplantation. *Blood* **2000**; 95:3302–9.
380. Price TH, Boeckh M, Harrison RW, et al. Efficacy of transfusion with granulocytes from G-CSF/dexamethasone treated donors in neutropenic patients with infection. *Blood* **2015**; 126:2153–61.
381. Martinez M, Chen V, Tong AJ, Hamilton K, Clemons KV, Stevens DA. Experimental evidence that granulocyte transfusions are efficacious in treatment of neutropenic hosts with pulmonary aspergillosis. *Antimicrob Agents Chemother* **2013**; 57:1882–7.
382. Wright DG, Robichaud KJ, Pizzo PA, Deisseroth AB. Lethal pulmonary reactions associated with the combined use of amphotericin B and leukocyte transfusions. *N Engl J Med* **1981**; 304:1185–9.
383. Smith NL, Denning DW. Clinical implications of interferon gamma genetic and epigenetic variants. *Immunology* **2014**; 143:499–511.
384. Hebart H, Bollinger C, Fisch P, et al. Analysis of T-cell responses to *Aspergillus fumigatus* antigens in healthy individuals and patients with hematologic malignancies. *Blood* **2002**; 100:4521–8.
385. A controlled trial of interferon gamma to prevent infection in chronic granulomatous disease. The International Chronic Granulomatous Disease Cooperative Study Group. *N Engl J Med* **1991**; 324:509–16.
386. Safdar A, Rodriguez G, Ohmagari N, et al. The safety of interferon-gamma-1b therapy for invasive fungal infections after hematopoietic stem cell transplantation. *Cancer* **2005**; 103:731–9.
387. Didier M, Guedin P, Staub F, et al. Pulmonary arterial mycotic pseudoaneurysms in a patient with invasive pulmonary aspergillosis. Successful occlusion by coils. *Am J Respir Crit Care Med* **2014**; 190:112–3.
388. Offner F, Cordonnier C, Ljungman P, et al. Impact of previous aspergillosis on the outcome of bone marrow transplantation. *Clin Infect Dis* **1998**; 26:1098–103.
389. Martino R, Parody R, Fukuda T, et al. Impact of the intensity of the pretransplantation conditioning regimen in patients with prior invasive aspergillosis undergoing allogeneic hematopoietic stem cell transplantation: a retrospective survey of the Infectious Diseases Working Party of the European Group for Blood and Marrow Transplantation. *Blood* **2006**; 108:2928–36.
390. El-Cheikh J, Castagna L, Wang L, et al. Impact of prior invasive aspergillosis on outcome in patients receiving reduced-intensity conditioning allogeneic hematopoietic stem cell transplant. *Leuk Lymphoma* **2010**; 51:1705–10.
391. Cordonnier C, Maury S, Pautas C, et al. Secondary antifungal prophylaxis with voriconazole to adhere to scheduled treatment in leukemic patients and stem cell transplant recipients. *Bone Marrow Transplant* **2004**; 33:943–8.
392. Almyroudis NG, Kontoyiannis DP, Sepkowitz KA, DePauw BE, Walsh TJ, Segal BH. Issues related to the design and interpretation of clinical trials of salvage therapy for invasive mold infection. *Clin Infect Dis* **2006**; 43:1449–55.
393. Bennett JE. Salvage therapy for aspergillosis. *Clin Infect Dis* **2005**; 41(suppl 6):S387–8.
394. Kontoyiannis DP, Lewis RE. Toward more effective antifungal therapy: the prospects of combination therapy. *Br J Haematol* **2004**; 126:165–75.
395. Ng TT, Denning DW. Liposomal amphotericin B (AmBisome) therapy in invasive fungal infections. Evaluation of United Kingdom compassionate use data. *Arch Intern Med* **1995**; 155:1093–8.
396. Walsh TJ, Hiemenz JW, Seibel NL, et al. Amphotericin B lipid complex for invasive fungal infections: analysis of safety and efficacy in 556 cases. *Clin Infect Dis* **1998**; 26:1383–96.
397. Perfect JR, Marr KA, Walsh TJ, et al. Voriconazole treatment for less-common, emerging, or refractory fungal infections. *Clin Infect Dis* **2003**; 36:1122–31.
398. Maertens J, Raad I, Petrikos G, et al. Efficacy and safety of caspofungin for treatment of invasive aspergillosis in patients refractory to or intolerant of conventional antifungal therapy. *Clin Infect Dis* **2004**; 39:1563–71.
399. Miceli MH, Graziutti ML, Woods G, et al. Strong correlation between serum aspergillus galactomannan index and outcome of aspergillosis in patients with hematological cancer: clinical and research implications. *Clin Infect Dis* **2008**; 46:1412–22.
400. Maertens J, Buve K, Theunissen K, et al. Galactomannan serves as a surrogate endpoint for outcome of pulmonary invasive aspergillosis in neutropenic hematology patients. *Cancer* **2009**; 115:355–62.
401. Park SH, Choi SM, Lee DG, et al. Serum galactomannan strongly correlates with outcome of invasive aspergillosis in acute leukaemia patients. *Mycoses* **2011**; 54:523–30.
402. Fisher CE, Stevens AM, Leisenring W, Pergam SA, Boeckh M, Hohl TM. The serum galactomannan index predicts mortality in hematopoietic stem cell transplant recipients with invasive aspergillosis. *Clin Infect Dis* **2013**; 57:1001–4.
403. Nouer SA, Nucci M, Kumar NS, Graziutti M, Barlogie B, Anaissie E. Earlier response assessment in invasive aspergillosis based on the kinetics of serum *Aspergillus* galactomannan: proposal for a new definition. *Clin Infect Dis* **2011**; 53:671–6.
404. Hadrich I, Makni F, Cheikhrouhou F, et al. Clinical utility and prognostic value of galactomannan in neutropenic patients with invasive aspergillosis. *Pathol Biol (Paris)* **2012**; 60:357–61.
405. Koo S, Bryar JM, Baden LR, Marty FM. Prognostic features of galactomannan antigenemia in galactomannan-positive invasive aspergillosis. *J Clin Microbiol* **2010**; 48:1255–60.
406. Russo A, Giuliano S, Vena A, et al. Predictors of mortality in non-neutropenic patients with invasive pulmonary aspergillosis: does galactomannan have a role? *Diagn Microbiol Infect Dis* **2014**; 80:83–6.
407. He H, Ding L, Chang S, Li F, Zhan Q. Value of consecutive galactomannan determinations for the diagnosis and prognosis of invasive pulmonary aspergillosis in critically ill chronic obstructive pulmonary disease. *Med Mycol* **2011**; 49:345–51.
408. He H, Li Q, Chang S, et al. Prognostic value of serum galactomannan index in critically ill patients with chronic obstructive pulmonary disease at risk of invasive pulmonary aspergillosis. *Chin Med J (Engl)* **2014**; 127:23–8.
409. Chai LY, Kullberg BJ, Johnson EM, et al. Early serum galactomannan trend as a predictor of outcome of invasive aspergillosis. *J Clin Microbiol* **2012**; 50:2330–6.
410. Chai LY, Kullberg BJ, Earnest A, et al. Voriconazole or amphotericin B as primary therapy yields distinct early serum galactomannan trends related to outcomes in invasive aspergillosis. *PLoS One* **2014**; 9:e90176.
411. Luong ML, Filion C, Labbe AC, et al. Clinical utility and prognostic value of bronchoalveolar lavage galactomannan in patients with hematologic malignancies. *Diagn Microbiol Infect Dis* **2010**; 68:132–9.
412. Koo S, Baden LR, Marty FM. Post-diagnostic kinetics of the (1 → 3)-β-D-glucan assay in invasive aspergillosis, invasive candidiasis and *Pneumocystis jirovecii* pneumonia. *Clin Microbiol Infect* **2012**; 18:e122–7.
413. Friberg LE, Ravva P, Karlsson MO, Liu P. Integrated population pharmacokinetic analysis of voriconazole in children, adolescents, and adults. *Antimicrob Agents Chemother* **2012**; 56:3032–42.
414. Walsh TJ, Driscoll T, Milligan PA, et al. Pharmacokinetics, safety, and tolerability of voriconazole in immunocompromised children. *Antimicrob Agents Chemother* **2010**; 54:4116–23.
415. Karlsson MO, Lutsar I, Milligan PA. Population pharmacokinetic analysis of voriconazole plasma concentration data from pediatric studies. *Antimicrob Agents Chemother* **2009**; 53:935–44.
416. Benjamin DKJ, Driscoll T, Seibel NL, et al. Safety and pharmacokinetics of intravenous anidulafungin in children with neutropenia at high risk for invasive fungal infections. *Antimicrob Agents Chemother* **2006**; 50:632–8.
417. Krenke R, Grabczak EM. Tracheobronchial manifestations of *Aspergillus* infections. *ScientificWorldJournal* **2011**; 11:2310–29.
418. Soubani AO, Chandrasekar PH. The clinical spectrum of pulmonary aspergillosis. *Chest* **2002**; 121:1988–99.
419. Denning DW, Stevens DA. Antifungal and surgical treatment of invasive aspergillosis: review of 2,121 published cases. *Rev Infect Dis* **1990**; 12:1147–201.
420. Kemper CA, Hostetler JS, Follansbee SE, et al. Ulcerative and plaque-like tracheobronchitis due to infection with *Aspergillus* in patients with AIDS. *Clin Infect Dis* **1993**; 17:344–52.
421. Boots RJ, Paterson DL, Allworth AM, Faoagali JL. Successful treatment of post-influenza pseudomembranous necrotising bronchial aspergillosis with liposomal amphotericin, inhaled amphotericin B, gamma interferon and GM-CSF. *Thorax* **1999**; 54:1047–9.
422. Adalja AA, Sappington PL, Harris SP, et al. Isolation of *Aspergillus* in three 2009 H1N1 influenza patients. *Influenza Other Respir Viruses* **2011**; 5:225–9.
423. Fernandez-Ruiz M, Silva JT, San-Juan R, et al. *Aspergillus* tracheobronchitis: report of 8 cases and review of the literature. *Medicine (Baltimore)* **2012**; 91:261–73.
424. Kramer MR, Denning DW, Marshall SE, et al. Ulcerative tracheobronchitis after lung transplantation. A new form of invasive aspergillosis. *Am Rev Respir Dis* **1991**; 144:552–6.
425. Husain S, Paterson DL, Studer S, et al. Voriconazole prophylaxis in lung transplant recipients. *Am J Transplant* **2006**; 6:3008–16.
426. Horvath J, Dummer S, Loyd J, Walker B, Merrill WH, Frist WH. Infection in the transplanted and native lung after single lung transplantation. *Chest* **1993**; 104:681–5.
427. Lin SJ, Schranz J, Teutsch SM. Aspergillosis case-fatality rate: systematic review of the literature. *Clin Infect Dis* **2001**; 32:358–66.

428. McCarthy M, Rosengart A, Schuetz AN, Kontoyiannis DP, Walsh TJ. Mold infections of the central nervous system. *N Engl J Med* **2014**; 371:150–60.
429. Viscoli C, Machetti M, Gazzola P, et al. *Aspergillus* galactomannan antigen in the cerebrospinal fluid of bone marrow transplant recipients with probable cerebral aspergillosis. *J Clin Microbiol* **2002**; 40:1496–9.
430. Mikulska M, Furfaro E, Del Bono V, et al. (1–3)-beta-D-glucan in cerebrospinal fluid is useful for the diagnosis of central nervous system fungal infections. *Clin Infect Dis* **2013**; 56:1511–2.
431. Tortorano AM, Esposito MC, Prigitano A, et al. Cross-reactivity of *Fusarium* spp. in the *Aspergillus* galactomannan enzyme-linked immunosorbent assay. *J Clin Microbiol* **2012**; 50:1051–3.
432. Schwartz S, Ruhnke M, Ribaud P, et al. Improved outcome in central nervous system aspergillosis, using voriconazole treatment. *Blood* **2005**; 106:2641–5.
433. Ng A, Gadong N, Kelsey A, Denning DW, Leggate J, Eden OB. Successful treatment of aspergillus brain abscess in a child with acute lymphoblastic leukemia. *Pediatr Hematol Oncol* **2000**; 17:497–504.
434. Khoury H, Adkins D, Miller G, Goodnough L, Brown R, DiPersio J. Resolution of invasive central nervous system aspergillosis in a transplant recipient. *Bone Marrow Transplant* **1997**; 20:179–80.
435. Coleman JM, Hogg GG, Rosenfeld JV, Waters KD. Invasive central nervous system aspergillosis: cure with liposomal amphotericin B, itraconazole, and radical surgery—case report and review of the literature. *Neurosurgery* **1995**; 36:858–63.
436. Pitisuttithum P, Negroni R, Graybill JR, et al. Activity of posaconazole in the treatment of central nervous system fungal infections. *J Antimicrob Chemother* **2005**; 56:745–55.
437. Imai T, Yamamoto T, Tanaka S, et al. Successful treatment of cerebral aspergillosis with a high oral dose of itraconazole after excisional surgery. *Intern Med* **1999**; 38:829–32.
438. Okugawa S, Ota Y, Tatsuno K, Tsukada K, Kishino S, Koike K. A case of invasive central nervous system aspergillosis treated with micafungin with monitoring of micafungin concentrations in the cerebrospinal fluid. *Scand J Infect Dis* **2007**; 39:344–6.
439. Stevens DA, Shatsky SA. Intrathecal amphotericin in the management of cocci-doidal meningitis. *Semin Respir Infect* **2001**; 16:263–9.
440. Dubbeld P, van Oostenbrugge RJ, Twinjstra A, Schouten HC. Spinal epidural abscess due to *Aspergillus* infection of the vertebrae: report of 3 cases. *Neth J Med* **1996**; 48:18–23.
441. Ng J, Ho S, Krishnan P, Teoh SC. *Aspergillus terreus* endogenous endophthalmitis in a nonimmunocompromised patient with a history of bronchiectasis. *Ocul Immunol Inflamm* **2013**; 21:231–3.
442. Georgala A, Laxeux B, Kwan J, et al. Inaugural bilateral *Aspergillus* endophthalmitis in a seriously immunocompromised patient. *Mycoses* **2011**; 54:e631–3.
443. Hoenigl M, Krause R. Antifungal therapy of aspergillosis of the central nervous system and *Aspergillus* endophthalmitis. *Curr Pharm Des* **2013**; 19:3648–68.
444. Shen YC, Wang CY, Tsai HY, Lee HN. Intracameral voriconazole injection in the treatment of fungal endophthalmitis resulting from keratitis. *Am J Ophthalmol* **2010**; 149:916–21.
445. Grosjean P, Weber R. Fungus balls of the paranasal sinuses: a review. *Eur Arch Otorhinolaryngol* **2007**; 264:461–70.
446. Popko M, Broglie MA, Holzmann D. Isolated fungus ball mimicking mucocele or frontal sinus tumour: a diagnostic pitfall. *J Laryngol Otol* **2010**; 124:1111–5.
447. Costa F, Polini F, Zerman N, Robiony M, Toro C, Politi M. Surgical treatment of *Aspergillus* mycetomas of the maxillary sinus: review of the literature. *Oral Surg Oral Med Oral Pathol Oral Radiol Endod* **2007**; 103:e23–9.
448. Karkas A, Rtail R, Rey E, Timi N, Righini CA. Sphenoid sinus fungus ball. *Eur Arch Otorhinolaryngol* **2013**; 270:893–8.
449. Mody KH, Ali MJ, Vemuganti GK, Nalamada S, Naik MN, Honavar SG. Orbital aspergillosis in immunocompetent patients. *Br J Ophthalmol* **2014**; 98:1379–84.
450. Chen CY, Sheng WH, Cheng A, et al. Invasive fungal sinusitis in patients with hematological malignancy: 15 years experience in a single university hospital in Taiwan. *BMC Infect Dis* **2011**; 11:250.
451. McCormack J, Pollard J. *Aspergillus* endocarditis 2003–2009. *Med Mycol* **2011**; 49(suppl 1):S30–4.
452. Riviere S, Lortholary O, Michon J, et al. *Aspergillus* endocarditis in the era of new antifungals: major role for antigen detection. *J Infect* **2013**; 67:85–8.
453. Ellis ME, Al-Abdely H, Sandridge A, Greer W, Ventura W. Fungal endocarditis: evidence in the world literature, 1965–1995. *Clin Infect Dis* **2001**; 32:50–62.
454. Gumbo T, Taeye AJ, Mawhorter S, et al. *Aspergillus* valve endocarditis in patients without prior cardiac surgery. *Medicine (Baltimore)* **2000**; 79:261–8.
455. Reis LJ, Barton TD, Pochettino A, et al. Successful treatment of *Aspergillus* prosthetic valve endocarditis with oral voriconazole. *Clin Infect Dis* **2005**; 41:752–3.
456. Martin MV, Yates J, Hitchcock CA. Comparison of voriconazole (UK-109,496) and itraconazole in prevention and treatment of *Aspergillus fumigatus* endocarditis in guinea pigs. *Antimicrob Agents Chemother* **1997**; 41:13–6.
457. Walsh TJ, Bulkley BH. *Aspergillus* pericarditis: clinical and pathologic features in the immunocompromised patient. *Cancer* **1982**; 49:48–54.
458. Le Moing V, Lortholary O, Timsit JF, et al. *Aspergillus* pericarditis with tamponade: report of a successfully treated case and review. *Clin Infect Dis* **1998**; 26:451–60.
459. Rueter F, Hirsch HH, Kunz F, et al. Late *Aspergillus fumigatus* endomyocarditis with brain abscess as a lethal complication after heart transplantation. *J Heart Lung Transplant* **2002**; 21:1242–5.
460. Studemeister A, Stevens DA. *Aspergillus* vertebral osteomyelitis in immunocompetent hosts: role of triazole antifungal therapy. *Clin Infect Dis* **2011**; 52:e1–6.
461. Gamaletsou MN, Rammaert B, Bueno MA, et al. *Aspergillus* osteomyelitis: epidemiology, clinical manifestations, management, and outcome. *J Infect* **2014**; 68:478–93.
462. Vinas FC, King PK, Diaz FG. Spinal *Aspergillus* osteomyelitis. *Clin Infect Dis* **1999**; 28:1223–9.
463. Mouas H, Lutsar I, Dupont B, et al. Voriconazole for invasive bone aspergillosis: a worldwide experience of 20 cases. *Clin Infect Dis* **2005**; 40:1141–7.
464. Stratov I, Korman TM, Johnson PD. Management of *Aspergillus* osteomyelitis: report of failure of liposomal amphotericin B and response to voriconazole in an immunocompetent host and literature review. *Eur J Clin Microbiol Infect Dis* **2003**; 22:277–83.
465. Hodiament CJ, Dolman KM, Ten Berge IJ, Melchers WJ, Verweij PE, Pajkrt D. Multiple-azole-resistant *Aspergillus fumigatus* osteomyelitis in a patient with chronic granulomatous disease successfully treated with long-term oral posaconazole and surgery. *Med Mycol* **2009**; 47:217–20.
466. Kumashi PR, Safdar A, Chamilos G, Chemaly RF, Raad II, Kontoyiannis DP. Fungal osteoarticular infections in patients treated at a comprehensive cancer centre: a 10-year retrospective review. *Clin Microbiol Infect* **2006**; 12:621–6.
467. Kirby A, Hassan I, Burnie J. Recommendations for managing *Aspergillus* osteomyelitis and joint infections based on a review of the literature. *J Infect* **2006**; 52:405–14.
468. Koehler P, Tacke D, Cornely OA. Aspergillosis of bones and joints—a review from 2002 until today. *Mycoses* **2014**; 57:323–35.
469. McCarty JM, Flam MS, Pullen G, Jones R, Kassel SH. Outbreak of primary cutaneous aspergillosis related to intravenous arm boards. *J Pediatr* **1986**; 108:721–4.
470. Bretagne S, Bart-Delabesse E, Wechsler J, Kuentz M, Dhedin N, Cordonnier C. Fatal primary cutaneous aspergillosis in a bone marrow transplant recipient: nosocomial acquisition in a laminar-air flow room. *J Hosp Infect* **1997**; 36:235–9.
471. Walsh TJ. Primary cutaneous aspergillosis—an emerging infection among immunocompromised patients. *Clin Infect Dis* **1998**; 27:453–7.
472. Eldridge ML, Chambers CJ, Sharon VR, Thompson GR 3rd. Fungal infections of the skin and nail: new treatment options. *Expert Rev Anti Infect Ther* **2014**; 12:1389–405.
473. Nannini EC, Paphitou NI, Ostrosky-Zeichner L. Peritonitis due to *Aspergillus* and zygomycetes in patients undergoing peritoneal dialysis: report of 2 cases and review of the literature. *Diagn Microbiol Infect Dis* **2003**; 46:49–54.
474. Manzano-Gayosso P, Hernandez-Hernandez F, Mendez-Tovar LJ, Gonzalez-Monroy J, Lopez-Martinez R. Fungal peritonitis in 15 patients on continuous ambulatory peritoneal dialysis (CAPD). *Mycoses* **2003**; 46:425–9.
475. Ates O, Metan G, Dundar T, et al. Diagnosis of *Aspergillus niger* peritonitis in a peritoneal dialysis patient by peritoneal galactomannan and beta-D-glucan detection. *Perit Dial Int* **2013**; 33:216–8.
476. Indramohan P, Rohit A, Kanchanamala M, Mathew M, Abraham G. Culture-negative *Aspergillus* peritonitis diagnosed by peritoneal biopsy. *Perit Dial Int* **2013**; 33:464–5.
477. Matuszkiewicz-Rowinska J. Update on fungal peritonitis and its treatment. *Perit Dial Int* **2009**; 29(suppl 2):S161–5.
478. van der Voort PH, Boerma EC, Yska JP. Serum and intraperitoneal levels of amphotericin B and flucytosine during intravenous treatment of critically ill patients with *Candida* peritonitis. *J Antimicrob Chemother* **2007**; 59:952–6.
479. Weiler S, Bellmann-Weiler R, Duzendorfer S, Joannidis M, Bellmann R. Levels of amphotericin B lipid formulations in ascites. *J Antimicrob Chemother* **2008**; 62:1163–4.
480. Peng LW, Lien YH. Pharmacokinetics of single, oral-dose voriconazole in peritoneal dialysis patients. *Am J Kidney Dis* **2005**; 45:162–6.
481. Ulusoy S, Ozkan G, Tosun I, et al. Peritonitis due to *Aspergillus nidulans* and its effective treatment with voriconazole: the first case report. *Perit Dial Int* **2011**; 31:212–3.
482. Li PK, Szeto CC, Piraino B, et al. Peritoneal dialysis-related infections recommendations: 2010 update. *Perit Dial Int* **2010**; 30:393–423.
483. Young RC, Bennett JE, Vogel CL, Carbone PP, DeVita VT. Aspergillosis. The spectrum of the disease in 98 patients. *Medicine (Baltimore)* **1970**; 49:147–73.
484. Meyer RD, Young LS, Armstrong D, Yu B. Aspergillosis complicating neoplastic disease. *Am J Med* **1973**; 54:6–15.
485. Eggimann P, Chevrolet JC, Starobinski M, et al. Primary invasive aspergillosis of the digestive tract: report of two cases and review of the literature. *Infection* **2006**; 34:333–8.

486. Kazan E, Maertens J, Herbrecht R, et al. A retrospective series of gut aspergillosis in haematology patients. *Clin Microbiol Infect* **2011**; 17:588–94.
487. van der Velden WJ, Blijlevens NM, Klont RR, Donnelly JP, Verweij PE. Primary hepatic invasive aspergillosis with progression after rituximab therapy for a post transplantation lymphoproliferative disorder. *Ann Hematol* **2006**; 85:621–3.
488. Erdman SH, Barber BJ, Barton LL. *Aspergillus* cholangitis: a late complication after Kasai portoenterostomy. *J Pediatr Surg* **2002**; 37:923–5.
489. Lisson SW, Hellinger WC, Parra RO. Primary bilateral parenchymal renal *Aspergillus* infection. *Urology* **2002**; 60:345.
490. Khan ZU, Gopalakrishnan G, al-Awadi K, et al. Renal aspergilloma due to *Aspergillus flavus*. *Clin Infect Dis* **1995**; 21:210–2.
491. Waller S, Raglow Z, Lemons S, et al. Microwave ablation of a large renal aspergilloma. *Transpl Infect Dis* **2014**; 16:496–500.
492. Kauffman CA. Diagnosis and management of fungal urinary tract infection. *Infect Dis Clin North Am* **2014**; 28:61–74.
493. Martinez-Pajares JD, Martinez-Ferriz MC, Moreno-Perez D, Garcia-Ramirez M, Martin-Carballido S, Blanch-Iribarne P. Management of obstructive renal failure caused by bilateral renal aspergilloma in an immunocompetent newborn. *J Med Microbiol* **2010**; 59:367–9.
494. Ho T, Vrabec JT, Yoo D, Coker NJ. Otorrhoea: clinical features and treatment implications. *Otolaryngol Head Neck Surg* **2006**; 135:787–91.
495. Munguia R, Daniel SJ. Otopical antifungals and otorrhoea: a review. *Int J Pediatr Otorhinolaryngol* **2008**; 72:453–9.
496. Bhatt YM, Pahade N, Nair B. *Aspergillus* petrous apicitis associated with cerebral and peritubular abscesses in an immunocompetent man. *J Laryngol Otol* **2013**; 127:404–7.
497. Gordon G, Giddings NA. Invasive otitis externa due to *Aspergillus* species: case report and review. *Clin Infect Dis* **1994**; 19:866–70.
498. Parize P, Chandresris MO, Lanternier F, et al. Antifungal therapy of *Aspergillus* invasive otitis externa: efficacy of voriconazole and review. *Antimicrob Agents Chemother* **2009**; 53:1048–53.
499. Thurtell MJ, Chiu AL, Goold LA, et al. Neuro-ophthalmology of invasive fungal sinusitis: 14 consecutive patients and a review of the literature. *Clin Experiment Ophthalmol* **2013**; 41:567–76.
500. Vennewald I, Klemm E. Otorrhoea: diagnosis and treatment. *Clin Dermatol* **2010**; 28:202–11.
501. Prajna VN, Lalitha PS, Mascarenhas J, et al. Natamycin and voriconazole in *Fusarium* and *Aspergillus* keratitis: subgroup analysis of a randomised controlled trial. *Br J Ophthalmol* **2012**; 96:1440–1.
502. Prajna NV, Krishnan T, Mascarenhas J, et al. The mycotic ulcer treatment trial: a randomized trial comparing natamycin vs voriconazole. *JAMA Ophthalmol* **2013**; 131:422–9.
503. Arora R, Gupta D, Goyal J, Kaur R. Voriconazole versus natamycin as primary treatment in fungal corneal ulcers. *Clin Experiment Ophthalmol* **2011**; 39:434–40.
504. Parchand S, Gupta A, Ram J, Gupta N, Chakrabarty A. Voriconazole for fungal corneal ulcers. *Ophthalmology* **2012**; 119:1083.
505. Thomas PA, Kaliyamurthy J. Mycotic keratitis: epidemiology, diagnosis and management. *Clin Microbiol Infect* **2013**; 19:210–20.
506. Shi W, Wang T, Xie L, et al. Risk factors, clinical features, and outcomes of recurrent fungal keratitis after corneal transplantation. *Ophthalmology* **2010**; 117:890–6.
507. Karnak D, Avery RK, Gildea TR, Sahoo D, Mehta AC. Endobronchial fungal disease: an under-recognized entity. *Respiration* **2007**; 74:88–104.
508. Chrdle A, Mustakim S, Bright-Thomas RJ, Baxter CG, Felton T, Denning DW. *Aspergillus* bronchitis without significant immunocompromise. *Ann N Y Acad Sci* **2012**; 1272:73–85.
509. Armstead J, Morris J, Denning DW. Multi-country estimate of different manifestations of aspergillosis in cystic fibrosis. *PLoS One* **2014**; 9:e98502.
510. Shoseyov D, Brownlee KG, Conway SP, Kerem E. *Aspergillus* bronchitis in cystic fibrosis. *Chest* **2006**; 130:222–6.
511. Wald A, Leisenring W, van Burik JA, Bowden RA. Epidemiology of *Aspergillus* infections in a large cohort of patients undergoing bone marrow transplantation. *J Infect Dis* **1997**; 175:1459–66.
512. Fukuda T, Boeckh M, Guthrie KA, et al. Invasive aspergillosis before allogeneic hematopoietic stem cell transplantation: 10-year experience at a single transplant center. *Biol Blood Marrow Transplant* **2004**; 10:494–503.
513. Wingard JR, Carter SL, Walsh TJ, et al. Randomized, double-blind trial of fluconazole versus voriconazole for prevention of invasive fungal infection after allogeneic hematopoietic cell transplantation. *Blood* **2010**; 116:5111–8.
514. Chabrol A, Cuzin L, Huguot F, et al. Prophylaxis of invasive aspergillosis with voriconazole or caspofungin during building work in patients with acute leukaemia. *Haematologica* **2010**; 95:996–1003.
515. Molina JR, Serrano J, Sanchez-Garcia J, et al. Voriconazole as primary antifungal prophylaxis in children undergoing allo-SCT. *Bone Marrow Transplant* **2012**; 47:562–7.
516. Peksa GD, Schultz K, Fung HC. Dosing algorithm for concomitant administration of sirolimus, tacrolimus, and an azole after allogeneic hematopoietic stem cell transplantation. *J Oncol Pharm Pract* **2015**; 21:409–15.
517. Siwek GT, Dodgson KJ, de Magalhaes-Silverman M, et al. Invasive zygomycosis in hematopoietic stem cell transplant recipients receiving voriconazole prophylaxis. *Clin Infect Dis* **2004**; 39:584–7.
518. Tong SY, Peleg AY, Yoong J, Handke R, Szer J, Slavin M. Breakthrough *Scedosporium* proliferans infection while receiving voriconazole prophylaxis in an allogeneic stem cell transplant recipient. *Transpl Infect Dis* **2007**; 9:241–3.
519. van Burik JA, Ratanatharathorn V, Stepan DE, et al. Micafungin versus fluconazole for prophylaxis against invasive fungal infections during neutropenia in patients undergoing hematopoietic stem cell transplantation. *Clin Infect Dis* **2004**; 39:1407–16.
520. Cattaneo C, Monte S, Algarotti A, et al. A randomized comparison of caspofungin versus antifungal prophylaxis according to investigator policy in acute leukaemia patients undergoing induction chemotherapy (PROFIL-C study). *J Antimicrob Chemother* **2011**; 66:2140–5.
521. Chou LS, Lewis RE, Ippoliti C, Champlin RE, Kontoyiannis DP. Caspofungin as primary antifungal prophylaxis in stem cell transplant recipients. *Pharmacotherapy* **2007**; 27:1644–50.
522. de Fabritiis P, Spagnoli A, Di Bartolomeo P, et al. Efficacy of caspofungin as secondary prophylaxis in patients undergoing allogeneic stem cell transplantation with prior pulmonary and/or systemic fungal infection. *Bone Marrow Transplant* **2007**; 40:245–9.
523. Mattiuzzi GN, Alvarado G, Giles FJ, et al. Open-label, randomized comparison of itraconazole versus caspofungin for prophylaxis in patients with hematologic malignancies. *Antimicrob Agents Chemother* **2006**; 50:143–7.
524. Bow EJ, Laverdiere M, Lussier N, Rotstein C, Cheang MS, Ioannou S. Antifungal prophylaxis for severely neutropenic chemotherapy recipients: a meta-analysis of randomized-controlled clinical trials. *Cancer* **2002**; 94:3230–46.
525. Morgenstern GR, Prentice AG, Prentice HG, Ropner JE, Schey SA, Warnock DW. A randomized controlled trial of itraconazole versus fluconazole for the prevention of fungal infections in patients with haematological malignancies. U.K. Multicentre Antifungal Prophylaxis Study Group. *Br J Haematol* **1999**; 105:901–11.
526. Harousseau JL, Dekker AW, Stamatoullas-Bastard A, et al. Itraconazole oral solution for primary prophylaxis of fungal infections in patients with hematological malignancy and profound neutropenia: a randomized, double-blind, double-placebo, multicenter trial comparing itraconazole and amphotericin B. *Antimicrob Agents Chemother* **2000**; 44:1887–93.
527. Nucci M, Biasoli I, Akiti T, et al. A double-blind, randomized, placebo-controlled trial of itraconazole capsules as antifungal prophylaxis for neutropenic patients. *Clin Infect Dis* **2000**; 30:300–5.
528. Winston DJ, Maziarz RT, Chandrasekar PH, et al. Intravenous and oral itraconazole versus intravenous and oral fluconazole for long-term antifungal prophylaxis in allogeneic hematopoietic stem-cell transplant recipients. A multicenter, randomized trial. *Ann Intern Med* **2003**; 138:705–13.
529. Marr KA, Crippa F, Leisenring W, et al. Itraconazole versus fluconazole for prevention of fungal infections in patients receiving allogeneic stem cell transplants. *Blood* **2004**; 103:1527–33.
530. Vardakas KZ, Michalopoulos A, Falagas ME. Fluconazole versus itraconazole for antifungal prophylaxis in neutropenic patients with haematological malignancies: a meta-analysis of randomised-controlled trials. *Br J Haematol* **2005**; 131:22–8.
531. Glasmacher A, Prentice A, Gorschluter M, et al. Itraconazole prevents invasive fungal infections in neutropenic patients treated for hematologic malignancies: evidence from a meta-analysis of 3,597 patients. *J Clin Oncol* **2003**; 21:4615–26.
532. Rousey SR, Russler S, Gottlieb M, Ash RC. Low-dose amphotericin B prophylaxis against invasive *Aspergillus* infections in allogeneic marrow transplantation. *Am J Med* **1991**; 91:484–92.
533. De Laurenzi A, Matteocci A, Lanti A, Pescador L, Blandino F, Papetti C. Amphotericin B prophylaxis against invasive fungal infections in neutropenic patients: a single center experience from 1980 to 1995. *Infection* **1996**; 24:361–6.
534. Perfect JR, Klotman ME, Gilbert CC, et al. Prophylactic intravenous amphotericin B in neutropenic autologous bone marrow transplant recipients. *J Infect Dis* **1992**; 165:891–7.
535. Gergis U, Markey K, Greene J, et al. Voriconazole provides effective prophylaxis for invasive fungal infection in patients receiving glucocorticoid therapy for GVHD. *Bone Marrow Transplant* **2010**; 45:662–7.
536. Amigues I, Cohen N, Chung D, et al. Hepatic safety of voriconazole after allogeneic hematopoietic stem cell transplantation. *Biol Blood Marrow Transplant* **2010**; 16:46–52.
537. Grigg AP, Brown M, Roberts AW, Szer J, Slavin MA. A pilot study of targeted itraconazole prophylaxis in patients with graft-versus-host disease at high risk

- of invasive mould infections following allogeneic stem cell transplantation. *Bone Marrow Transplant* **2004**; 34:447–53.
538. Neoh CF, Snell GI, Kotsimbos T, et al. Antifungal prophylaxis in lung transplantation—a world-wide survey. *Am J Transplant* **2011**; 11:361–6.
539. Schaefer JM. Is universal antifungal prophylaxis mandatory in lung transplant patients? *Curr Opin Infect Dis* **2013**; 26:317–25.
540. Drew RH, Dodds Ashley E, Benjamin DK Jr, Duane Davis R, Palmer SM, Perfect JR. Comparative safety of amphotericin B lipid complex and amphotericin B deoxycholate as aerosolized antifungal prophylaxis in lung-transplant recipients. *Transplantation* **2004**; 77:232–7.
541. Shitrit D, Ollech JE, Ollech A, et al. Itraconazole prophylaxis in lung transplant recipients receiving tacrolimus (FK 506): efficacy and drug interaction. *J Heart Lung Transplant* **2005**; 24:2148–52.
542. Cadena J, Levine DJ, Angel LF, et al. Antifungal prophylaxis with voriconazole or itraconazole in lung transplant recipients: hepatotoxicity and effectiveness. *Am J Transplant* **2009**; 9:2085–91.
543. Bhaskaran A, Mumtaz K, Husain S. Anti-*Aspergillus* prophylaxis in lung transplantation: a systematic review and meta-analysis. *Curr Infect Dis Rep* **2013**; 15:514–25.
544. Palmer SM, Drew RH, Whitehouse JD, et al. Safety of aerosolized amphotericin B lipid complex in lung transplant recipients. *Transplantation* **2001**; 72:545–8.
545. Lowry CM, Marty FM, Vargas SO, et al. Safety of aerosolized liposomal versus deoxycholate amphotericin B formulations for prevention of invasive fungal infections following lung transplantation: a retrospective study. *Transpl Infect Dis* **2007**; 9:121–5.
546. Monforte V, Lopez-Sanchez A, Zurbano F, et al. Prophylaxis with nebulized liposomal amphotericin B for *Aspergillus* infection in lung transplant patients does not cause changes in the lipid content of pulmonary surfactant. *J Heart Lung Transplant* **2013**; 32:313–9.
547. Hosseini-Moghaddam SM, Husain S. Fungi and molds following lung transplantation. *Semin Respir Crit Care Med* **2010**; 31:222–33.
548. Helmi M, Love RB, Welter D, Cornwell RD, Meyer KC. *Aspergillus* infection in lung transplant recipients with cystic fibrosis: risk factors and outcomes comparison to other types of transplant recipients. *Chest* **2003**; 123:800–8.
549. Nunley DR, Ohori P, Grgurich WF, et al. Pulmonary aspergillosis in cystic fibrosis lung transplant recipients. *Chest* **1998**; 114:1321–9.
550. Vadnerkar A, Clancy CJ, Celik U, et al. Impact of mold infections in explanted lungs on outcomes of lung transplantation. *Transplantation* **2010**; 89:253–60.
551. Singh N, Husain S. *Aspergillus* infections after lung transplantation: clinical differences in type of transplant and implications for management. *J Heart Lung Transplant* **2003**; 22:258–66.
552. Steinbach WJ, Marr KA, Anaissie EJ, et al. Clinical epidemiology of 960 patients with invasive aspergillosis from the PATH Alliance registry. *J Infect* **2012**; 65:453–64.
553. Paterson DL, Singh N. Invasive aspergillosis in transplant recipients. *Medicine* **1999**; 78:123–38.
554. Gavalda J, Len O, San Juan R, et al. Risk factors for invasive aspergillosis in solid-organ transplant recipients: a case-control study. *Clin Infect Dis* **2005**; 41:52–9.
555. Singh N, Arnow PM, Bonham A, et al. Invasive aspergillosis in liver transplant recipients in the 1990s. *Transplantation* **1997**; 64:716–20.
556. Brown RS Jr, Lake JR, Katzman BA, et al. Incidence and significance of *Aspergillus* cultures following liver and kidney transplantation. *Transplantation* **1996**; 61:666–9.
557. Singh N, Paterson DL. *Aspergillus* infections in transplant recipients. *Clin Microbiol Rev* **2005**; 18:44–69.
558. Hayes D Jr, Ball AM, Mansour HM, Martin CA, Flynn JD. Fungal infection in heart-lung transplant recipients receiving single-agent prophylaxis with itraconazole. *Exp Clin Transplant* **2011**; 9:399–404.
559. Munoz P, Rodriguez C, Bouza E, et al. Risk factors of invasive aspergillosis after heart transplantation: protective role of oral itraconazole prophylaxis. *Am J Transplant* **2004**; 4:636–43.
560. Cofan F, Ricart MJ, Oppenheimer F, et al. Study of kidney rejection following simultaneous kidney-pancreas transplantation. *Nephron* **1996**; 74:58–63.
561. Weiland D, Ferguson RM, Peterson PK, Snover DC, Simmons RL, Najarian JS. Aspergillosis in 25 renal transplant patients. Epidemiology, clinical presentation, diagnosis, and management. *Ann Surg* **1983**; 198:622–9.
562. Fishman JA, Gonzalez RG, Branda JA. Case records of the Massachusetts General Hospital. Case 11-2008. A 45-year-old man with changes in mental status after liver transplantation. *N Engl J Med* **2008**; 358:1604–13.
563. Collins LA, Samore MH, Roberts MS, et al. Risk factors for invasive fungal infections complicating orthotopic liver transplantation. *J Infect Dis* **1994**; 170:644–52.
564. Karchmer AW, Samore MH, Hadley S, Collins LA, Jenkins RL, Lewis WD. Fungal infections complicating orthotopic liver transplantation. *Trans Am Clin Climatol Assoc* **1995**; 106:38–47; discussion 48.
565. George MJ, Snyderman DR, Werner BG, et al. The independent role of cytomegalovirus as a risk factor for invasive fungal disease in orthotopic liver transplant recipients. Boston Center for Liver Transplantation CMVIG-Study Group. *Cytogam*. MedImmune, Inc. Gaithersburg, Maryland. *Am J Med* **1997**; 103:106–13.
566. Briegel J, Forst H, Spill B, et al. Risk factors for systemic fungal infections in liver transplant recipients. *Eur J Clin Microbiol Infect Dis* **1995**; 14:375–82.
567. Playford EG, Webster AC, Sorrell TC, Craig JC. Antifungal agents for preventing fungal infections in solid organ transplant recipients. *Cochrane Database Syst Rev* **2004**; CD004291.
568. Playford EG, Webster AC, Sorrell TC, Craig JC. Systematic review and meta-analysis of antifungal agents for preventing fungal infections in liver transplant recipients. *Eur J Clin Microbiol Infect Dis* **2006**; 25:549–61.
569. Giannella M, Ercolani G, Cristini F, et al. High-dose weekly liposomal amphotericin b antifungal prophylaxis in patients undergoing liver transplantation: a prospective phase II trial. *Transplantation* **2015**; 99:848–54.
570. Sun HY, Cacciarelli TV, Singh N. Micafungin versus amphotericin B lipid complex for the prevention of invasive fungal infections in high-risk liver transplant recipients. *Transplantation* **2013**; 96:573–8.
571. Sipsas NV, Kontoyiannis DP. Clinical issues regarding relapsing aspergillosis and the efficacy of secondary antifungal prophylaxis in patients with hematological malignancies. *Clin Infect Dis* **2006**; 42:1584–91.
572. Chamilos G, Marom EM, Lewis RE, Lionakis MS, Kontoyiannis DP. Predictors of pulmonary zygomycosis versus invasive pulmonary aspergillosis in patients with cancer. *Clin Infect Dis* **2005**; 41:60–6.
573. Heinz WJ, Egerer G, Lellek H, Boehme A, Greiner J. Posaconazole after previous antifungal therapy with voriconazole for therapy of invasive *Aspergillus* disease, a retrospective analysis. *Mycoses* **2013**; 56:304–10.
574. Warris A, Weemaes CM, Verweij PE. Multidrug resistance in *Aspergillus fumigatus*. *N Engl J Med* **2002**; 347:2173–4.
575. Georgiadou SP, Kontoyiannis DP. Concurrent lung infections in patients with hematological malignancies and invasive pulmonary aspergillosis: how firm is the *Aspergillus* diagnosis? *J Infect* **2012**; 65:262–8.
576. Fisher CE, Stevens AM, Leisenring W, Pergam SA, Boeckh M, Hohl TM. Independent contribution of bronchoalveolar lavage and serum galactomannan in the diagnosis of invasive pulmonary aspergillosis. *Transpl Infect Dis* **2014**; 16:505–10.
577. Freifeld AG, Bow EJ, Sepkowitz KA, et al. Clinical practice guideline for the use of antimicrobial agents in neutropenic patients with cancer: 2010 update by the Infectious Diseases Society of America. *Clin Infect Dis* **2011**; 52:e56–93.
578. Pizzo PA, Robichaud KJ, Gill FA, Witebsky FG. Empiric antibiotic and antifungal therapy for cancer patients with prolonged fever and granulocytopenia. *Am J Med* **1982**; 72:101–11.
579. Empiric antifungal therapy in febrile granulocytopenic patients. EORTC International Antimicrobial Therapy Cooperative Group. *Am J Med* **1989**; 86:668–72.
580. Walsh TJ, Finberg RW, Arndt C, et al. Liposomal amphotericin B for empirical therapy in patients with persistent fever and neutropenia. National Institute of Allergy and Infectious Diseases Mycoses Study Group. *N Engl J Med* **1999**; 340:764–71.
581. Boogaerts M, Winston DJ, Bow EJ, et al. Intravenous and oral itraconazole versus intravenous amphotericin B deoxycholate as empirical antifungal therapy for persistent fever in neutropenic patients with cancer who are receiving broad-spectrum antibacterial therapy. A randomized, controlled trial. *Ann Intern Med* **2001**; 135:412–22.
582. Walsh TJ, Teppler H, Donowitz GR, et al. Caspofungin versus liposomal amphotericin B for empirical antifungal therapy in patients with persistent fever and neutropenia. *N Engl J Med* **2004**; 351:1391–402.
583. Walsh TJ, Pappas P, Winston DJ, et al. Voriconazole compared with liposomal amphotericin B for empirical antifungal therapy in patients with neutropenia and persistent fever. *N Engl J Med* **2002**; 346:225–34.
584. Caselli D, Cesaro S, Ziino O, et al. A prospective, randomized study of empirical antifungal therapy for the treatment of chemotherapy-induced febrile neutropenia in children. *Br J Haematol* **2012**; 158:249–55.
585. Maschmeyer G, Heinz WJ, Hertenstein B, et al. Immediate versus deferred empirical antifungal (IDEA) therapy in high-risk patients with febrile neutropenia: a randomized, double-blind, placebo-controlled, multicenter study. *Eur J Clin Microbiol Infect Dis* **2013**; 32:679–89.
586. Malhotra P, Makkak A, Guru Murthy GS, Varma N, Varma S, Chakrabarti A. Empirical amphotericin B therapy on day 4 or day 8 of febrile neutropenia. *Mycoses* **2014**; 57:110–5.
587. Hebart H, Klingspor L, Klingebiel T, et al. A prospective randomized controlled trial comparing PCR-based and empirical treatment with liposomal amphotericin B in patients after allo-SCT. *Bone Marrow Transplant* **2009**; 43:553–61.
588. Blennow O, Remberger M, Klingspor L, et al. Randomized PCR-based therapy and risk factors for invasive fungal infection following reduced-intensity conditioning and hematopoietic SCT. *Bone Marrow Transplant* **2010**; 45:1710–8.

589. Cordonnier C, Pautas C, Maury S, et al. Empirical versus preemptive antifungal therapy for high-risk, febrile, neutropenic patients: a randomized, controlled trial. *Clin Infect Dis* **2009**; 48:1042–51.
590. Tan BH, Low JG, Chlebicka NL, et al. Galactomannan-guided preemptive vs. empirical antifungals in the persistently febrile neutropenic patient: a prospective randomized study. *Int J Infect Dis* **2011**; 15:e350–6.
591. White PL, Mengoli C, Bretagne S, et al. Evaluation of *Aspergillus* PCR protocols for testing serum specimens. *J Clin Microbiol* **2011**; 49:3842–8.
592. Loeffler J, Barnes R, Donnelly JP; European Aspergillus PCR Initiative. Standardization of *Aspergillus* PCR diagnosis. *Bone Marrow Transplant* **2012**; 47:299–300.
593. White PL, Wingard JR, Bretagne S, et al. *Aspergillus* polymerase chain reaction: systematic review of evidence for clinical use in comparison with antigen testing. *Clin Infect Dis* **2015**; 61:1293–303.
594. Segal BH, Almyroudis NG, Battiwalla M, et al. Prevention and early treatment of invasive fungal infection in patients with cancer and neutropenia and in stem cell transplant recipients in the era of newer broad-spectrum antifungal agents and diagnostic adjuncts. *Clin Infect Dis* **2007**; 44:402–9.
595. Cahill BC, Hibbs JR, Savik K, et al. *Aspergillus* airway colonization and invasive disease after lung transplantation. *Chest* **1997**; 112:1160–4.
596. Iversen M, Burton CM, Vand S, et al. *Aspergillus* infection in lung transplant patients: incidence and prognosis. *Eur J Clin Microbiol Infect Dis* **2007**; 26:879–86.
597. Weigt SS, Copeland CA, Derhovanessian A, et al. Colonization with small conidia *Aspergillus* species is associated with bronchiolitis obliterans syndrome: a two-center validation study. *Am J Transplant* **2013**; 13:919–27.
598. Neoh CF, Snell GI, Levvey B, et al. Preemptive treatment with voriconazole in lung transplant recipients. *Transpl Infect Dis* **2013**; 15:344–53.
599. Westney GE, Kesten S, De Hoyos A, Chapparro C, Winton T, Maurer JR. *Aspergillus* infection in single and double lung transplant recipients. *Transplantation* **1996**; 61:915–9.
600. Hosseini-Moghaddam SM, Chaparro C, Luong ML, et al. The effectiveness of culture-directed preemptive anti-*Aspergillus* treatment in lung transplant recipients at one year after transplant. *Transplantation* **2015**; 99:2387–93.
601. Denning DW, Riniotis K, Dobrashian R, Sambatakou H. Chronic cavitary and fibrosing pulmonary and pleural aspergillosis: case series, proposed nomenclature change, and review. *Clin Infect Dis* **2003**; 37(suppl 3):S265–80.
602. Cadranet J, Philippe B, Hennequin C, et al. Voriconazole for chronic pulmonary aspergillosis: a prospective multicenter trial. *Eur J Clin Microbiol Infect Dis* **2012**; 31:3231–9.
603. Smith NL, Denning DW. Underlying conditions in chronic pulmonary aspergillosis including simple aspergilloma. *Eur Respir J* **2011**; 37:865–72.
604. Denning DW, Cadranet J, Beigelman-Aubry C, et al. Chronic pulmonary aspergillosis: rationale and clinical guidelines for diagnosis and management. *Eur Respir J* **2016**; 47:45–68.
605. Hope WW, Walsh TJ, Denning DW. The invasive and saprophytic syndromes due to *Aspergillus* spp. *Med Mycol* **2005**; 43(suppl 1):S207–38.
606. Smith NL, Hankinson J, Simpson A, Bowyer P, Denning DW. A prominent role for the IL1 pathway and IL15 in susceptibility to chronic cavitary pulmonary aspergillosis. *Clin Microbiol Infect* **2014**; 20:O480–8.
607. Smith NL, Hankinson J, Simpson A, Denning DW, Bowyer P. Reduced expression of TLR3, TLR10 and TREM1 by human macrophages in chronic cavitary pulmonary aspergillosis, and novel associations of VEGFA, DENND1B and PLAT. *Clin Microbiol Infect* **2014**; 20:O960–8.
608. Baxter CG, Denning DW, Jones AM, Todd A, Moore CB, Richardson MD. Performance of two *Aspergillus* IgG EIA assays compared with the precipitin test in chronic and allergic aspergillosis. *Clin Microbiol Infect* **2013**; 19:E197–204.
609. Page ID, Richardson M, Denning DW. Antibody testing in aspergillosis—*quo vadis?* *Med Mycol* **2015**; 53:417–39.
610. Roberts CM, Citron KM, Strickland B. Intrathoracic aspergilloma: role of CT in diagnosis and treatment. *Radiology* **1987**; 165:123–8.
611. Agarwal R, Vishwanath G, Aggarwal AN, Garg M, Gupta D, Chakrabarti A. Itraconazole in chronic cavitary pulmonary aspergillosis: a randomised controlled trial and systematic review of literature. *Mycoses* **2013**; 56:559–70.
612. Camuset J, Nunes H, Dombret MC, et al. Treatment of chronic pulmonary aspergillosis by voriconazole in nonimmunocompromised patients. *Chest* **2007**; 131:1435–41.
613. Jain LR, Denning DW. The efficacy and tolerability of voriconazole in the treatment of chronic cavitary pulmonary aspergillosis. *J Infect* **2006**; 52:e133–7.
614. Al-shair K, Atherton GT, Kennedy D, Powell G, Denning DW, Cares A. Validity and reliability of the St. George's Respiratory Questionnaire in assessing health status in patients with chronic pulmonary aspergillosis. *Chest* **2013**; 144:623–31.
615. Felton TW, Baxter C, Moore CB, Roberts SA, Hope WW, Denning DW. Efficacy and safety of posaconazole for chronic pulmonary aspergillosis. *Clin Infect Dis* **2010**; 51:1383–91.
616. Koyama K, Ohshima N, Suzuki J, et al. Recurrence of chronic pulmonary aspergillosis after discontinuation of maintenance treatment by antifungal triazoles. *J Infect Chemother* **2014**; 20:375–9.
617. Prutsky G, Domecq JP, Salazar CA, Accinelli R. Antifibrinolytic therapy to reduce haemoptysis from any cause. *Cochrane Database Syst Rev* **2012**; 4:CD008711.
618. Moen CA, Burrell A, Dunning J. Does tranexamic acid stop haemoptysis? *Interact Cardiovasc Thorac Surg* **2013**; 17:991–4.
619. Jardin M, Remy J. Control of hemoptysis: systemic angiography and anastomoses of the internal mammary artery. *Radiology* **1988**; 168:377–83.
620. Swanson KL, Johnson CM, Prakash UB, McKusick MA, Andrews JC, Stanson AW. Bronchial artery embolization: experience with 54 patients. *Chest* **2002**; 121:789–95.
621. Corr P. Management of severe hemoptysis from pulmonary aspergilloma using endovascular embolization. *Cardiovasc Intervent Radiol* **2006**; 29:807–10.
622. Serasli E, Kalpakidis V, Iatrou K, Tsara V, Siopi D, Christaki P. Percutaneous bronchial artery embolization in the management of massive hemoptysis in chronic lung diseases. Immediate and long-term outcomes. *Int Angiol* **2008**; 27:319–28.
623. Kohno S, Izumikawa K, Yoshida M, et al. A double-blind comparative study of the safety and efficacy of caspofungin versus micafungin in the treatment of candidiasis and aspergillosis. *Eur J Clin Microbiol Infect Dis* **2013**; 32:387–97.
624. Nam HS, Jeon K, Um SW, et al. Clinical characteristics and treatment outcomes of chronic necrotizing pulmonary aspergillosis: a review of 43 cases. *Int J Infect Dis* **2010**; 14:e479–82.
625. Keir GJ, Garfield B, Hansell DM, et al. Cyclical caspofungin for chronic pulmonary aspergillosis in sarcoidosis. *Thorax* **2014**; 69:287–8.
626. Lejay A, Falcoz PE, Santelmo N, et al. Surgery for aspergilloma: time trend towards improved results? *Interact Cardiovasc Thorac Surg* **2011**; 13:392–5.
627. Chen QK, Jiang GN, Ding JA. Surgical treatment for pulmonary aspergilloma: a 35-year experience in the Chinese population. *Interact Cardiovasc Thorac Surg* **2012**; 15:77–80.
628. Lee JG, Lee CY, Park IK, et al. Pulmonary aspergilloma: analysis of prognosis in relation to symptoms and treatment. *J Thorac Cardiovasc Surg* **2009**; 138:820–5.
629. Demir A, Gunluoglu MZ, Turna A, Kara HV, Dincer SI. Analysis of surgical treatment for pulmonary aspergilloma. *Asian Cardiovasc Thorac Ann* **2006**; 14:407–11.
630. Muniappan A, Tapias LF, Butala P, et al. Surgical therapy of pulmonary aspergillomas: a 30-year North American experience. *Ann Thorac Surg* **2014**; 97:432–8.
631. Chen QK, Chen C, Chen XF, Jiang GN. Video-assisted thoracic surgery for pulmonary aspergilloma: a safe and effective procedure. *Ann Thorac Surg* **2014**; 97:218–23.
632. Ichinose J, Kohno T, Fujimori S. Video-assisted thoracic surgery for pulmonary aspergilloma. *Interact Cardiovasc Thorac Surg* **2010**; 10:927–30.
633. Farid S, Mohamed S, Devbhandari M, et al. Results of surgery for chronic pulmonary aspergillosis, optimal antifungal therapy and proposed high risk factors for recurrence—a National Centre's experience. *J Cardiothorac Surg* **2013**; 8:180.
634. Alexander GR. A retrospective review comparing the treatment outcomes of emergency lung resection for massive haemoptysis with and without preoperative bronchial artery embolization. *Eur J Cardiothorac Surg* **2014**; 45:251–5.
635. Pendleton M, Denning DW. Multifocal pulmonary aspergillomas: case series and review. *Ann N Y Acad Sci* **2012**; 1272:58–67.
636. Knutsen AP, Bush RK, Demain JG, et al. Fungi and allergic lower respiratory tract diseases. *J Allergy Clin Immunol* **2012**; 129:280–91; quiz 92–3.
637. Agarwal R, Chakrabarti A, Shah A, et al. Allergic bronchopulmonary aspergillosis: review of literature and proposal of new diagnostic and classification criteria. *Clin Exp Allergy* **2013**; 43:850–73.
638. Agarwal R, Aggarwal AN, Garg M, Saikia B, Chakrabarti A. Cut-off values of serum IgE (total and *A. fumigatus*-specific) and eosinophil count in differentiating allergic bronchopulmonary aspergillosis from asthma. *Mycoses* **2014**; 57:659–63.
639. Moss RB. Treatment options in severe fungal asthma and allergic bronchopulmonary aspergillosis. *Eur Respir J* **2014**; 43:1487–500.
640. Agarwal R, Nath A, Aggarwal AN, Gupta D, Chakrabarti A. *Aspergillus* hypersensitivity and allergic bronchopulmonary aspergillosis in patients with acute severe asthma in a respiratory intensive care unit in north India. *Mycoses* **2010**; 53:138–43.
641. Denning DW, Pashley C, Hartl D, et al. Fungal allergy in asthma—state of the art and research needs. *Clin Transl Allergy* **2014**; 4:14.
642. Tanou K, Zintzaras E, Kaditis AG. Omalizumab therapy for allergic bronchopulmonary aspergillosis in children with cystic fibrosis: a synthesis of published evidence. *Pediatr Pulmonol* **2014**; 49:503–7.
643. Kellett F, Redfern J, Niven RM. Evaluation of nebulised hypertonic saline (7%) as an adjunct to physiotherapy in patients with stable bronchiectasis. *Respir Med* **2005**; 99:27–31.

644. Moreira AS, Silva D, Ferreira AR, Delgado L. Antifungal treatment in allergic bronchopulmonary aspergillosis with and without cystic fibrosis: a systematic review. *Clin Exp Allergy* **2014**; 44:1210–27.
645. Stevens DA, Schwartz HJ, Lee JY, et al. A randomized trial of itraconazole in allergic bronchopulmonary aspergillosis. *N Engl J Med* **2000**; 342:756–62.
646. Chishimba L, Langridge P, Powell G, Niven RM, Denning DW. Efficacy and safety of nebulised amphotericin B (NAB) in severe asthma with fungal sensitisation (SAFS) and allergic bronchopulmonary aspergillosis (ABPA). *J Asthma* **2015**; 52:289–95.
647. Chang C, Gershwin ME, Thompson GR 3rd. Fungal disease of the nose and sinuses: an updated overview. *Curr Allergy Asthma Rep* **2013**; 13:152–61.
648. Thompson GR 3rd, Patterson TF. Fungal disease of the nose and paranasal sinuses. *J Allergy Clin Immunol* **2012**; 129:321–6.
649. Bozeman S, deShazo R, Stringer S, Wright L. Complications of allergic fungal sinusitis. *Am J Med* **2011**; 124:359–68.
650. Howard BE, Lal D. Oral steroid therapy in chronic rhinosinusitis with and without nasal polyposis. *Curr Allergy Asthma Rep* **2013**; 13:236–43.
651. Gan EC, Thamboo A, Rudmik L, Hwang PH, Ferguson BJ, Javer AR. Medical management of allergic fungal rhinosinusitis following endoscopic sinus surgery: an evidence-based review and recommendations. *Int Forum Allergy Rhinol* **2014**; 4:702–15.
652. Tsabouri S, Tseretopoulou X, Priftis K, Ntzani EE. Omalizumab for the treatment of inadequately controlled allergic rhinitis: a systematic review and meta-analysis of randomized clinical trials. *J Allergy Clin Immunol Pract* **2014**; 2:332–40. e1.
653. Chan KO, Genoway KA, Javer AR. Effectiveness of itraconazole in the management of refractory allergic fungal rhinosinusitis. *J Otolaryngol Head Neck Surg* **2008**; 37:870–4.
654. Seiberling K, Wormald PJ. The role of itraconazole in recalcitrant fungal sinusitis. *Am J Rhinol Allergy* **2009**; 23:303–6.
655. Thanasumpun T, Batra PS. Oral antifungal therapy for chronic rhinosinusitis and its subtypes: a systematic review. *Int Forum Allergy Rhinol* **2011**; 1:382–9.